

---

# Noninvasive Measurement of Gastric Accommodation by Means of Pertechnetate SPECT: Limiting Radiation Dose Without Losing Image Quality

Roelof J. Bennink, MD<sup>1</sup>; Bram D. van den Elzen, MD<sup>2</sup>; Sjoerd D. Kuiken, MD<sup>2</sup>; and Guy E. Boeckxstaens, MD, PhD<sup>2</sup>

<sup>1</sup>Department of Nuclear Medicine, Academic Medical Center, Amsterdam, The Netherlands; and <sup>2</sup>Department of Gastroenterology and Hepatology, Academic Medical Center, Amsterdam, The Netherlands

---

The gastric accommodation response to a meal is impaired in conditions such as functional dyspepsia. At present, a barostat study is the gold standard to assess fundic relaxation in response to a meal. However, this method is invasive and possibly induces artifacts as a result of positive intraluminal balloon pressure. A noninvasive scintigraphic test has been developed to measure gastric accommodation in humans. The aim of this study was to refine this method, increasing the imaging time span and limiting the radiation dose applied without losing image quality, so that repeated measurements within 1 subject are possible without increasing radiation risk. **Methods:** Thirteen healthy volunteers without gastrointestinal symptoms were recruited from a student population. Each volunteer had previously undergone a barostat study. After an overnight fast, volunteers were scanned twice on separate days after intravenous injection of 200 MBq <sup>99m</sup>Tc-pertechnetate. On 1 occasion, volunteers were pretreated with a proton pump inhibitor. Thirty minutes after injection, sequential, 7-min SPECT scans (72 views, 10 s/view, 128 matrix) were acquired on a dual-head  $\gamma$ -camera system before and up to 2 h after ingestion of a test meal. After reconstruction (filtered backprojection, ramp-Butterworth filter; order, 10; cutoff, 0.45 Nyquist), fundus volume was calculated semiautomatically by means of a threshold voxel volume tool. **Results:** Limiting injection dose from 370–740 MBq to 200 MBq <sup>99m</sup>Tc-pertechnetate resulted in good-quality images, with high target-to-background ratio up to 150 min after injection. This represents a significant dose reduction, from 4.6–9.3 to 2.5 mSv. There was no significant difference between SPECT fundic volumes or accommodation response with or without proton pump inhibitor pretreatment. Volume kinetics were similar to those with barostat studies, but gastric volumes were inferior. **Conclusion:** Refining the methodology yields an improved noninvasive test for the assessment of gastric accommodation without unnecessarily increasing radiation burden. This technique enables repeated and serial measurement of gastric accommodation to a test meal, a process that is poten-

tially useful for characterization and follow-up of dyspeptic patients with and without drug intervention.

**Key Words:** radionuclide imaging; gastric accommodation; SPECT; barostat studies; <sup>99m</sup>Tc-pertechnetate

**J Nucl Med 2004; 45:147–152**

---

**D**yspepsia refers to pain or discomfort centered in the upper abdomen in the absence of structural or biochemical abnormalities (1). The pathophysiology of functional dyspepsia is largely unknown (2–4). Proximal stomach dysfunction has been demonstrated in patients with functional dyspepsia, with impaired gastric accommodation to meal ingestion (5) and hypersensitivity to fundic distention (6). However, controversy remains, and therapeutic effects of drugs targeting these mechanisms are often disappointing (7,8).

The gastric accommodation response enables relaxation of the proximal stomach, providing a reservoir for food ingestion without a rise in pressure (9). Impaired relaxation of the proximal stomach may contribute to the development of meal-induced symptoms (5,10,11). To facilitate research on impaired gastric accommodation, a noninvasive and easy-to-perform test is needed to select patients for pharmacologic testing and evaluate effects of therapeutic strategies (12).

Measurement of the gastric accommodation response to meal intake is technically difficult, and available techniques have methodologic drawbacks (12). The current gold standard for the measurement of accommodation is the gastric barostat, involving the introduction of a balloon into the gastric fundus (13). In addition to the discomfort associated with this invasive and time-consuming procedure, the presence of a balloon in the stomach has been shown to cause dilatation of the antrum as a result of meal displacement and induction of exaggerated proximal gastric relaxation (14). Nonradiation techniques, such as ultrasound or MRI, have

---

Received May 7, 2003; revision accepted Sep. 25, 2003.  
For correspondence or reprints contact: Roelof J. Bennink, MD, Department of Nuclear Medicine, Academic Medical Center, Meibergdreef 9, 1105 AZ Amsterdam, The Netherlands.  
E-mail: r.bennink@amc.uva.nl

technical limitations or, in the case MRI, potential advantages but limited availability for this type of study (12,15).

A scintigraphic technique based on pertechnetate uptake in gastric mucosa for measurement of gastric accommodation has been described (16–21). However, this technique requires relatively high exposure to ionizing radiation and imaging can be performed only within a relatively short time interval ( $\pm 20$  min) after isotope injection (12). Despite these limitations, the technique could be applicable in clinical practice to select patients with impaired accommodation who might benefit from fundic relaxant agents (22).

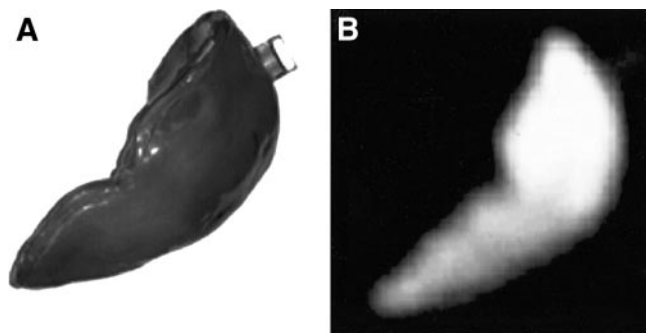
Enhancement of pertechnetate uptake in gastric mucosa through inhibition of intraluminal release with H<sub>2</sub> receptor antagonists is routinely performed in scintigraphy for detection of ectopic gastric mucosa. The more potent and longer-lasting inhibition of gastric acid secretion provided by proton pump inhibitors (PPI) could provide an even higher and more prolonged uptake in gastric mucosa, providing a basis for reduction of radiopharmaceutical dose and increasing the period of adequate imaging.

The aim of this study was to refine the scintigraphic method, limiting the radiation dose applied and increasing the possible postinjection imaging time span without losing image quality, so that sequential (multiple measurements within 1 test) and repeated (measurements before and after treatment) measurements within 1 subject become possible without increasing radiation burden.

## MATERIALS AND METHODS

### Phantom and Pilot Studies

Stomach-shaped plastic inserts (250, 500, 750, and 1,000 mL; Fig. 1A) were filled with water containing 40 MBq <sup>99m</sup>Tc-pertechnetate and were placed in an anthropomorphic abdomen phantom. The pertechnetate dose was determined as 20% total stomach uptake (ICRP-53), assuming that a volunteer would be injected with 200 MBq. Tomographic studies were acquired on a large-field-of-view  $\gamma$ -camera (Varicam; General Electric Medical Systems) equipped with low-energy high-resolution collimators. Using the dual-head camera, a 180° orbit around the phantom was performed, acquiring into a 128 × 128 matrix every 5° at 5, 7, 10, and 15 s/frame. After completion of the acquisition, data were



**FIGURE 1.** (A) Photograph of stomach-shaped 1,000-mL plastic insert of anthropomorphic abdomen phantom. (B) Corresponding coronal SPECT slice of phantom, filled with water containing 40 MBq <sup>99m</sup>Tc-pertechnetate.

reconstructed on a Hermes processing station (Nuclear Diagnostics) using filtered backprojection (ramp–Butterworth filter; order, 10; cutoff, 0.45 Nyquist) to produce transverse, sagittal, and coronal images of the phantom (Fig. 1B). After reconstruction, phantom volume measurements were performed using the volume tool software on the Hermes processing station.

To determine the optimal timing of SPECT after intravenous injection of pertechnetate, 10 previous dynamic pertechnetate studies performed for diagnosis of Meckel's diverticulum (patient ages > 15 y) were selected randomly. All patients were injected intravenously with 200 MBq <sup>99m</sup>Tc-pertechnetate followed by dynamic imaging of the abdomen for 30 min. On these dynamic studies, a region of interest (ROI) was drawn around the stomach and a background ROI was drawn in the liver to determine the specific uptake of pertechnetate in the stomach.

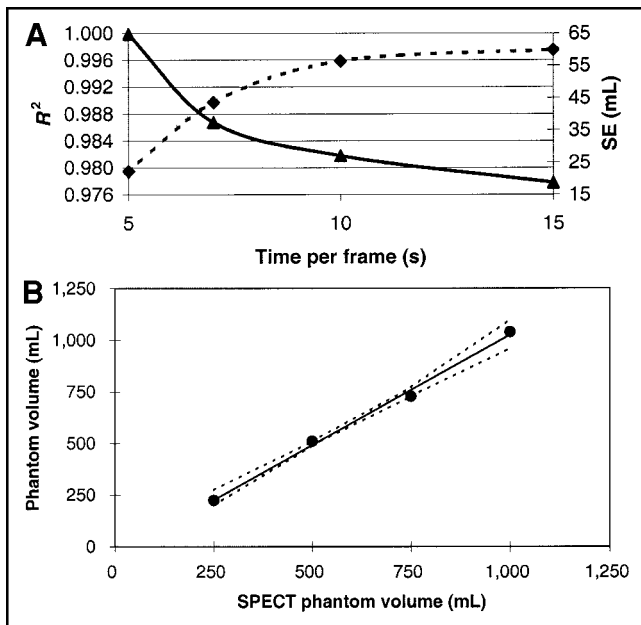
### Volunteer Studies

**Volunteers.** Thirteen healthy volunteers (9 women, 4 men; mean age, 22 y; range, 20–25 y) were studied. All subjects were free of gastrointestinal symptoms, had undergone no previous gastrointestinal surgeries, and were taking no medications. Subjects were studied after an overnight fast and were not allowed to smoke or drink alcohol for at least 24 h before the study. All subjects underwent a gastric barostat study and 2 pertechnetate SPECT sessions, 1 with and 1 without gastric acid suppression with a PPI (pantoprazol, 80 mg orally, 3 d). All volunteers gave written informed consent to participate in the study, which was approved by the medical ethics committee of the Academic Medical Center of the University of Amsterdam.

**Gastric Barostat.** After an overnight fast, the volunteers underwent a gastric barostat study. The barostat bag was introduced, unfolded, and positioned into the proximal stomach. After an equilibration period of 15 min, mean diaphragmatic pressure (MDP) was determined and baseline-operating pressure was set at MDP + 2 mm Hg. Intrabag volume was recorded for 15 min, followed by ingestion of a liquid test meal with a caloric load of 300 kcal and a volume of 200 mL (Nutridrink; Nutricia), which was ingested through a straw. Intrabag volume was recorded during the next 60 min.

Postprandial (PP) volumes were measured as the mean volume of 5-min periods using commercially available software (Polygram for Windows; Medtronic, Inc.). Fasting volume was calculated as the mean volume at 15 min before meal intake. After meal intake, the average of the 60-min PP volume was measured. The gastric relaxation after ingestion of the liquid meal was expressed as the difference in volume between the mean volume of the total PP recording period and that at 15 min before meal ingestion (Diff). The PP ratio was calculated as the average of the 60-min PP volume divided by the mean fasting volume (Ratio).

**Scintigraphy and Interpretation.** Tomographic studies were acquired on a large-field-of-view  $\gamma$ -camera (Varicam) equipped with low-energy high-resolution collimators. Volunteers were positioned supine on the imaging table with the stomach in the middle of the field of view. Thirty minutes after intravenous injection of 200 MBq <sup>99m</sup>Tc-pertechnetate, a 7-min baseline acquisition (72 views, 10 s/view, 128 × 128 matrix) was performed. After ingestion of a liquid test meal with a caloric load of 300 kcal and a volume of 200 mL (Nutridrink), sequential 7-min SPECT imaging was performed every 10 min for the first hour and every 30 min for the second hour. After completion of the acquisition, data were reconstructed as described for the phantom studies. A threshold of



**FIGURE 2.** (A) Square of correlation coefficient ( $R^2$ , dashed line) and SEE (SE, solid line) in function of acquisition time per frame of actual phantom values and SPECT volume estimates. With constant 72-view orbit, SPECT volume estimates become more accurate with increasing acquisition time. (B) Correlation and 95% confidence interval of known phantom volumes with volumes measured by SPECT.

20% of the maximal voxel count value was applied after filling the interior stomach with a default 50% of the maximal voxel count value. Total and proximal (fundus) gastric volumes were calculated. The stomach was divided into proximal and distal parts by drawing a line across the incisura angularis perpendicular to the great curvature of the stomach. Fasting volume was calculated when no suppression of acid secretion was used and when volunteers had received a PPI before scintigraphy. In an analogy to barostat reporting parameters, the mean PP volume was calculated. Subsequently, the gastric relaxation ratio after ingestion of the liquid meal was expressed as the difference in volume between the mean volume of the total PP recording period, and the fasting volume (Diff) and the PP ratio was calculated as the average of the 60-min PP volume divided by the mean fasting volume (Ratio).

The specific uptake in the posterior gastric wall was determined on transverse SPECT slices with and without PPI pretreatment. Therefore, both datasets were coregistered using Hermes Multimodality (Nuclear Diagnostics), and identical ROIs were drawn in the posterior gastric wall and the liver. A gastric pertechnetate uptake ratio was calculated on a 1-min anterior and posterior image acquired before the first and after the last SPECT acquisition. After construction of a geometric mean image, identical ROIs were drawn on the stomach and liver and specific uptake of pertechnetate in the stomach was determined.

### Statistical Analysis

Results are expressed as the mean  $\pm$  SEM. Differences between 2 measurements were analyzed by the nonparametric Wilcoxon rank test for paired data. The correlation between scintigraphy and barostat was determined with a nonparametric rank correlation test. All statistical tests were 2-tailed, and differences were eval-

uated at the 5% level of significance. In the volunteer study, a Bonferroni correction was applied for multiple comparison testing ( $n = 8$ ).

## RESULTS

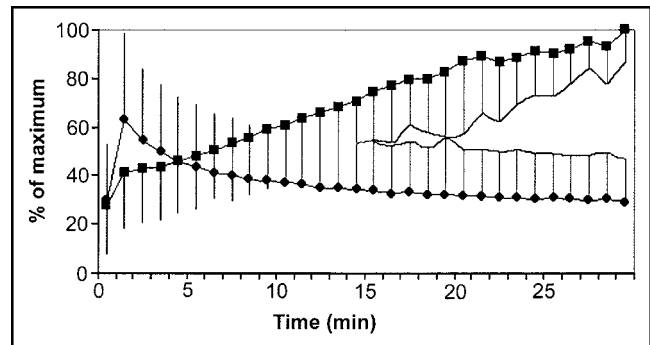
### Phantom and Pilot Studies

**Phantom Study.** Figure 2 shows the actual phantom volumes and SPECT volume estimates for the water-filled stomach insert in the anthropomorphic abdomen phantom. Figure 2A shows that the accuracy of SPECT volume estimates improves with increasing acquisition time. With increasing total acquisition time, the square of the correlation coefficient  $R^2$  approaches its maximal value and the SEE (SE) decreases. The trade-off with highest accuracy and minimal acquisition time per orbit was chosen and set on a total of 10 s of acquisition time per frame, resulting in a total acquisition time of 7 min (including gantry movement). SPECT-derived volume estimates (10 s/frame) were highly accurate and showed a near perfect linear relationship with the actual phantom volumes (Fig. 2B).

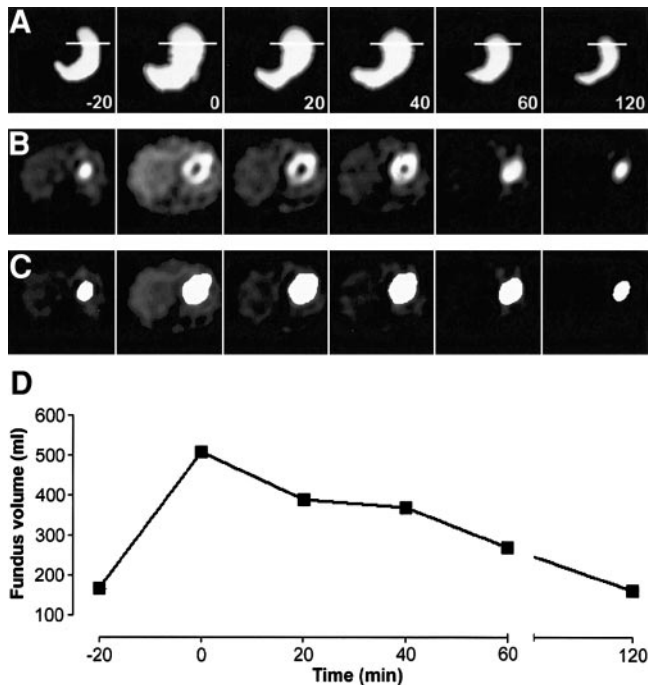
**Pilot Study.** Figure 3 shows the mean pertechnetate uptake in the stomach and in the surrounding tissue (liver) over time. The uptake in the stomach increases over time and is significantly higher ( $P < 0.01$ ) than background from 10 min after injection. Clear distinction between stomach and background, accounting for biologic variance, is obtained from 20 min after injection.

### Volunteer Study

Figure 4 shows an example of gastric volume scintigraphy. Limiting injection dose from 370–740 MBq to 200 MBq  $^{99m}\text{Tc}$ -pertechnetate resulted in good-quality images, with a significant dose reduction from 4.6–9.3 to 2.5 mSv. Table 1 shows the results of the volunteer study. Both in a fasting and in a PP state, the mean fundic volumes measured by barostat were significantly higher than the volumes measured by scintigraphy. There was no significant difference between the derived parameters (Diff and Ratio) for SPECT and barostat. Fundic volume kinetics were very similar for

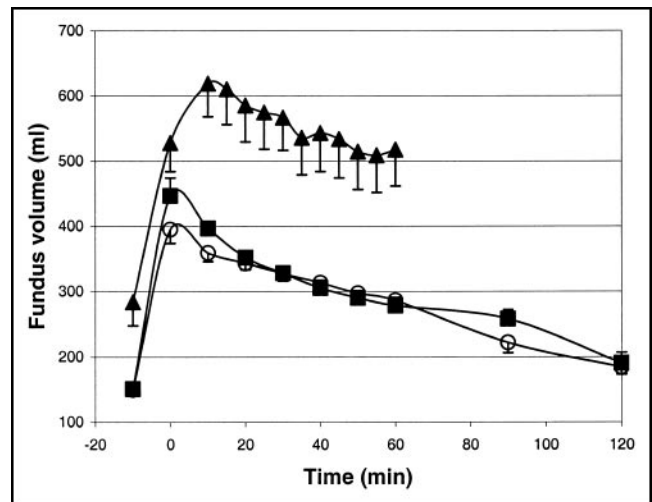


**FIGURE 3.** Mean  $\pm$  2 SDs for pertechnetate uptake in stomach (■) and surrounding tissue (♦) in function of time after intravenous injection. Clear distinction between stomach and surrounding tissue (liver), accounting for biologic variance, can be made beginning 20 min after pertechnetate injection.



**FIGURE 4.** Gastric volume scintigraphy (volunteer 2, without PPI). (A) Gradient-shading volume-rendered SPECT images of stomach at baseline (20 min preprandial) and at multiple postprandial time points (0–120 min). Transverse SPECT slices have been selected (white line). (B) Corresponding transverse SPECT slices. Uptake of  $^{99m}\text{Tc}$ -pertechnetate is visible in gastric mucosa. (C) Same transverse SPECT slices after filling stomach lumen and determination of threshold-based voxel volume. (D) Corresponding volume of fundus, determined by gastric volume scintigraphy.

barostat and SPECT measurements (Fig. 5). No significant difference between the fundic volumes was measured by scintigraphy with or without PPI in fasting or PP state (Table 1). Differences between the mean PP fundic volume and the fasting fundic volume (Diff) and the volume ratio with and without PPI (Ratio) were not significant. On transverse SPECT slices, radioactivity was more homogeneously distributed in the stomach wall, with less secreted pertechnetate when volunteers were pretreated with PPIs (Fig. 6). The relative uptake in the stomach posterior wall was significantly higher ( $35.1\% \pm 6.7\%$ ,  $P < 0.01$ ) after pretreat-



**FIGURE 5.** Fundic volumes (mean  $\pm$  SEM) measured in fasting and postprandial state measured by barostat ( $\blacktriangle$ ), SPECT without PPI ( $\circ$ ) and SPECT with PPI pretreatment ( $\blacksquare$ ). Significant difference ( $P < 0.01$ ) is seen between barostat and SPECT volume measurements. No significant difference is seen between SPECT measurements with and without PPI pretreatment. Shape of gastric volume curve is very similar for both techniques.

ment with PPIs. The pertechnetate uptake ratio, determined on planar scintigraphy in volunteers with and without PPI pretreatment before the first and after the last SPECT acquisition, was significantly higher ( $P < 0.01$ ) 150 min after injection than that at 30 min after injection of the radiopharmaceutical (Fig. 7). The mean increases in uptake ratio with and without PPI pretreatment were  $4.64 \pm 0.67$  and  $3.89 \pm 0.89$ , respectively. There was no significant difference in uptake ratio or uptake ratio increase in the 2 groups.

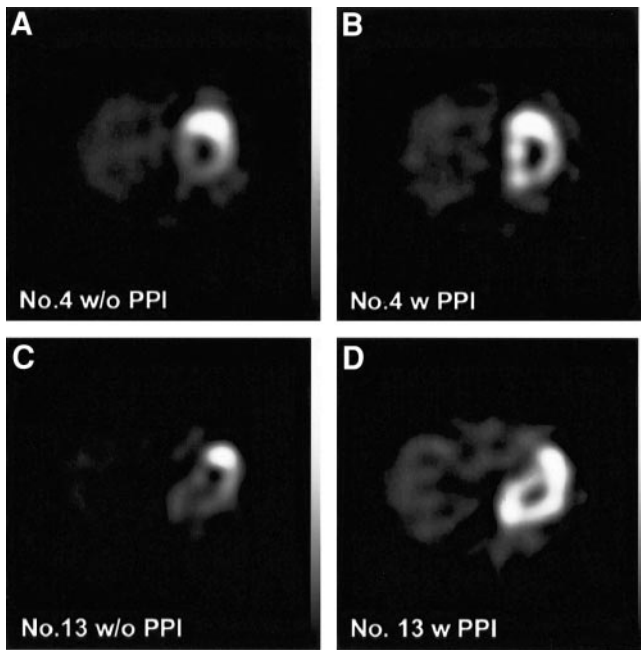
## DISCUSSION

We investigated whether noninvasive measurement of gastric accommodation by means of pertechnetate SPECT can be performed with a reduced pertechnetate dose. Reducing the amount of radioactivity can be accounted for by increasing the acquisition time. When serial measurement is required in a dynamic process such as gastric volume after meal ingestion, longer total acquisition time per SPECT

**TABLE 1**  
Results of the Volunteer Study

Parameter	Gastric region	Barostat	SPECT	SPECT + PPI	$P$ (SPECT $\pm$ PPI)	$P$ (SPECT – barostat)
Fasting	Fundus	$284.07 \pm 36.11$	$150.07 \pm 6.42$	$150.79 \pm 3.78$	NS	<0.01
Postprandial	Fundus	$553.17 \pm 53.82$	$339.36 \pm 10.76$	$358.75 \pm 10.14$	NS	<0.01
Diff	Fundus	$269.10 \pm 45.00$	$189.29 \pm 10.30$	$207.96 \pm 9.50$	NS	NS
Ratio	Fundus	$2.200 \pm 0.30$	$2.30 \pm 0.10$	$2.39 \pm 0.07$	NS	NS

NS = not statistically significant; Diff = difference in volume between mean volume of total postprandial recording period and 15 min before meal ingestion; Ratio = average of 60-min postprandial volume divided by mean fasting volume.



**FIGURE 6.** Transverse SPECT slices of 2 volunteers. (A) and (C) Studies performed without PPI pretreatment. (B) and (D) Coregistered transverse SPECT slices of studies performed with PPI pretreatment in same volunteers. Remaining amount of tracer in posterior gastric wall was significantly higher when volunteers were pretreated with PPI ( $P < 0.01$ ).

orbit not only would limit repeated measurement but also would decrease measurement reliability, because of the resulting greater difference between the starting volume of the stomach and the volume at the end of the SPECT acquisition.

Our goal was to limit the radiation exposure in patients or volunteers to 5 mSv, enabling research protocols to perform 2 tests, 1 before and 1 after treatment. To limit radiation exposure to 2.5 mSv per investigation, the amount of pertechnetate injected must be  $\leq 200$  MBq (ICRP-80). The experiments with the anthropomorphic abdomen phantom confirmed that the accuracy of volume determination of different volumes on SPECT images increases with total acquisition time. Because the total radioactivity within the phantom was constant, this mimics closely the physiologic situation with pertechnetate within the stomach wall as it distends after food intake. Based on the shape of the accuracy curve, with a plateau phase beginning at 10 s per frame, the minimal acquisition time could be determined. Using 10 s per frame, the resulting total acquisition time of 7 min including gantry movement is comparable to or less than that cited in other published studies (16,17,21) and enables serial measurement every 10 min.

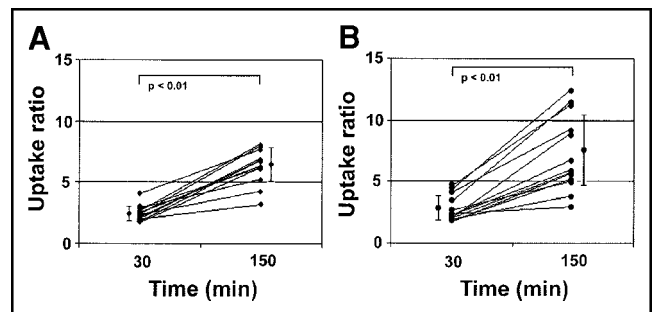
For reliable stomach volume measurement based on threshold volume delineation, a sufficient and preferably constant organ-to-background uptake ratio is needed. Therefore, the uptake characteristic of pertechnetate was assessed in patients. It was clearly shown that the gastric uptake increases with time, being significantly higher than

surrounding tissue (liver) 10 min after injection. To guarantee clear distinction between the normal range (mean  $\pm$  2 SDs) of the stomach and surrounding tissue, a delay of 20 min after injection was needed. The uptake ratio in the stomach remained high and enabled serial SPECT acquisition up to at least 150 min after injection, which is significantly longer than times cited in other studies (16–21). This is a solution to the problem posed by the previous necessity to image within a relatively short time interval after injection of the radiopharmaceutical (12).

The rationale for the additional administration of a PPI was to compensate for the reduced amount of radioactivity injected intravenously. Comparing the relative amount of tracer in the posterior stomach wall with and without PPI showed an increased retention with less secretion floating on top of the test meal and with theoretically better delineation of the stomach wall. The addition of a PPI, however, had no significant effect on gastric volumes measured. Because image quality was sufficient with the reduced pertechnetate dose in SPECT for volumetric calculation, it was decided not to pursue PPI use in future trials.

Comparing the results of gastric volume measuring by means of SPECT and barostat before and up to 60 min PP, we confirmed observations made in other studies (16,18,21). Volumes measured by SPECT are consistently lower than barostat volumes. The shape and derived parameters of the volume curve, however, were very similar. The higher volumes measured with the barostat are believed to be an artifact caused by the intraballloon pressure in the barostat bag, needed to measure baseline and PP volumes (16). Whether the nonphysiologic-exerted pressure is needed to investigate accommodation is a matter of debate, because it can be argued that scintigraphy detects intragastric volume and that the detected increase in PP volume also depends on gastric emptying and gastric secretion (23). On the other hand, several trials have demonstrated the ability of SPECT to detect abnormal accommodation (17,18,21).

For comparison of barostat and SPECT, the SPECT volume of the fundus was derived from the total stomach



**FIGURE 7.** Uptake ratio of pertechnetate in stomach without (A) and with (B) PPI pretreatment determined on planar scintigraphy 30 and 150 min after intravenous injection (mean  $\pm$  SD). Uptake ratio increases over time and enables SPECT volumetry up to at least 150 min after injection. No significant difference in uptake ratio increase was observed between groups.

SPECT volume. This can be considered arbitrary, because an exact scintigraphic delineation of the fundus is not possible. In practice, however, identification of the antrum as a horizontal part of the stomach is quite feasible. Together with the incisura angularis, this provides enough information for separation of the proximal and distal stomach. However, the comparison parameters of fasting and PP volume differences (Diff) and ratio (Ratio) for the total stomach and the fundus were not significantly different (data not shown), suggesting a negligible role of the antrum in measurement of gastric accommodation. However, the ability of measuring total as well as fundic or antral volumes might be interesting in characterizing gastric response to stimuli in health and disease.

It has been reported that suppression of gastric acid secretion affects both gastric motility and gastric emptying (24). Not only H<sub>2</sub> receptor antagonists, such as ranitidine, but also PPIs, such as omeprazole, delay gastric emptying despite an increase in PP antral contractility. Although the differences in SPECT volumes measured with and without PPI were not significantly different, PP volumes were slightly higher with PPI, supporting observations made on the effects of acid suppression on gastric motility (24).

The differences between PP and fasting volumes assessed with reduced pertechnetate dose scintigraphy without PPI pretreatment are not significantly different from those measured with a barostat balloon in the same population of healthy volunteers. This enables repeated noninvasive investigation of gastric accommodation in volunteers and patients to identify and characterize gastric motility abnormalities and therapeutic effects of known or experimental drugs without the increased morbidity of intragastric balloons or elevated radiation burden. It is also feasible to determine gastric volumes up to 2 h PP. Whether this is useful must be established in trials comparing dyspeptic patients with normal volunteers.

## CONCLUSION

Noninvasive measurement of gastric accommodation with a reduced dose of pertechnetate is feasible without losing image quality. Increasing image quality by using a PPI does not affect measurement results but is controversial in terms of effects on gastric motility and, therefore, is discarded. This noninvasive technique enables repeated and serial measurement of gastric accommodation to a test meal, a process that is potentially useful for characterization and follow-up of dyspeptic patients with and without drug intervention.

## REFERENCES

1. Talley NJ, Stanghellini V, Heading RC, Koch KL, Malagelada JR, Tytgat GN. Functional gastroduodenal disorders. *Gut*. 1999;45(suppl 2):II37-II42.
2. Quartero AO, de Wit NJ, Lodder AC, Numans ME, Smout AJ, Hoes AW. Disturbed solid-phase gastric emptying in functional dyspepsia: a meta-analysis. *Dig Dis Sci*. 1998;43:2028-2033.
3. Richter JE. Stress and psychologic and environmental factors in functional dyspepsia. *Scand J Gastroenterol*. 1991;182(suppl):40-46.
4. Thumshirn M. Pathophysiology of functional dyspepsia. *Gut*. 2002;51(suppl 1):I63-I66.
5. Tack J, Piessevaux H, Coulie B, Caenepeel P, Janssens J. Role of impaired gastric accommodation to a meal in functional dyspepsia. *Gastroenterology*. 1998;115:1346-1352.
6. Mertz H, Fullerton S, Naliboff B, Mayer EA. Symptoms and visceral perception in severe functional and organic dyspepsia. *Gut*. 1998;42:814-822.
7. Berstad A, Olafsson S, Tefera S, Hatlebakk JG, Gilja OH, Hausken T. Controversies in dyspepsia. *Eur J Surg*. 2001;167:4-11.
8. Panganamamula KV, Fisher RS, Parkman HP. Functional (nonulcer) dyspepsia. *Curr Treat Options Gastroenterol*. 2002;5:153-160.
9. Azpiroz F, Malagelada JR. Vagally mediated gastric relaxation induced by intestinal nutrients in the dog. *Am J Physiol*. 1986;251:G727-G735.
10. Samsom M, Salet GA, Roelofs JM, Akkermans LM, Vanberge-Henegouwen GP, Smout AJ. Compliance of the proximal stomach and dyspeptic symptoms in patients with type I diabetes mellitus. *Dig Dis Sci*. 1995;40:2037-2042.
11. Vu MK, Straathof JW, Schaar PJ, et al. Motor and sensory function of the proximal stomach in reflux disease and after laparoscopic Nissen fundoplication. *Am J Gastroenterol*. 1999;94:1481-1489.
12. Schwizer W, Steingotter A, Fox M, et al. Non-invasive measurement of gastric accommodation in humans. *Gut*. 2002;51(suppl 1):I59-I62.
13. Azpiroz F, Malagelada JR. Gastric tone measured by an electronic barostat in health and postsurgical gastroparesis. *Gastroenterology*. 1987;92:934-943.
14. Mundt MW, Hausken T, Samsom M. Effect of intragastric barostat bag on proximal and distal gastric accommodation in response to liquid meal. *Am J Physiol Gastrointest Liver Physiol*. 2002;283:G681-G686.
15. de Zwart IM, Mearadji B, Lamb HJ, et al. Gastric motility: comparison of assessment with real-time MR imaging or barostat measurement initial experience. *Radiology*. 2002;224:592-597.
16. Kuiken SD, Samsom M, Camilleri M, et al. Development of a test to measure gastric accommodation in humans. *Am J Physiol*. 1999;277:G1217-G1221.
17. Bouras EP, Delgado-Aros S, Camilleri M, et al. SPECT imaging of the stomach: comparison with barostat, and effects of sex, age, body mass index, and fundoplication. *Gut*. 2002;51:781-786.
18. Liao SS, Camilleri M, Kim DY, Stephens D, Burton DD, O'Connor MK. Pharmacological modulation of human gastric volumes demonstrated noninvasively using SPECT imaging. *Neurogastroenterol Motil*. 2001;13:533-542.
19. Kuo B, Camilleri M, Burton D, et al. Effects of 5-HT(3) antagonism on postprandial gastric volume and symptoms in humans. *Aliment Pharmacol Ther*. 2002;16:225-233.
20. Delgado-Aros S, Kim DY, Burton DD, et al. Effect of GLP-1 on gastric volume, emptying, maximum volume ingested, and postprandial symptoms in humans. *Am J Physiol Gastrointest Liver Physiol*. 2002;282:G424-G431.
21. Kim DY, Delgado-Aros S, Camilleri M, et al. Noninvasive measurement of gastric accommodation in patients with idiopathic nonulcer dyspepsia. *Am J Gastroenterol*. 2001;96:3099-3105.
22. Kim DY, Myung SJ, Camilleri M. Novel testing of human gastric motor and sensory functions: rationale, methods, and potential applications in clinical practice. *Am J Gastroenterol*. 2000;95:3365-3373.
23. van den Elzen BD, Bennink RJ, Wieringa RE, Tytgat GN, Boeckxstaens GE. Fundic accommodation assessed by SPECT scanning; comparison with the gastric barostat. *Gut*. 2003;52:1548-1554.
24. Parkman HP, Urbain JL, Knight LC, et al. Effect of gastric acid suppressants on human gastric motility. *Gut*. 1998;42:243-250.