
Cholescintigraphy in the Diagnosis of Acute Cholecystitis: Morphine Augmentation Is Superior to Delayed Imaging

Chun K. Kim, Kevin K.M. Tse, Malik Juweid, P. David Mozley, Annemarie Woda and Abass Alavi

Division of Nuclear Medicine, Hospital of the University of Pennsylvania, Philadelphia, Pennsylvania

Morphine-augmented radionuclide hepatobiliary imaging has been used as an alternative to delayed imaging for the diagnosis of acute cholecystitis. Previous studies have indicated that the morphine-augmentation is as useful as, or more useful than, delayed imaging. A careful comparison of the efficacy of the two techniques appears warranted because: (1) most early studies did not compare the efficacy of the two techniques in a single report using comparable patient populations; (2) the reported efficacy of morphine-augmentation is based primarily on study designs which excluded cases of early gallbladder visualization without morphine, while most delayed imaging protocols included these cases; and (3) there were concerns about the potential consequences of a false-negative morphine examination. This study compared the efficacy of morphine-augmentation with delayed imaging in those cases in which the gallbladder was not visualized during the first hour of study. Of 306 consecutive patients who were scanned to rule out acute cholecystitis, the gallbladder was visualized within 1 hr in 215 cases. In the remaining 91 cases, 46 patients had delayed imaging (17 true-positive, 10 true-negative, 19 false-positive and 0 false-negative), and 45 had morphine-augmentation (24 true-positive, 15 true-negative, 4 false-positive and 2 false-negative). The data indicate that delayed imaging has a significantly lower specificity and positive-predictive value for acute cholecystitis than morphine-augmentation and a slightly higher (statistically insignificant) sensitivity and negative-predictive value. These results appear to be supported by a reanalysis of the data that has already been reported in the literature.

J Nucl Med 1993; 34:1866-1870

Cholescintigraphy is currently considered the procedure of choice for diagnosing acute cholecystitis. However, conventional imaging protocols frequently require delayed imaging for up to 4 hr postinjection of the radiotracer (1), or even up to 24 hr in patients with severe intercurrent disease (2), to achieve a sufficiently high level of accuracy.

The intravenous administration of morphine results in sig-

nificant contraction of the sphincter of Oddi. This, in turn, causes an increase in the intraductal pressure and forces the bile flow from the common bile duct into the gallbladder if the cystic duct is patent. For this reason, morphine-augmentation has been used as an alternative to delayed imaging to shorten the total imaging time required to diagnose acute cholecystitis (3). The entire study can be terminated in 90 min in contrast to the 4 hr or more with delayed imaging. Previous studies of patients with suspected acute cholecystitis have indicated that the morphine-augmentation is as useful as, or more useful than, delayed imaging (3-8).

However, another comparison of the efficacy of the two techniques would appear warranted for several reasons. First, most investigators did not compare the two techniques in a single series using comparable patient populations. Second, the reported efficacy of morphine-augmentation is based primarily on study designs which excluded cases of early gallbladder visualization without morphine (4-9), while most delayed imaging protocols included these cases. Third, some concerns have been raised about false-negative morphine-augmented studies which need to be examined (10,11). The consequences of a false-negative study can be grave if the result is delayed surgical intervention.

Our preliminary data indicated that morphine-augmented cholescintigraphy was superior to delayed imaging in terms of the specificity and the positive predictive value for the diagnosis of acute cholecystitis (12). In this report, we have expanded our sample size significantly to measure the efficacy of the two techniques, particularly regarding their negative-predictive value (NPV) and positive-predictive value (PPV). We have also reviewed the literature on morphine-augmentation (3-9) and conventional imaging (1,3,13), and the data, which excluded cases with early gallbladder visualization, were reanalyzed.

MATERIALS AND METHODS

Patients

Hepatobiliary scans performed over a 20-mo period were reviewed in their entirety for this report. Scans were excluded from the analysis if they were performed to evaluate a disease other than acute cholecystitis, or if there was no evidence of biliary excretion due to profound hepatocellular dysfunction or cholestasis. The final sample consisted of 306 studies.

Received Mar. 23, 1993; revision accepted Jun. 25, 1993.
For correspondence and reprints contact: Chun K. Kim, MD, Dept. of Nuclear Medicine, Mount Sinai Medical Center, One Gustave L. Levy Place, New York, NY 10029.

TABLE 1
Gallbladder Visualization Scan Results

	TP	FP	TN	FN	PPV	NPV
Visualization within 1 hr (n = 215)			210	5		98%
Nonvisualization by 1 hr (n = 91)						
DI (n = 46):	36 Norvis:	17	19		47%	
	10 Vis:		10	0		100%
MA (n = 45):	28 Norvis:	24	4		86%	
	17 Vis:		15	2		88%

Vis = visualization; Norvis = nonvisualization; DI = delayed imaging; and MA = morphine augmentation.

Imaging Protocol

About 185 MBq (5 mCi) of ^{99m}Tc-diisopropyl-iminodiacetic acid (DISIDA) were administered intravenously to each patient. Sequential images of the abdomen were obtained for 5 min each with a dynamic acquisition protocol on a scintillation camera equipped with a low-energy, all-purpose, parallel-hole collimator linked to a digital computer.

If the gallbladder was not visualized within 60 min, in spite of the presence of radioactive bile in the common bile duct and the small bowel, 0.04 mg/kg of morphine sulfate was injected intravenously over 3 min followed immediately by the administration with an additional 74 MBq (2 mCi) of ^{99m}Tc-DISIDA. Planar images were acquired for another 30 min. If the gallbladder could still not be visualized, the findings were interpreted as most consistent with acute cholecystitis.

Statistical Analysis

The efficacy of the two techniques was compared with either the chi-square or Fisher's exact test, depending on the frequency in the cells of each contingency table. The method that was used to recalculate the PPV and NPV from previously reported studies of delayed imaging is documented in the Appendix.

RESULTS

Gallbladder Visualization Within One Hour

In 215 patients, the gallbladder was visualized within the first hour of study (Table 1). The medical records of these patients were reviewed. Five of these 215 patients had acute cholecystitis confirmed by postsurgical histopathology. The other 210 patients had a variety of abdominal or pelvic disorders. Therefore, the NPV of early gallbladder visualization was 98% in this population.

Delayed Imaging

The gallbladder was not visualized within 1 hr in 91 patients (Table 1). Delayed images were obtained in 46 patients between 3 and 24 hr after injection. The final diagnosis was confirmed by postsurgical histopathology in 31. The final diagnosis was eventually made based on clinical follow-up and outcome data in the remaining 15 patients, which included serial physical examinations, repeated laboratory assays and other imaging procedures.

Of the 46 patients who underwent delayed imaging, the gallbladder was eventually visualized in 10. None of these 10 patients, including two who went to surgery anyway,

had acute cholecystitis (NPV = 100%). Of the remaining 36 patients with persistent nonvisualization of the gallbladder on the delayed views, 29 had surgery; Seventeen had acute cholecystitis and 12 did not. Follow-up showed that the remaining seven patients with persistent nonvisualization did not have acute cholecystitis either. The PPV calculated only from the 29 patients who had surgery is 59% (17/29). The PPV calculated from the 36 patients, including the seven who did not have surgery, was 47% (17/36). Of the 19 patients with false-positive studies, 14 had chronic cholecystitis, one had granulomatous cholecystitis, one had sclerosing cholangitis and three had nonbiliary abdominal diseases.

Morphine Augmentation

There were 45 patients who received morphine after the first hour of imaging (Table 1). The final diagnosis was confirmed by postsurgical histopathology in 33. The final diagnosis was made on clinical grounds in the remaining 12 patients.

In 17 of these 45 patients, the gallbladder was visualized within 30 min of the morphine injection. Five of these 17 patients had surgery, but only one of them was found to have acute cholecystitis. The final diagnosis was made medically in the remaining 12, one of whom had acute cholecystitis. Therefore, two of the 17 patients had acute cholecystitis (NPV = 88%).

All 28 of the patients without visualization of the gallbladder within 30 min of the morphine injection underwent surgery. Of these, 24 had acute cholecystitis and 4 did not (PPV = 86%). Three of the four patients with a false-positive study had chronic cholecystitis. The other patient had a cholangiocarcinoma that obstructed the cystic duct.

In the two patients with false-negative examinations, the gallbladder was visualized within 10 min of the morphine administration. No relationships were found between the time it took to visualize the gallbladder after morphine and the final diagnosis.

The results of our series are summarized in Table 1. In synopsis, when the cases with gallbladder visualization within 1 hr are excluded, delayed imaging has a significantly lower PPV for acute cholecystitis than morphine-augmentation (47% versus 86%, $p = 0.0015$). When the analysis was confined exclusively to the patients who underwent surgery, the PPV was 59% versus 86%, $p = 0.02$.

TABLE 2
Efficacy of Delayed Imaging

Authors	No. of cases	AC%	Sen	Spc	PPV	NPV
Weissmann et al. (1)	138	87%	97.5%	94%	99%	84%
Choy et al. (3)	30	80%	100%	33%	86%	100%
Mauro et al. (13)	33	76%	100%	50%	86%	100%
Total	201	85%	98%	71%	95%	88%
Total*	201	49%*	98%	71%	76%*	97.4%*

*Recalculated PPV and NPV using 49% AC%.

AC% = percent of patients with acute cholecystitis; Sen = sensitivity; and Spc = specificity.

There was no statistically significant difference in the NPV of the two techniques (100% versus 88%, $p = 0.39$). Most of the patients in whom the gallbladder was visualized did not have an operation, as has been the case in most previous reports. There was not enough statistical power to calculate a NPV for these few subjects.

Literature Review and Analysis

Delayed Imaging. When cases with early GB visualization were excluded from the analysis, there was a total of 201 patients who had delayed imaging in three previous reports (1,3,13). Of these patients, 170 (85%: range 76%–88% in each report) had acute cholecystitis. There were 167 true-positive (TP), nine false-positive (FP), 22 true-negative (TN) and three false-negative (FN) studies, for an overall sensitivity of 98% (97%–100%), a specificity of 71% (33%–94%), a PPV of 95% (86%–99%) and a NPV of 88% (84%–100%) (Table 2).

Morphine-Augmentation. Data presented in six reports were analyzed (3,5–9). Of a total of 283 patients with morphine-augmentation, 138 (49%: range 33%–67% in each report) had acute cholecystitis. There were 133 TP, 19 FP, 126 TN and 5 FN studies, for an overall sensitivity of 96% (range: 94%–100%), a specificity of 87% (69%–100%), a PPV of 87.5% (60%–100%) and a NPV of 96% (92%–100%) (Table 3).

DISCUSSION

A previous review suggested that the sensitivity and specificity of cholescintigraphy may be as high as 94%–

100% (1). However, delayed imaging is required to achieve this level of accuracy (1,2). Delayed imaging can be logistically inconvenient and potentially disadvantageous to the patient, and may not be feasible in some clinical settings. Furthermore, the efficacy of delayed imaging alone (excluding cases with early gallbladder visualization) has not been independently evaluated.

Morphine augmentation appears to be a useful alternative to delayed imaging (3–8). However, only one of the seven morphine reports that we reviewed compared the efficacy of the two techniques directly (3). In this particular study, delayed imaging was carried out for only 2.5 hr, and the rate of acute cholecystitis was 80% in patients who had delayed aging. This rate is higher than the frequency of acute cholecystitis in the six other morphine augmentation studies we reviewed. This may be only one of several reasons why an alternative comparison of the two techniques seems necessary.

The NPV for visualization within 1 hr was 97.7% (210/215) in our sample, which is essentially identical to 98.1% (155/158) from the data reported by Weissmann et al. (1). Our data also indicate that the sensitivity and NPV of delayed imaging are excellent, even when patients whose gallbladder visualized within 1 hr are excluded. We feel that one reason there were no false-negatives in our delayed imaging group was related to the small number of patients in that subsample.

On the other hand, the specificity and PPV of delayed imaging were surprisingly poor in our patient population.

TABLE 3
Efficacy of Morphine Augmentation

Authors	No. of cases	AC%	Sen	Spc	PPV	NPV
Choy et al. (3)	36	67%	96%	100%	100%	92%
Keslar et al. (5)	31	62%	100%	83%	90%	100%
Vasquez et al. (6)	39	33%	100%	85%	76%	100%
Flancbaum et al. (7)	68	43%	97%	95%	93%	97%
Fink-Bennett et al. (8)	61	61%	95%	96%	97%	92%
Fig et al. (9)	48	33%	94%	69%	60%	96%
Total	283	49%	96%	87%	87.5%	96%

See Table 2 for definitions.

This may be due in part to the fact that there were a large number of patients with chronic cholecystitis in our sample. Most patients with false-positive results were found to have chronic cholecystitis. Many cases of acute cholecystitis may be erroneously classified as chronic if strict pathologic criteria (e.g., transmural inflammatory changes), are employed instead of more liberal criteria (e.g., intimal infiltration), which, in turn, may alter the apparent efficacy of the test (14). However, this may not have been an issue in this sample because the pathologists in our institution used liberal criteria. Therefore, the large number of patients with chronic cholecystitis in our sample appears to have been a real finding.

Combining the data from the morphine studies in the literature produced a lower PPV (87.5% versus 95%), and a higher NPV (96% versus 88%) than the PPV and the NPV calculated from the three conventional delayed imaging studies. This observation seems inconsistent with our results, which showed a higher PPV, and a lower, but statistically insignificant, NPV for morphine augmentation. However, it must be noted that the patient populations in the two combined series were considerably different (Tables 2 and 3). An average of 49% of the patients in the morphine protocols had acute cholecystitis, compared to 85% of the patients in the delayed imaging studies. In our series, acute cholecystitis was present in 17 of the 46 patients (37%) in the delayed imaging group, and 26 of the 45 patients (58%) in the morphine group. The frequency of acute cholecystitis in both of our study groups was within the range found in the morphine protocols (33%–67%).

When the prevalence of a disease varies substantially in two groups of patients being tested with different methodologies, measurements of sensitivity and specificity provide a more accurate description of test efficacy than the predictive values. The sensitivity of morphine augmentation that was calculated from the previous reports was similar to the sensitivity calculated from the previous reports of delayed imaging (96% versus 98%, $p = 0.25$). The specificity of morphine augmentation was significantly higher (87% versus 71%, $p = 0.028$).

An alternative approach for comparing the PPV and NPV in this situation is to apply the same disease prevalence to two techniques. If only 49% (prevalence in the morphine group) of the patients in the delayed-imaging group are assumed to have acute cholecystitis instead of 85% (prevalence in the delayed imaging group), and a sensitivity of 98% and a specificity of 71% of the delayed imaging techniques are applied, the PPV and NPV of delayed imaging become 76% and 94%, respectively, instead of 95% and 88% (see Appendix and Table 3). This recalculated PPV is, although not as low as the value in our series, still significantly lower than the 87% PPV of morphine-augmentation ($p = 0.014$). The recalculated NPV varies by less than 2% from the 96% NPV of morphine-augmentation ($p = 0.50$). These findings are consistent with our results.

CONCLUSION

Our findings appear to agree with previous reports that have suggested that gallbladder visualization within 1 hr has a very high negative predictive value for acute cholecystitis (1). However, nonvisualization on the delayed images appears to be a nonspecific finding. We have found that morphine-augmentation can be quite helpful in these cases. It seems to have a reasonably good PPV that is significantly better than that of delayed imaging. Our expanded series failed to show a statistically significant difference between the NPV of morphine-augmentation and that of delayed imaging. These results appear to be supported by a reanalysis of previous reports in the literature, although an even larger series comparing the NPV of the two techniques might be even more useful.

APPENDIX

When the entire population is defined as 1,

$$TP + TN + FP + FN = 1,$$

Prevalence = patients with disease,

(1 - Prevalence) = patients without disease.

Then, TP, TN, FP, and FN can be expressed as:

$$TP = Prv \times Sen,$$

$$TN = (1 - Prv) \times Spc,$$

$$FN = Prv \times (1 - Sen),$$

$$FP = (1 - Prv) \times (1 - Spc),$$

where Sen = sensitivity, Spc = specificity and Prv = prevalence.

$$PPV = \frac{TP}{TP + FP} = \frac{Prv \times Sen}{Prv \times (Sen + Spc - 1) - Spc + 1}$$

and

$$NPV = \frac{TN}{TN + FN} = \frac{(1 - Prv) \times Spc}{Prv \times (1 - Sen - Spc) + Spc}$$

REFERENCES

1. Weissmann HS, Freeman LM. The biliary tract. In: Freeman LM, eds. *Freeman and Johnson's clinical radionuclide imaging*, third edition. Orlando: Grune & Stratton, Inc.; 1984:879-1049.
2. Drane WE, Nelp WB, Rudd TG. The need for routine delayed radionuclide hepatobiliary imaging in patients with intercurrent disease. *Radiology* 1984; 151:763-769.
3. Choy D, Shi EC, McLean RG, Hoscho R, Murray IPC, Ham JM. Cholescintigraphy in acute cholecystitis: use of intravenous morphine. *Radiology* 1984;151:203-207.
4. Kim EE, Pjura G, Lowery P, Nguyen M, Pollac M. Morphine augmented cholescintigraphy in the diagnosis of acute cholecystitis. *AJR* 1986;147: 1177-1179.
5. Keslar PJ, Turbiner EH. Hepatobiliary imaging and the use of intravenous morphine. *Clin Nucl Med* 1987;12:592-596.
6. Vasquez TE, Greenspan G, Evans DG, Halpern SE, Ashburn WL. Clinical efficacy of intravenous morphine administration in hepatobiliary imaging for acute cholecystitis. *Clin Nucl Med* 1988;13:4-6.

7. Flancbaum L, Alden SM. Morphine cholescintigraphy. *Surg Gynecol Obstet* 1990;171:227-232.
8. Fink-Benett D, Balon H, Robins T, Tsai D. Morphine-augmented cholescintigraphy: its efficacy in detecting acute cholecystitis. *J Nucl Med* 1991;32:1231-1233.
9. Fig LM, Wahl RL, Stewart RE, Shapiro B. Morphine-augmented hepatobiliary scintigraphy in the severely ill: caution is in order. *Radiology* 1990;175:467-473.
10. Mack JM, Slavin JD, Spencer RP. Two false-negative results using morphine sulfate in hepatobiliary imaging. *Clin Nucl Med* 1989;14:87-88.
11. Achong DM, Oates E. The cystic duct sign during morphine-augmented cholescintigraphy. *Clin Nucl Med* 1991;16:627-629.
12. Kim CK, Juweid M, Woda A, Rothstein RD, Alavi A. Hepatobiliary scintigraphy: morphine-augmented versus delayed imaging in patients with suspected acute cholecystitis. *J Nucl Med* 1993;34:506-509.
13. Mauro MA, McCartney WH, Melmed JR. Hepatobiliary scanning with ^{99m}Tc-PIPIDA in acute cholecystitis. *Radiology* 1982;142:193-197.
14. Freitas JE, Coleman RE, Nagle CE, Bree RL, Krewer KD, Gross MD. Influence of scan and pathologic criteria on the specificity of cholescintigraphy: concise communication. *J Nucl Med* 1983;24:876-879.

(continued from page 7A)

FIRST IMPRESSIONS

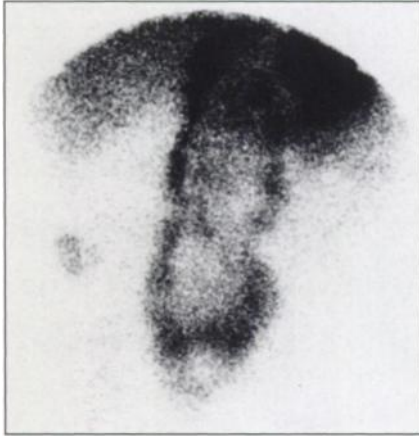

FIGURE 1.

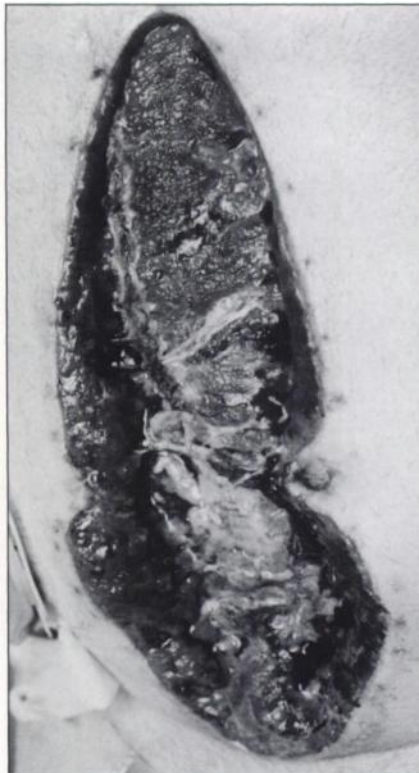


FIGURE 2.

PURPOSE

A 46-yr-old diabetic male was admitted with progressive myositis. While in the hospital, he had massive gastrointestinal bleeding. At laparotomy, the colon was found to be necrotic and a total colectomy was performed. Postoperatively, the patient became febrile and infection of the surgical wound was identified, which required opening the incision. Although wound infection was assumed to be the cause of the pyrexia, an ¹¹¹In-WBC study was performed to rule out an intra-abdominal abscess. Images of the abdomen and pelvis obtained at both 3 hr and 24 hr showed a large, vertically oriented "hour glass-shaped" area of uptake in the midline and a smaller area of uptake in the right lower quadrant (Fig. 1). On examining the patient, these findings correlated to a large surgical wound that had been left open for healing by secondary intention to the ileostomy opening (Fig. 2). No other foci of uptake were identified to suggest intra-abdominal abscess.

TRACER

Indium-111-WBCs, 600 μ Ci.

ROUTE OF ADMINISTRATION

Intravenous injection.

TIME AFTER INJECTION

3 and 24 hr.

INSTRUMENTATION

Gamma camera.

CONTRIBUTORS

Einat Evin-Sapir and Robert H. Martin

INSTITUTION

Division of Nuclear Medicine, Department of Radiology, Victoria General Hospital, Halifax, Canada.