

A Perspective on the Evolving story of PSMA Biology and PSMA Based Imaging and Endoradiotherapeutic Strategies.

Short running title: PSMA biology

Denise S. O'Keefe¹, Dean J. Bacich¹, Steve S. Huang², Warren D.W. Heston^{3*}

1 Dept. of Urology, Univ. Texas Health Science Center at San Antonio, Mail code 7845, 7703 Floyd Curl Drive, San Antonio 78229. okeefed@uthscsa.edu 210 562 4098.

2 Imaging Institute and Cancer Biology Dept., Lerner Research Institute, Cleveland Clinic, Cleveland OH.

3 Dept. of Cancer Biology, Lerner Research Institute and Glickman Urologic Institute Cleveland Clinic, 9500 Euclid Avenue, Cleveland OH, 44195. hestonw@ccf.org 216 44 8181. Fax 216 445 6269.

Key Words: Prostate Cancer, Angiogenesis, Tumor Neovasculature, Imaging, Endoradiotherapy. PSMA, GCP II, FOLH1, NAALADASE, Inflammatory Bowel Disease, folate

Word count: 6549

Noteworthy points are on page 21

Financial support: This work was supported in part by NIH Grant R01 CA138444

(Denise O'Keefe and Dean Bacich).

ABSTRACT

We will review the evolution of knowledge of the biology of Prostate-Specific Membrane Antigen (PSMA) and how the translation to therapy has also developed. The usual key to discovery is a realistic model for experimentation and hypothesis testing. This is especially true for the prostate where the human prostate differs significantly from that of other often used species for research models. We will emphasize the genetic characterization of PSMA, The nature of the PSMA protein and its role as a carboxypeptidase, with differing important substrates and products in different tissues. We will give special prominence to its importance as a target for imaging and therapy in prostate cancer and its under-developed role for imaging and targeting the neovasculature of tumors other than prostate cancer. Lastly we will bring attention to its importance in other non-prostatic tissues

CLONING AND EXPRESSION OF PROSTATE-SPECIFIC MEMBRANE ANTIGEN (PSMA)

As with most discoveries and the requirement for an appropriate model, the PSMA story began with the development of the prostate cancer cell line LNCaP (1) in 1983. It was the first cell model that maintained a number of key bio-markers in keeping with real human prostate cancers both *in vitro* and *in vivo*. Horoszewicz then reported on developing a monoclonal mouse antibody, 7E11-C5, to the membranes of this cell line (2). This antibody eventually was used to develop the first Food and Drug Administration-approved imaging agent for prostate cancer, ProstateScint. We used the

7E11-C5 antibody for immunoprecipitation, peptide micro-sequencing, and subsequently degenerate primers to clone and sequence the complementary DNA encoding PSMA (3). Using a ribonuclease protection assay PSMA was predominantly expressed in the prostate with much lower levels of expression in brain, salivary gland and small intestine. Therefore we named the encoded protein, Prostate-Specific Membrane Antigen.(4). The deduced amino acid sequence established that the gene encoded for a type two membrane protein with a region of homology to the transferrin receptor. *In vitro* expression of PSMA was decreased three to ten-fold by treatment with androgens.(4). The short intracellular region of 19 amino acids was subsequently determined to be the target recognized by the Prostatecint antibody likely explaining Prostatecint's poor performance as an imaging agent (5).

A concern we had was that our initial studies suggested that PSMA mapped to two nearly identical regions; one on chromosome 11p11.2 and one on 11q14.3 (6). We designated the one on 11q14.3 as PSMA-Like. We were able to distinguish the PSMA and PSMA-like genes because our group had fully sequenced the entire PSMA gene prior to the completion of the human genome project and reported its full characterization (7).

Although the two genes are very similar, the PSMA-like encoded protein lacks the transmembrane domain and is therefore a cytosolic protein and would not interfere with clinical targeting of PSMA (7). There was also reason to consider that the level of PSMA mRNA may under-represent protein expression because membrane proteins can be relatively stable and radioimmunoassay measurement of PSMA protein found the

amount of PSMA in the prostate to be 1000 times the amount of that found in liver or kidney, the tissues where both PSMA and PSMA-Like mRNA are expressed (8).

In collaboration with investigators in Australia, we were able to identify which regions of the PSMA gene were responsible for the high level of expression in the prostate and prostate cancers (9). The identification of this enhancer sequence served for a number of groups to use this information to design gene therapies specifically targeted toward prostate tumors (10). The lack of expression of PSMA in the prostate of most mammals, including rodents and apes, most likely relates to the gene duplication event that occurred 22 million years ago followed by acquisition of factors able to activate expression in the prostate sometime after the separation of chimps and humans, 6-7 million years ago (6,7,11).

As noted, PSMA has substantial sequence and structural homology with transferrin receptors. The crystal structure of PSMA was first solved using the existing transferrin receptor 1 crystal structure as the model for molecular replacement (12). Like the transferrin receptor, the extracellular portion of PSMA has three domains: apical, helical and protease domains. PSMA exists as a symmetric homodimer with a large (approximately 4,600 Å²) dimerization interface from the association of the two helical domains. The apical domain of PSMA contains the binding site of the J591 antibody. The active site and substrate binding cavity of the peptidase lies deep within the PSMA structure and is formed with contribution from all three domains. There are two zinc atoms at the active site; the zinc atoms are coordinated by residues from the protease

domain. As expected, the position of zinc atoms, the catalytic water and their coordinating amino acid residues are nearly identical to other binuclear zinc exopeptidases (12).

Tissue Distribution of the PSMA Protein

To determine the tissue distribution of PSMA protein expression, we employed immunohistochemistry using the 7E11-C5 antibody. In normal tissue we observed expression in a sub-set of kidney proximal tubules, duodenal brush border cells and cells in the colonic crypts. Most other cell types were lacking in expression. In the normal and hyperplastic prostate staining was weak or absent. In prostatic cancer 33 of 35 primary tumors were positive, 7 of 8 metastatic lymph nodes were positive and 8 of 18 bone metastases were positive. Other cancer cell types were PSMA negative, **but in many non-prostatic tumors, the tumor-associated neovasculature was positive for PSMA expression while the neovasculature in prostate cancers was negative** (13). Other investigators using the 7E11-C5 antibody also found benign prostatic hyperplasia to have less expression than normal prostate, which in turn was less than the expression in prostatic intraepithelial neoplasia. PSMA expression in cancer increased with grade with the highest expression in metastatic deposits; 94% of lymph nodes and 100% of bone metastases exhibiting strong apical membrane staining, although it did not correlate with tumor stage (14). In another investigation, Ross reported that both pathologic stage ($p=.0018$) and PSMA ($p=.002$) were independent predictors of biochemical recurrence with overexpression of PSMA in the primary tumor independently predicting disease outcome (15).

BIOLOGICAL FUNCTION OF PSMA

The PSMA mRNA transcript encodes a protein of 750 amino acids and a predicted molecular weight of 84kD, however due to protein glycosylation it appears as greater than 100kD (16,17). PSMA glycosylation is required for enzymatic activity (16,17), and exists as both dimer and monomeric forms on the apical cell surface (18). A second generation antibody developed in the Bander laboratory, J591, was found to increase the rate of internalization of PSMA. Similar to transferrin, when PSMA is internalized it follows intracellular trafficking to the recycling endosomal compartment (19). The short 19 amino acid intracellular domain has a novel MXXXL motif that mediates the internalization by interacting with the clathrin adaptor protein-2 complex (18). The intracellular domain binds to the structural protein filamin A as part of a larger macromolecular complex including beta-1-integrin, p130 Crk-associated substrate, c-SRC and the Epidermal Growth Factor Receptor that ultimately activates the Protein Kinase B (AKT) and Mitogen-Activated Protein kinase pathways to promote proliferation and survival (20). These *in vitro* findings are supported by the recent findings in *in vivo* xenograft models showing that PSMA activates the AKT pathway (21).

The enzymatic activity of PSMA is considered part of the cocatalytic zinc metallopeptidase family M28 (22). We observed strong expression of PSMA in the proximal small intestine and we were able to identify polyglutamated folate as a substrate (23). PSMA removes the gamma-linked glutamates from folate providing de-glutamated folate for absorption and nutrition, leaving a single alpha-linked glutamate

attached. The official gene name of PSMA is folate hydrolase 1 (FOLH1), reflecting its major role in folate uptake, however although PSMA usually acts as a glutamate carboxypeptidase, its major substrate can differ in different tissues.

Prostate and Prostate Cancer

The prostate of mammals can differ substantially both in location, lobation, and histological features (24). All mammalian prostates are dependent on androgens for growth and maintenance. The different mammalian prostates however can differ dramatically in the nature of their secretions. Indeed, as has been pointed out already the mouse prostate does not produce PSMA to any extent, is multi-lobated and rarely develops cancer, while the human structure is encased as one lobe and makes large amounts of proteins like prostate-specific antigen (PSA), prostatic acid phosphatase, and PSMA. The development of prostate cancer in humans is common but rarely observed in other mammalian species with the exception of dogs (24). Thus it is difficult to consider the mouse prostate a good model for aspects of prostate function that differ significantly from that found in the human such as PSMA.

We cloned the mouse homolog of human PSMA and generated a knockout mouse of the gene, known as Folate hydrolase I (25-27). Others have also reported that the mouse prostate is lacking in PSMA/Folh1 expression (the protein is also referred to as glutamate carboxypeptidase II,GCPII) and have reported on another related glutamate carboxypeptidase (GCP III) which has similar enzymatic features but with different

tissue distributions (11,28). PSMA expression in human cancers increases with increasing cancer aggressiveness. Despite the fact that there is no expression of PSMA/Folh1 in the mouse prostate or genetic tumor models such as the popular TRansgenic-Adenocarcinoma of the Mouse Prostate, commonly known as the TRAMP, its expression at other sites such as brain, kidney and salivary glands still makes it a useful *in vivo* model for studying off-target side effects for targeting approaches using xeno-transplanted human tumors (28). It should also be remembered that GCPIII would also likely exhibit uptake of PSMA-targeted low molecular weight ligands and to keep those off-site targets of ovary, uterus, testes, heart, lung and skeletal muscle in mind as well (28). Fortunately PSMA is located on the apical surface of cells keeping it less accessible to targeting.

To humanize the mouse prostate, Yao *et al.*, developed a transgenic mouse model expressing human PSMA (hPSMA) in the luminal epithelial cells in the mouse prostate ventral, lateral and dorsal lobes (29). As the expression of hPSMA in these mice did not lead to cancer in the short term, they explored the effect of hPSMA expression specifically in the tissue recombinant prostatic recapitulation model, comparing hPSMA expressing versus wild-type mouse. They found 47% of the PSMA transgenic prostate recombinants demonstrated adenocarcinoma by 24 weeks while no cancer was observed in the wild-type tissue recombinants. They reached the conclusion that PSMA played a role in promoting prostate carcinogenesis, with moderate expression associated with prostate cancer development and PSMA negative cells being unable to become cancers (29). This is in keeping with the findings of Rajasekaran *et al.*, who

observed that high PSMA expression decreases cell cycle time in G2/M from its association with the anaphase promoting complex setting cells up for potential of aneuploidy and carcinogenesis (30).

Folate (vitamin B9), PSMA and Prostate Cancer

Intracellular folate concentration has been described as a two-edged sword (31). Low levels are associated with increased susceptibility to chromosome damage, while high levels have been noted to increase tumor growth. Indeed *in vitro* it has been reported that LNCaP and PC-3 prostate cancer cell lines show increased growth and invasiveness when exposed to high folate concentrations (32). However grains and cereals in the U.S. are now supplemented with folic acid to reduce the potential for neural-tube defects in newborns. Cole et al. hypothesized that folic acid supplementation could prevent colorectal adenoma in patients who had a history of the disease. However they found that in fact, mild supplementation with folic-acid led to an increased risk of advanced adenomas (33). Furthermore, there was a significant over-representation of prostate cancer in the folate supplemented group (age-adjusted hazard ratio 2.63) even years after the trial ended (34). Intriguing in this regard, is a case report in which a patient with hormone refractory prostate cancer had a rising PSA while undergoing docetaxel treatment. The PSA rise occurred as the patient began taking folate supplements, with his serum folates reaching 304nM. After stopping the supplementation and fortified foods his serum folate dropped to 9nM and his PSA dropped to 2 ng/ml within two weeks (35).

Folate levels also modulate the activity of PSMA; in *in vitro* studies, Yao *et al.*, demonstrated increased invasiveness under low folate conditions, and a growth advantage of PSMA transfected PC-3 cells in physiologic folate compared to PC-3 cells lacking PSMA (32). As PSMA may also internalize its ligands, it is possibly involved in folate uptake in prostate tissue. Indeed Yao *et al.* found that PSMA expressing cells also demonstrated a two-fold increase uptake of folate suggesting that PSMA may be associated with folate transport (32).

Jan Grimm's research team has documented that the level of PSMA expression and the generation of glutamate from its substrate polyglutamated vitamin B9 (which is the general term for folates) provides the signal necessary to activate the AKT pathway *in vitro*, and that PSMA expression correlates with prostate cancer aggressiveness (21). They used Memorial Sloan Kettering's cohort of 168 primary prostate cancers that combined full clinical annotation with extensive gene expression and copy number profiling at the time of surgery. In their well annotated cohort, elevated PSMA is associated with disease relapse and metastasis and PSMA levels also correlated with the phosphorylation with eIF4E-binding protein 1, a downstream target of the mammalian Target of Rapamycin. In addition PSMA expression levels positively correlated with phosphorylation of AKT and its downstream targets. Using *in vitro* studies with polyglutamated folates, they demonstrated that glutamate released by the enzymatic activity of PSMA was responsible for the signaling via the metabotropic glutamate receptor 1, activating the phospholipase C pathway. Recently, it was

reported that combined androgen receptor and Phosphoinositide 3-kinase inhibition is required for therapeutic efficacy in prostate cancer (36). Since inhibitors of the latter pathway have off-target effects, Grimm's research group asked if inhibition of PSMA could be an alternative approach (21). They examined a combination therapy of androgen receptor and/or PSMA blockade using enzalutamide and/or 2-Phosphonomethyl pentanedioic acid (2-PMPA, an inhibitor of PSMA enzymatic activity) *in vivo* in mouse xenograft models. They found that either enzalutamide or 2-PMPA could retard tumor growth, but what was most dramatic was that the combination resulted in regression of 90% of the tumors. They then asked whether it would be possible to use imaging to see if this pathway was operative in patients to determine if that might identify patients for this type of combination therapeutic approach. They examined patients using PET/MRI and the PSMA specific probe Gallium 68-PSMA-11-CC prior to prostatectomy and histopathological evidence for PSMA and phosphorylated AKT and found a strong correlation. They argue that not only should this approach be considered in prostate cancer, but because PSMA is strongly expressed in the neovasculature of some tumors and that a number of tumors express metabotropic glutamate receptors that combined therapies should be considered in those situations as well (21).

We have previously reported that mice carrying LNCaP xenografts either expressing PSMA or knocked down for PSMA expression have superior take rates for tumors expressing PSMA (16/18 versus 10/18). Furthermore, the tumors that expressed PSMA grew significantly larger in response to increasing dietary folate, however the non-PSMA

expressing tumors remained small and there was no significant differences in tumor sizes between different levels of folate containing diets (37). These findings suggest that given most prostate tumors express PSMA, patients should be mindful about which vitamins and fortified foods they consume.

The Role of PSMA in Tumor associated neovasculature

As noted PSMA is expressed in the tumor neovasculature of some tumors other than prostate cancer (13,38). The question was whether this was a human only aspect or if it was common in other animal models as well. In a collaboration with Shapiro's research group using our knockout mouse model, we used an *in vivo* matrigel plug assay to evaluate the activation of endothelial cell ingrowth (neovascularization) into the matrigel plug. The PSMA knockout animals responded with dramatically attenuated vascular growth and reduced hemoglobin content when compared with the wildtype animals (39). Similarly the PSMA inhibitor 2-PMPA also blocked neovascularization. Examination of different extracellular matrix proteins demonstrated that vascular invasion by PSMA was mediated by laminin. Further studies showed that the carboxypeptidase activity of PSMA resulted in endothelial cell activation through integrin focal adhesion kinase phosphorylation and subsequent PAK activation (39) and that the laminin derived peptides of LQE, IEE, and LNE were substrates for PSMA (39). They further identified that LQ, a product of PSMA's enzymatic cleavage of LQE efficiently activates endothelial cells *in vitro* and enhances angiogenesis *in vivo* and is dependent on beta-1-integrin activation (39).

PSMA BASED IMAGING AND TARGETED THERAPY

Antibody-Based Strategies

It has been a dramatic theranostic evolution from the Ehrlich's imagined antibody "silver bullet" specific for cancer to the reality of delivering sufficient radionuclide dose to treat cancer while avoiding toxicity to normal tissues. In that light PSMA as a target for imaging and therapy has been undergoing an evolution. The first Food and Drug Administration approved imaging agent for PSMA was capromab pendetide, Proscint, a mouse monoclonal antibody (7E11-C5) linked to Indium 111 for SPECT imaging in patients with rising PSA levels post-prostatectomy. However there were specificity and sensitivity issues (40). Dr. Bander's research group identified another antibody, J591, which binds to the extracellular portion of PSMA that was more sensitive than technetium scans for detection of bone metastatic disease. In a phase 2 study, treatment using J591 chelated with Lu-177 (65-70mCi/m²) was studied in 47 patients who progressed on hormonal therapy, of which half had received prior cytotoxic chemotherapy (41). Ten percent of patients had a PSA decline of 50% or greater. One of 12 with measureable disease experienced a radiographic response and sites of prostate cancer were targeted in 44 of 47 sites as determined by planar imaging. All experienced reversible hematologic toxicity. The J591 antibody too is evolving; it has been humanized and undergone genetic engineering to generate a minibody, 89Zr-Df-IAB2M, which is 80kD in size compared to the 150kD J591 antibody (42). Monomeric and dimeric single chain Fv fragment anti-PSMA agents are also being developed as well as multimers using different targets including PSMA (43). These agents have the advantage of more rapid clearance which could reduce the toxicity found with the full

size antibody, and reduce the time required before the antibody can be readily imaged. Interestingly, the antibodies and derivatives used to date have not imaged salivary glands nor has that been a site of toxicity.

Ligand-Based Strategies

The further evolution of PSMA targeting involves low-molecular weight ligands based on the glutamate-urea-cargo carrying derivatives (MIP-1095, MIP-1404, PSMA-11/617/1007, DCFPyl, PSMA I&T) with first-in-man studies demonstrating good imaging and therapeutic activity for F-18 and I-131 linked radionuclides that are being evaluated at a number of U.S. sites in ongoing clinical trials in preparation for regulatory approval, the results of which should be available in early 2019 (44-47). In studies outside the U.S., especially in Germany, imaging and treatment targeting PSMA in hormone refractory disease has been performed with other low molecular weight compounds linked to Gallium 68 for PET imaging and Lu-177 for endoradiotherapeutic treatment. These low molecular weight ligands have all demonstrated excellent imaging of prostate cancer at distant metastatic sites as well as local-regional nodes and identification of areas of aggressive cancer within the prostate itself (48).

Recent experience with Lu-177 ligands has been extensive (49). These patients are being treated on a compassionate use basis in Germany, nevertheless a retrospective compilation of data from 12 centers and 145 patients receiving doses of 2-8 GBq per cycle for up to four cycles achieved an overall biochemical response rate of 45% (50 %

or greater decline in PSA) with 40% of patients responding after a single dose. Bone pain improved in 33-77%. Grade 3-4 hematotoxicity occurred in 18 patients with 10%, 4%, and 3% experiencing anemia, thrombocytopenia, and leucopenia. Xerostomia occurred in 8%, which is quite different from antibody treatment in which no salivary gland toxicity is observed. Elevated alkaline phosphatase and visceral metastases were negative predictors of response (49,50).

Even though low molecular weight anti-PSMA Lu-177 treatment produced an impressive response for such heavily pretreated patients nevertheless, 40% of the patients did not respond. Kratochwil and colleagues began a trial using Actinium 225 in heavily pretreated castration-resistant prostate cancer patients and demonstrated that treatment with an alpha emitter could overcome resistance seen to beta emitters (51). In an empiric dose findings series they found that treatment with 100 kBq/kg of Actinium 225-PSMA-617 every 2 months was superior for continuing tumor control. Similar results were obtained with 213-Bi-PSMA-617 by Sathekge et al.(52). Indeed many dramatic responses were seen in these heavily pretreated patients (51,52).

These are impressive results considering this is third line therapy facing bulky metastatic disease. Dr. Czernin and Eiber have called on the Food and Drug Administration to approve these agents as they have already had extensive testing in humans with minimal toxicity and excellent imaging and therapeutic responses, even in heavily pretreated patients (53).

Imaging the Neovasculature

In addition to imaging for prostate cancer, PSMA expression in the vasculature of most solid tumors has been exploited by other groups. Using the J591 antibody radiolabeled with Indium 111, Pandit-Taskar and colleagues were able to image the majority of metastatic deposits to the skeleton, lymph nodes and soft tissues from patients with renal, breast and colorectal cancer (54). As PSMA-based detection frequently identifies sites in addition to those visible by standard scanning, a recent study included a therapy resistant patient with renal cancer that was imaged shortly before expiration, and upon death a rapid autopsy was performed. All the sites detected by PSMA imaging were histologically proven clear cell renal cancer with PSMA expression in the tumor vasculature, suggesting that PSMA imaging is more sensitive than standard imaging techniques (55).

OTHER CONSIDERATIONS

Brain PSMA (NAALADASE, GCPII)

Understanding the biological role of PSMA is aided by examining its role in other tissues. Neurochemistry researchers were working on a protein that hydrolysed the brain dipeptide N-acetylaspartylglutamate, NAAG, to yield N-acetylaspartate and glutamate which they called the protein **NAALADASE** (56). Carter and colleagues cloned rat brain NAALADASE and found that it had 85% homology with human PSMA. In the brain it is a membrane-bound enzyme found on the extracellular face of glia. Its substrate, NAAG, is found in many types of neuronal cells in the brain, spinal cord and

peripheral nerves. There are at least two distinct neurotransmitter functions for NAAG. Under basal condition when PSMA/GCPII activity is relatively low NAAG dampens synaptic activity via metabotropic glutamate receptor III activation and NMDA receptor blockade. However during stimulated conditions NAAG release and PSMA/GCPII activity are enhanced resulting in excess glutamate generation and pathological receptor activation (56).

Using the Bacich PSMA knockout mouse it was observed that mice lacking PSMA/GCPII were resistant to nerve damage induced via physical, chemical and hypoxic conditions, confirming that PSMA under these conditions cleaves the neuroprotective NAAG released by damaged neurons to NAA and excitotoxic glutamate, exacerbating nerve damage (27). PSMA/GCPII is expressed in the spinal cord and peripheral nerves. Nevertheless PSMA imaging has not demonstrated uptake in spinal cords that do not have prostate cancer metastasis, and because of the blood brain barrier no imaging of brain PSMA/GCPII has been observed.

Intestinal and Colonic PSMA

PSMA expression in the gastrointestinal tract is responsible for the hydrolysis of the gamma-linked glutamates from polyglutamated folates found in foods leaving intact the alpha-linked glutamate of folate. Folate, with its remaining alpha-linked glutamate is then transported into enterocytes and subsequently transported to the liver to provide folate for nutrition (23).

We originally observed PSMA expression in the colonic crypt in what we thought were neuroendocrine like cells (13). Slusher's research group, citing recent gene-profiling analysis which demonstrated significant up-regulation of PSMA expression in patients with inflammatory bowel disease, experimentally determined that there was an increase in PSMA/GCPII enzymatic activity of 4 to 41 fold in patient surgical specimens of affected inflammatory colon when compared with non-inflamed areas. To examine this relationship they used an animal model of inflammatory bowel disease either using dextran sodium sulfate or IL 10 -/- mice, and demonstrated an increase in PSMA/GCPII expression (57). Slusher's group then demonstrated that this inflammation could be attenuated either with the PSMA inhibitor 2-PMPA, or by using the PSMA/GCPII knockout animals of Bacich (26) accompanied by a lower disease activity index. Not only were the PSMA/GCPII knockout mice resistant to dextran treatment, they also had a longer colon length with a healthier mucosa and less neutrophil infiltration with preserved crypts and goblet cells.

Kidney

Most model systems demonstrate PSMA/GCP II/FOLH1 expression in a subset of the kidney proximal tubules (13). The kidneys are a site imaged with the low molecular weight ligands for PSMA, which are rapidly excreted. Indeed in an initial study of Prostate cancer tumor imaging, the uptake in the kidneys was indeed higher in normal kidneys than in the kidneys of the PSMA knockout mice indicating some PSMA-specific binding (58). The knockout animals demonstrate no retention of the low molecular weight ligands, and the animals themselves appear to be healthy with nothing to

suggest there is any negative aspect of kidneys that lack PSMA expression. There is no evidence of any specific enzymatic substrate for PSMA in the kidneys nor why it appears that just a subset of proximal tubules express PSMA. Of note, the knockout mice do have a slight difference in blood pressure (27).

CONCLUSIONS

The PSMA gene was cloned in the Urology Research Laboratory at Memorial Sloan Kettering Cancer Center in 1993. William R Fair was chair of Urology at that time with Dr. Willet F. Whitmore having previously stepped down as chair. Dr. Whitmore was considered the Dean of Urologic Oncology. He was not a fan of PSA and was a proponent of expectant management at the time, (noted as active surveillance in today's parlance). He died from metastatic prostatic cancer in 1995 (59). He was noted for raising the question, "Is cure necessary for those in whom it is possible and is cure possible in for those in whom it is necessary". For him, a cure was necessary but not possible. Here we are 24 years later and at the Prostate Cancer Foundation meetings a presentation was made demonstrating the use of PSMA targeted radiotherapy in patients with castration resistant prostate cancer. The patient was imaged with Gallium 68 labelled low molecular weight PSMA ligand which identified hundreds of metastatic sites involving bone and soft tissues. He was subsequently treated with PSMA targeted low molecular weight ligand linked with Actinium 225 for therapy. All those sites of metastatic disease disappeared and his PSA came down from the thousands to undetectable, an amazing result. In talking with that patient at breakfast, he was asked how he was doing and he felt great. He was asked about the symptom of dry mouth and

he said he drinks a lot of water. So today there will be patients in whom the answer to Dr. Whitmore's question will be that cure is both necessary and possible. Indeed, PSMA imaging can be used to help identify high grade localized prostate cancer and prostate cancer that has spread local regionally and to distant metastatic sites and as well as used for therapy. It may even be that PSMA inhibition along with androgen deprivation therapy may further slow progression of the disease (21). In terms of toxicity, the salivary gland needs to be considered. Both for imaging and therapy, a modification may be to alter the structure of the low molecular PSMA targeting ligand to decrease uptake at off target sites while retaining the high uptake into the tumor (58).

Dr. Fair died from complications of metastatic colon cancer (60). Given the presence of PSMA expression in the neo-vasculature of many types of tumors other than prostate cancer, hopefully evolving strategies and innovations in the type of payload targeted to PSMA will eventually prove useful against other cancers and will result in the answer that cure is possible for those patients in whom it is necessary as well.

NOTEWORTHY

- The high expression of PSMA in the human prostate is unique as no other mammals from mouse to monkey, with the possible exception of the dog, express detectable protein; this expression increases further in prostate cancer with increasing grade, and in metastatic disease.
- PSMA expression is also seen in tumor-associated angiogenesis of almost all solid tumors other than prostate, but not in normal vasculature.
- The role of PSMA in the metabolism of folates may contribute to cancer progression, as shown in Figure 1.
- The theranostic evolution of radionuclide PSMA targeted ligands has generated encouraging improvements in imaging and therapy especially with low molecular weight-linked positron and alpha emitters.

Acknowledgements: This work was supported in part by NIH Grant R01 CA138444

(Denise O'Keefe and Dean Bacich).

References Cited

1. Horoszewicz JS, Leong SS, Kawinski E, et al. LNCaP model of human prostatic carcinoma. *Cancer Res.* 1983;43:1809-1818.
2. Horoszewicz JS, Kawinski E, Murphy GP. Monoclonal antibodies to a new antigenic marker in epithelial prostatic cells and serum of prostatic cancer patients. *Anticancer Res.* 1987;7:927-935.
3. Israeli RS, Powell CT, Fair WR, Heston WD. Molecular cloning of a complementary DNA encoding a prostate-specific membrane antigen. *Cancer Res.* 1993;53:227-230.
4. Israeli RS, Powell CT, Corr JG, Fair WR, Heston WD. Expression of the prostate-specific membrane antigen. *Cancer Res.* 1994;54:1807-1811.
5. Troyer JK, Beckett ML, Wright GL. Location of prostate-specific membrane antigen in the LNCaP prostate carcinoma cell line. *Prostate.* 1997;30:232-242.
6. O'Keefe DS, Bacich DJ, Heston WD. Comparative analysis of prostate-specific membrane antigen (PSMA) versus a prostate-specific membrane antigen-like gene. *Prostate.* 2004;58:200-210.
7. O'Keefe DS, Su SL, Bacich DJ, et al. Mapping, genomic organization and promoter analysis of the human prostate-specific membrane antigen gene. *Biochim Biophys Acta.* 1998;1443:113-127.
8. Sokoloff RL, Norton KC, Gasior CL, Marker KM, Grauer LS. A dual-monoclonal sandwich assay for prostate-specific membrane antigen: levels in tissues, seminal fluid and urine. *Prostate.* 2000;43:150-157.
9. Watt F, Martorana A, Brookes DE, et al. A tissue-specific enhancer of the prostate-specific membrane antigen gene, FOLH1. *Genomics.* 2001;73:243-254.
10. O'Keefe DS, Uchida A, Bacich DJ, et al. Prostate-specific suicide gene therapy using the prostate-specific membrane antigen promoter and enhancer. *Prostate.* 2000;45:149-157.
11. Aggarwal S, Ricklis RM, Williams SA, Denmeade SR. Comparative study of PSMA expression in the prostate of mouse, dog, monkey, and human. *Prostate.* 2006;66:903-910.

12. Davis MI, Bennett MJ, Thomas LM, Bjorkman PJ. Crystal structure of prostate-specific membrane antigen, a tumor marker and peptidase. *Proc Natl Acad Sci U S A*. 2005;102:5981-5986.
13. Silver DA, Pellicer I, Fair WR, Heston WD, Cordon-Cardo C. Prostate-specific membrane antigen expression in normal and malignant human tissues. *Clin Cancer Res*. 1997;3:81-85.
14. Wright GL, Haley C, Beckett ML, Schellhammer PF. Expression of prostate-specific membrane antigen in normal, benign, and malignant prostate tissues. *Urol Oncol*. 1995;1:18-28.
15. Ross JS, Sheehan CE, Fisher HA, et al. Correlation of primary tumor prostate-specific membrane antigen expression with disease recurrence in prostate cancer. *Clin Cancer Res*. 2003;9:6357-6362.
16. Barinka C, Sácha P, Sklenár J, et al. Identification of the N-glycosylation sites on glutamate carboxypeptidase II necessary for proteolytic activity. *Protein Sci*. 2004;13:1627-1635.
17. Ghosh A, Heston WD. Effect of carbohydrate moieties on the folate hydrolysis activity of the prostate specific membrane antigen. *Prostate*. 2003;57:140-151.
18. Rajasekaran AK, Anilkumar G, Christiansen JJ. Is prostate-specific membrane antigen a multifunctional protein? *Am J Physiol Cell Physiol*. 2005;288:C975-981.
19. Liu H, Rajasekaran AK, Moy P, et al. Constitutive and antibody-induced internalization of prostate-specific membrane antigen. *Cancer Res*. 1998;58:4055-4060.
20. Perico ME, Grasso S, Brunelli M, et al. Prostate-specific membrane antigen (PSMA) assembles a macromolecular complex regulating growth and survival of prostate cancer cells "in vitro" and correlating with progression "in vivo". *Oncotarget*. 2016;7:74189-74202.
21. Kaittanis C, Andreou C, Hieronymus H, et al. Prostate-specific membrane antigen cleavage of vitamin B9 stimulates oncogenic signaling through metabotropic glutamate receptors. *J Exp Med*. 2018;215:159-175.
22. Rawlings ND, Barrett AJ. Structure of membrane glutamate carboxypeptidase. *Biochim Biophys Acta*. 1997;1339:247-252.
23. Pinto JT, Suffoletto BP, Berzin TM, et al. Prostate-specific membrane antigen: a novel folate hydrolase in human prostatic carcinoma cells. *Clin Cancer Res*. 1996;2:1445-1451.
24. Coffey DS. Similarities of prostate and breast cancer: Evolution, diet, and estrogens. *Urology*. 2001;57:31-38.

25. Bacich DJ, Pinto JT, Tong WP, Heston WD. Cloning, expression, genomic localization, and enzymatic activities of the mouse homolog of prostate-specific membrane antigen/NAALADase/folate hydrolase. *Mamm Genome*. 2001;12:117-123.
26. Bacich DJ, Ramadan E, O'Keefe DS, et al. Deletion of the glutamate carboxypeptidase II gene in mice reveals a second enzyme activity that hydrolyzes N-acetylaspartylglutamate. *J Neurochem*. 2002;83:20-29.
27. Bacich DJ, Wozniak KM, Lu XC, et al. Mice lacking glutamate carboxypeptidase II are protected from peripheral neuropathy and ischemic brain injury. *J Neurochem*. 2005;95:314-323.
28. Knedlík T, Vorlová B, Navrátil V, et al. Mouse glutamate carboxypeptidase II (GCPII) has a similar enzyme activity and inhibition profile but a different tissue distribution to human GCPII. *FEBS Open Bio*. 2017;7:1362-1378.
29. Yao V, Parwani A, Maier C, Heston WD, Bacich DJ. Moderate expression of prostate-specific membrane antigen, a tissue differentiation antigen and folate hydrolase, facilitates prostate carcinogenesis. *Cancer Res*. 2008;68:9070-9077.
30. Rajasekaran SA, Christiansen JJ, Schmid I, et al. Prostate-specific membrane antigen associates with anaphase-promoting complex and induces chromosomal instability. *Mol Cancer Ther*. 2008;7:2142-2151.
31. Rycyna KJ, Bacich DJ, O'Keefe DS. Opposing roles of folate in prostate cancer. *Urology*. 2013;82:1197-1203.
32. Yao V, Berkman CE, Choi JK, O'Keefe DS, Bacich DJ. Expression of prostate-specific membrane antigen (PSMA), increases cell folate uptake and proliferation and suggests a novel role for PSMA in the uptake of the non-polyglutamated folate, folic acid. *Prostate*. 2010;70:305-316.
33. Cole BF, Baron JA, Sandler RS, et al. Folic acid for the prevention of colorectal adenomas: a randomized clinical trial. *JAMA*. 2007;297:2351-2359.
34. Figueiredo JC, Grau MV, Haile RW, et al. Folic acid and risk of prostate cancer: results from a randomized clinical trial. *J Natl Cancer Inst*. 2009;101:432-435.
35. Tisman G, Garcia A. Control of prostate cancer associated with withdrawal of a supplement containing folic acid, L-methyltetrahydrofolate and vitamin B12: a case report. *J Med Case Rep*. 2011;5:413.

36. Carver BS, Chapinski C, Wongvipat J, et al. Reciprocal feedback regulation of PI3K and androgen receptor signaling in PTEN-deficient prostate cancer. *Cancer Cell*. 2011;19:575-586.
37. Bacich D, Flores S, Pennetti S, et al. MP66-19 Prostate-Specific Membrane Antigen Interacts with Dietary Folate to Facilitate Prostate Carcinogenesis and Progression *J Urol*.195:e880.
38. Chang SS, O'Keefe DS, Bacich DJ, Reuter VE, Heston WD, Gaudin PB. Prostate-specific membrane antigen is produced in tumor-associated neovasculature. *Clin Cancer Res*. 1999;5:2674-2681.
39. Conway RE, Rojas C, Alt J, et al. Prostate-specific membrane antigen (PSMA)-mediated laminin proteolysis generates a pro-angiogenic peptide. *Angiogenesis*. 2016;19:487-500.
40. Schuster DM, Savir-Baruch B, Nieh PT, et al. Detection of recurrent prostate carcinoma with anti-1-amino-3-18F-fluorocyclobutane-1-carboxylic acid PET/CT and 111In-capromab pendetide SPECT/CT. *Radiology*. 2011;259:852-861.
41. Tagawa ST, Milowsky MI, Morris M, et al. Phase II study of Lutetium-177-labeled anti-prostate-specific membrane antigen monoclonal antibody J591 for metastatic castration-resistant prostate cancer. *Clin Cancer Res*. 2013;19:5182-5191.
42. Pandit-Taskar N, O'Donoghue JA, Ruan S, et al. First-in-Human Imaging with 89Zr-Df-IAB2M Anti-PSMA Minibody in Patients with Metastatic Prostate Cancer: Pharmacokinetics, Biodistribution, Dosimetry, and Lesion Uptake. *J Nucl Med*. 2016;57:1858-1864.
43. Freise AC, Wu AM. In vivo imaging with antibodies and engineered fragments. *Mol Immunol*. 2015;67:142-152.
44. Kopka K, Benešová M, Bařinka C, Haberkorn U, Babich J. Glu-Ureido-Based Inhibitors of Prostate-Specific Membrane Antigen: Lessons Learned During the Development of a Novel Class of Low-Molecular-Weight Theranostic Radiotracers. *J Nucl Med*. 2017;58:17S-26S.
45. Rowe SP, Gorin MA, Allaf ME, et al. PET imaging of prostate-specific membrane antigen in prostate cancer: current state of the art and future challenges. *Prostate Cancer Prostatic Dis*. 2016;19:223-230.
46. Szabo Z, Mena E, Rowe SP, et al. Initial Evaluation of [(18)F]DCFPyL for Prostate-Specific Membrane Antigen (PSMA)-Targeted PET Imaging of Prostate Cancer. *Mol Imaging Biol*. 2015;17:565-574.

47. Zechmann CM, Afshar-Oromieh A, Armor T, et al. Radiation dosimetry and first therapy results with a (124)I/ (131)I-labeled small molecule (MIP-1095) targeting PSMA for prostate cancer therapy. *Eur J Nucl Med Mol Imaging*. 2014;41:1280-1292.
48. Eiber M, Fendler WP, Rowe SP, et al. Prostate-Specific Membrane Antigen Ligands for Imaging and Therapy. *J Nucl Med*. 2017;58:67S-76S.
49. Fendler WP, Rahbar K, Herrmann K, Kratochwil C, Eiber M. 177Lu-PSMA Radioligand Therapy for Prostate Cancer. *J Nucl Med*. 2017;58:1196-1200.
50. Baum RP, Kulkarni HR, Schuchardt C, et al. 177Lu-Labeled Prostate-Specific Membrane Antigen Radioligand Therapy of Metastatic Castration-Resistant Prostate Cancer: Safety and Efficacy. *J Nucl Med*. 2016;57:1006-1013.
51. Kratochwil C, Bruchertseifer F, Rathke H, et al. Targeted Alpha Therapy of mCRPC with (225)Actinium-PSMA-617: Swimmer-Plot analysis suggests efficacy regarding duration of tumor-control. *J Nucl Med*. 2018.
52. Sathekge M, Knoesen O, Meckel M, Modiselle M, Vorster M, Marx S. (213)Bi-PSMA-617 targeted alpha-radionuclide therapy in metastatic castration-resistant prostate cancer. *Eur J Nucl Med Mol Imaging*. 2017;44:1099-1100.
53. Czernin J, Eiber M. Acceleration of PSMA-Targeted Theranostics to the Clinic: Can Common Sense Prevail? *J Nucl Med*. 2017;58:1186-1187.
54. Pandit-Taskar N, O'Donoghue JA, Divgi CR, et al. Indium 111-labeled J591 anti-PSMA antibody for vascular targeted imaging in progressive solid tumors. *EJNMMI Res*. 2015;5:28.
55. Gorin MA, Rowe SP, Hooper JE, et al. PSMA-Targeted 18F-DCFPyL PET/CT Imaging of Clear Cell Renal Cell Carcinoma: Results from a Rapid Autopsy. *Eur Urol*. 2017;71:145-146.
56. Vornov JJ, Hollinger KR, Jackson PF, et al. Still NAAG'ing After All These Years: The Continuing Pursuit of GCPII Inhibitors. *Adv Pharmacol*. 2016;76:215-255.
57. Rais R, Jiang W, Zhai H, et al. FOLH1/GCPII is elevated in IBD patients, and its inhibition ameliorates murine IBD abnormalities. *JCI Insight*. 2016;1.
58. Huang SS, Wang X, Zhang Y, Doke A, DiFilippo FP, Heston WD. Improving the biodistribution of PSMA-targeting tracers with a highly negatively charged linker. *Prostate*. 2014;74:702-713.
59. Willet Whitmore M.D. *New York Times*. May 9, 1995;Obituary.

60. William Fair M.D. *New York Times*. January 13, 2002;Obituary.

FIGURE LEGEND

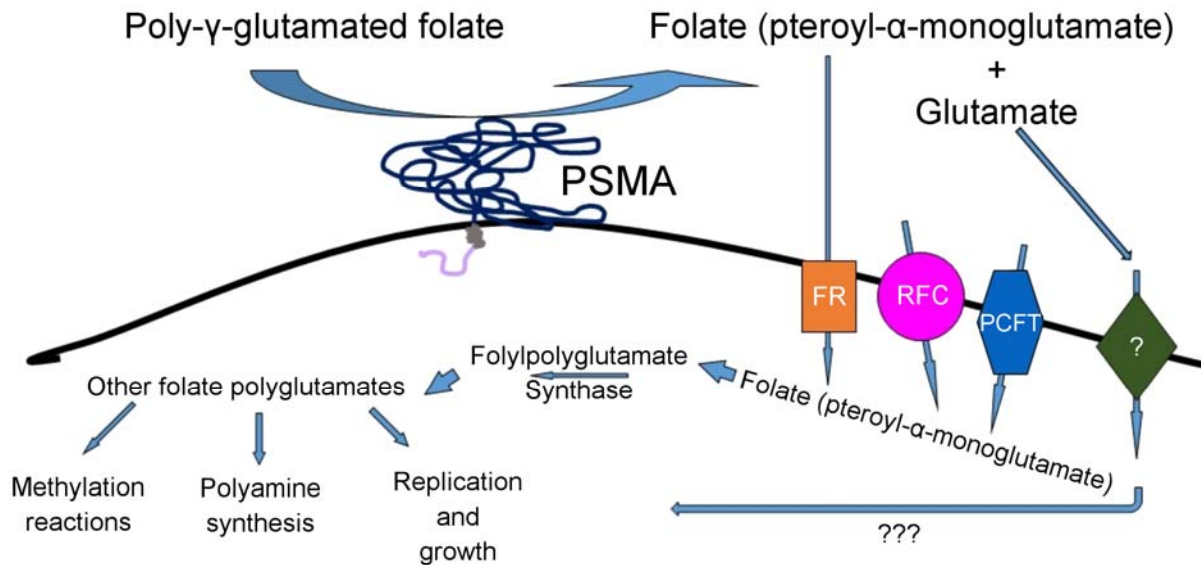


Figure 1. Proposed mechanism(s) by which PSMA contributes to tumor growth and progression. Poly-gamma-glutamated folates released from dead and dying tumor cells are hydrolyzed to folate by PSMA, and can now be taken up by nearby healthy tumor cells via the PCFT (proton coupled folate transporter), FR (folate receptor) or RFC (reduced folate carrier). Once inside the cell, folate is again polyglutamated and utilized for polyamine synthesis, methylation reactions and nucleotide synthesis required for cell proliferation. Free glutamate released by this reaction may be taken up by a glutamate receptor, stimulating proliferative growth pathways however the role of glutamate in the process, whether metabolic or signaling is still being clarified.