

## Effectiveness and Safety of $^{18}\text{F}$ -FDG PET in the Evaluation of Dementia: A Review of the Recent Literature

Nicolaas I. Bohnen<sup>1-3</sup>, David S.W. Djang<sup>4</sup>, Karl Herholz<sup>5</sup>, Yoshimi Anzai<sup>6,7</sup>, and Satoshi Minoshima<sup>6</sup>

<sup>1</sup>Department of Radiology, University of Michigan, Ann Arbor, Michigan; <sup>2</sup>Department of Neurology, University of Michigan, Ann Arbor, Michigan; <sup>3</sup>VAMC, Ann Arbor, Michigan; <sup>4</sup>Seattle Nuclear Medicine, Swedish Medical Center, Seattle, Washington; <sup>5</sup>Wolfson Molecular Imaging Centre, University of Manchester, Manchester, England; <sup>6</sup>Department of Radiology, University of Washington, Seattle, Washington; and <sup>7</sup>Health Service Research, University of Washington, Seattle, Washington

**Learning Objectives:** On successful completion of this activity, participants should be able to describe (1) the added diagnostic value of  $^{18}\text{F}$ -FDG PET in the assessment of dementia, compared with clinical assessment and follow-up alone; (2) the physiologic basis of cerebral glucose metabolism and its pathologic alterations in neurodegeneration; (3) recent literature reports of potential contributions of  $^{18}\text{F}$ -FDG PET in Alzheimer disease assessment; (4) the inclusion of biomarker evidence, including  $^{18}\text{F}$ -FDG PET, in new diagnostic criteria for Alzheimer disease; and (5) the impact of  $^{18}\text{F}$ -FDG PET on physician diagnostic confidence when assessing a patient with suspected dementia.

**Financial Disclosure:** The authors of this article have indicated no relevant relationships that could be perceived as a real or apparent conflict of interest.

**CME Credit:** SNM is accredited by the Accreditation Council for Continuing Medical Education (ACCME) to sponsor continuing education for physicians. SNM designates each JNM continuing education article for a maximum of 1.0 AMA PRA Category 1 Credit. Physicians should claim only credit commensurate with the extent of their participation in the activity.

For CE credit, participants can access this activity through the SNM Web site ([http://www.snm.org/ce\\_online](http://www.snm.org/ce_online)) through January 2013.

Imaging that can detect pathophysiologic change in the brain holds great promise for diagnostic assessment of patients with Alzheimer disease (AD) and dementia. Although a previous metaanalysis centering on literature from 1990 to 2000 showed a summary accuracy of 86% for  $^{18}\text{F}$ -FDG PET for AD diagnosis, the clinical value was considered uncertain because of methodologic shortcomings. Review of the recent literature since 2000 demonstrates that the evidence for  $^{18}\text{F}$ -FDG PET in assessment of dementia has increased with new studies that include autopsy confirmation, wide-diagnostic-spectrum recruitment in primary care settings, historical and prospective cohort studies, and multicenter data analyses. These data support the role of  $^{18}\text{F}$ -FDG PET as an effective and useful adjunct to other diagnostic information in the assessment of patients with symptoms of dementia. Findings are in line with recently revised diagnostic criteria of AD that for the first time recognize the unique role of biomarker evidence in disease definition.

**Key Words:** Alzheimer disease; diagnosis; dementia; fluorodeoxyglucose; PET; physician confidence; prognosis

**J Nucl Med 2012; 53:59–71**

DOI: 10.2967/jnumed.111.096578

**A**lzheimer disease (AD) is the most common form of dementia in the elderly and, in individuals over age 65 y, is the fourth leading cause of death, after heart disease, can-

cer, and stroke (1). AD accounts for 50%–60% of cases of dementia; dementia with Lewy bodies (DLB) and frontotemporal dementia (FTD) account for approximately 15%–25% of cases (2). AD is a progressive neurodegenerative disorder with an insidious onset and is characterized by a severe decline in episodic memory. Instrumental signs include aphasia, apraxia, and agnosia, together with general cognitive symptoms such as impaired judgment, decision making, and orientation (3).

### CLINICAL GUIDELINES FOR THE DIAGNOSIS OF AD AND DEMENTIA AND THE ROLE OF IMAGING

The definitive diagnosis of AD is based on the postmortem observation of specific pathologic lesions: intraneuronal deposits consisting of abnormally phosphorylated  $\tau$ -protein (neurofibrillary tangles), and amyloid- $\beta$  deposition in the form of extracellular aggregates (senile plaques). These hallmarks are associated with neuronal and synaptic losses and with atrophy in specific brain areas (4–6). Both amyloid deposits and neurofibrillary tangles are necessary for the postmortem diagnosis of AD (4).

Although there are various clinical criteria used in the diagnosis of dementia, there is no single reliable test. For example, the diagnosis of AD is frequently based on the National Institute of Neurologic and Communicative Disorders and Stroke–Alzheimer Disease and Related Disorders Association (NINCDS-ADRDA) criteria (3). The diagnosis is classified as definite (clinical diagnosis with histologic confirmation), probable (typical clinical syndrome without histologic confirmation), or possible (atypical clinical features but no alternative diagnosis apparent;

Received Aug. 27, 2011; revision accepted Nov. 3, 2011.

For correspondence or reprints contact: Nicolaas I. Bohnen, Department of Radiology, University of Michigan, B1G412 University Hospital, Ann Arbor, MI 48109-0028.

E-mail: [nbohen@umich.edu](mailto:nbohen@umich.edu)

Published online ■■■■.

COPYRIGHT © 2012 by the Society of Nuclear Medicine, Inc.

no histologic confirmation). Clinical diagnostic schemata are available from the American Academy of Neurology (AAN). The AAN reported practice parameter guidelines for the clinical evaluation of dementia in 2001 (7). There was a consensus that the DSM-III-R definition for dementia (8) was reliable and that the NINCDS-ADRDA criteria for AD have sufficient reliability and validity and both should be used routinely in clinical practice (7).

Definite diagnosis of AD and other types of dementia requires pathologic confirmation. There are many studies, including 3 diagnostic studies with an AAN class I level of evidence, that have addressed the diagnostic accuracy of the clinical diagnosis of AD using neuropathologic confirmation as the gold standard (7). Both the DSM-III-R "Dementia of the Alzheimer type" (8) and the NINCDS-ADRDA "probable" AD definitions (3) achieved either good sensitivity (average across cited studies, 81%; range, 49%–100%) for AD at the expense of specificity (average across cited studies, 70%; range, 47%–100%) or vice-versa in most of the cited studies. A diagnosis of "possible" AD achieved high sensitivity (average across 4 studies, 93%; range, 85%–96%) but at the price of specificity (average across 4 studies, 48%; range, 32%–61%) (9–12), reflecting the many features that non-AD dementias share with AD.

Physician confidence in a dementia diagnosis can be challenging in the early stage of disease, in younger patients, in atypical presentations, in patients with comorbid depressive and cognitive symptoms, and in patients with a high level of education, who can experience a substantial decline of cognitive function before reaching the lower normal limits of standardized neuropsychological tests (13,14). Therefore, imaging that can detect functional or pathophysiologic changes in the brain holds great promise for diagnostic assessment of patients with AD (15). More accurate assessment of dementia diagnosis can help to better select appropriate patients for antidementia therapy and family prognostic planning (16). Furthermore, there is a strong physician need not only for a disease confirmatory test but also for an exclusionary test, in which a normal test result can help to provide patient reassurance (17). In vivo brain  $^{18}\text{F}$ -FDG PET is a minimally invasive diagnostic imaging procedure used to evaluate cerebral glucose metabolism. One of the striking features of AD is the drastic reduction of glucose metabolic activity in specific brain regions as determined by  $^{18}\text{F}$ -FDG PET (18). Cerebral glucose metabolic activity is an index of synaptic function and density (19,20). Cerebral glucose hypometabolism is a characteristic feature of neurodegeneration. The clinical test involves the qualitative visual interpretation of the scan images, on which metabolically active areas are indicated by greater degrees of  $^{18}\text{F}$ -FDG activity. Patients with AD have predominant reductions in temporoparietal regions, including the precuneus, with additional reductions in the adjacent posterior cingulate cortex and the frontal cortex (21–25), whereas other dementias may have a range of different metabolic patterns (16). The posterior cingulate

cortex and the neighboring precuneus are metabolically affected in the earliest clinical and preclinical stages of AD, and the primary visual cortex is relatively spared (26,27). Moreover, the cerebellum, thalamus, and basal ganglia nuclei are spared from significant reductions in glucose metabolism in AD. Therefore, it is the complete regional pattern of metabolic impairment of the posterior cingulate and temporoparietal cortices, more accentuated than frontal cortex deficits, together with the relative preservation of the primary sensorimotor and visual cortices, basal ganglia, and cerebellum that defines the distinct metabolic phenotype of AD (21,28).

With regard to brain imaging, the 2001 AAN guidelines suggest at least 1 structural brain scan with either unenhanced CT or MRI in the initial evaluation of dementia to assess possible structural causes, which might include normal-pressure hydrocephalus, strokes, silent brain infarcts, neoplasms, and intracranial hemorrhage (7). However, the 2001 AAN recommendations did not endorse functional neuroimaging in the initial evaluation of dementia. At that time, data were insufficient to argue that functional imaging techniques such as SPECT perfusion or  $^{18}\text{F}$ -FDG PET were adequately developed to aid in the accurate or differential diagnosis of dementia or to consistently distinguish among various types of dementia. There were few large prospective studies of  $^{18}\text{F}$ -FDG PET available at the time of review to argue for its routine use in the initial evaluation of dementia. Subsequent to 2001, more prospective studies have been reported with both SPECT and PET in the evaluation of dementia (29). Although SPECT has been more broadly available, studies show PET has a higher diagnostic accuracy by approximately 15%–20%, suggesting that PET may be more beneficial in the early detection of neurodegenerative diseases (30). In fact, PET is superior to SPECT in its ability to separate healthy controls from patients with true dementing illnesses (31).

## OBJECTIVES OF THIS REVIEW

Previous reviews of the diagnostic utility of  $^{18}\text{F}$ -FDG PET in the clinical evaluation of dementia, in particular AD, were based on older literature, mainly from 1990 to 2000, when PET was an emerging technology and only a limited number of high-quality studies were available (32,33). Although a metaanalysis of the literature during this period found  $^{18}\text{F}$ -FDG PET to have a summary sensitivity of 86% and a summary specificity of 86% for AD diagnosis, several methodologic shortcomings in the early literature because of limitations in study design and patient characteristics were identified (33). Consequently, a set of quality criteria to guide future studies in this field were suggested (33).

The primary objective of this article is to review new literature published since 2000 to determine the effectiveness and safety of  $^{18}\text{F}$ -FDG PET in the assessment of dementia, in particular suspected AD. Furthermore, the new literature reports were selected and assessed on the basis of

additional quality criteria, including studies using dementia diagnosis based on postmortem verification, studies using dementia diagnosis based on longitudinal clinical follow-up, studies with <sup>18</sup>F-FDG classification based on the visual assessment of scans, and studies with a spectrum of AD severity and also including common non-AD dementia syndromes. Studies with both traditional visual assessments of <sup>18</sup>F-FDG PET images and surface-rendered statistical maps based on reference data from healthy control subjects were included for review, as such studies have become part of current clinical practice. Studies that did not include visual review of images and were based on only automated quantitative parameters were not included in the review and were considered investigational.

Details of the review process are listed in the supplemental data (supplemental materials are available online only at <http://jnm.snmjournals.org>). Through the selection process, a total number of 11 eligible studies were identified. These included 4 studies using postmortem diagnosis as a gold standard to determine the diagnostic accuracy of <sup>18</sup>F-FDG PET in AD, 2 studies using longitudinal clinical assessment of at least 1 y as an acceptable gold standard to determine the diagnostic accuracy of <sup>18</sup>F-FDG PET in AD, 2 large multicenter studies, 2 studies from a predominant primary care setting, 8 studies using a comparison group that included subjects with other types of dementia or cognitive complaints, and 3 studies that reported subgroup analyses based on severity of dementia. A tabulated summary of the 11 studies, including detailed-review quality scores and assigned AAN level of diagnostic evidence, is available in Supplemental Table 1. Studies will be discussed below according to increasing AAN level of diagnostic evidence.

#### **<sup>18</sup>F-FDG PET CROSS-SECTIONAL CASE-CONTROL STUDIES USING CLINICAL ASSESSMENT AS DIAGNOSTIC REFERENCE STANDARD**

**[Table 1]** Five of the eligible 11 papers were case-control studies using clinical assessment as the reference standard. Table 1 represents the individual and pooled diagnostic performance of <sup>18</sup>F-FDG PET in these studies. The pooled di-

agnostic summary of cross-sectional case-control <sup>18</sup>F-FDG PET studies revealed an overall diagnostic accuracy of 93% for differentiating AD subjects from healthy subjects, with sensitivity of 96% and specificity of 90% (all 5 studies met AAN level III diagnostic evidence). The prior metaanalysis conducted by Patwardhan et al. showed <sup>18</sup>F-FDG PET to have a summary sensitivity of 86% and a summary specificity of 86% for AD diagnosis (33). The current pooled analysis (references published since 2000) shows comparable or better values, validating the analysis. The better sensitivity in the literature published since 2000 could be attributable to several factors including differences in subjects studied, the use of improved PET devices, or improved interpretational skills of observers.

#### **<sup>18</sup>F-FDG PET STUDIES USING LONGITUDINAL CLINICAL FOLLOW-UP ASSESSMENT AS DIAGNOSTIC REFERENCE STANDARD**

Two studies provided <sup>18</sup>F-FDG PET information on the diagnosis of AD and dementia using longitudinal clinical follow-up assessment as the reference standard (Table 2). Although no formal description of patient recruitment was provided, one study appeared to consecutively recruit its sample from a primary care center (34). In this study, 24 patients with initial clinical suspicion of mild dementia, 12 of them with mild cognitive impairment, underwent <sup>18</sup>F-FDG PET at baseline, and the final diagnosis was based on variable longitudinal clinical follow-up (average of 16 ± 12 mo). The final diagnosis included 9 patients with pure AD, 7 with mixed AD and vascular-type dementia, 6 without dementia, and the remainder with FTD or pure vascular dementia. This study reported an <sup>18</sup>F-FDG PET diagnostic sensitivity of 44% for the diagnosis of purely defined AD, with a specificity of 83%, whereas the sensitivity of <sup>18</sup>F-FDG PET for mixed AD and vascular diagnosis dementia was 71%, with a specificity of 78%. However, the sensitivity of <sup>18</sup>F-FDG PET in the diagnosis of AD or mixed AD and vascular dementia versus absence of dementia was 91.7%, with a specificity of 88.9% (34). Using <sup>18</sup>F-FDG PET, progressive dementia was excluded in all 6 patients who did not develop dementia during the follow-up period.

**TABLE 1**  
<sup>18</sup>F-FDG PET Diagnosis of AD in Cross-Sectional Case-Control Studies

Reference	Cohort A	Cohort B	TP	FN	FP	TN	Sensitivity	Specificity	Accuracy
Mosconi et al., 2007 (88)	AD	Healthy control	33	0	0	19	100%	100%	100%
Ng et al., 2007 (94)	AD	Healthy control	12	3	10	15	80%	60%	68%
Chen et al., 2008 (95)	AD	Healthy control	47	5	9	51	90%	85%	88%
Mosconi et al., 2008 (52)	AD	Healthy control	192	2	2	108	99%	98%	99%
McMurtray et al., 2008 (90)	AD	Elderly control with only subjective memory complaints	25	2	4	23	93%	85%	89%
		Total	309	12	25	216	96%	90%	93%

FN = false-negative; FP = false-positive; TN = true-negative; TP = true-positive.

**TABLE 2**  
Cohort Studies with Clinical Diagnosis of AD Based on Longitudinal Assessment

Reference and AAN level	Diagnostic standard and study type	Subjects	Major findings
Dobert et al., 2005 (34), AAN level II	Longitudinal clinical diagnosis; prospective cohort study in primary care-like setting	Twenty-four patients with initial clinical suspicion of beginning dementia, 12 of whom had mild cognitive impairment, underwent <sup>18</sup> F-FDG PET at baseline. Final diagnosis was based on variable longitudinal clinical follow-up (average, 16 ± 12 mo) and included 9 patients with pure AD, 7 with mixed AD and vascular-type dementia, 6 without dementia, and remainder with FTD or pure vascular dementia.	For diagnosis of more purely defined AD, <sup>18</sup> F-FDG PET had sensitivity of 44% and specificity of 83%. For diagnosis of mixed AD and vascular dementia, <sup>18</sup> F-FDG PET had sensitivity of 71% and specificity of 78%. For diagnosis of AD and mixed vascular/AD dementia vs. absence of dementia, <sup>18</sup> F-FDG PET had sensitivity of 91.7% and specificity of 88.9%.
Panegyres et al., 2009 (35), AAN level I	Longitudinal clinical diagnosis with average clinical follow-up of 5–6 y; prospective cohort study of <sup>18</sup> F-FDG PET diagnostic utility in primary care setting	Community-dwelling subjects presented to primary care center for cognitive complaints. Final clinical diagnosis was early-stage AD ( <i>n</i> = 49), non-AD dementia ( <i>n</i> = 29), depression ( <i>n</i> = 11), or miscellaneous ( <i>n</i> = 13).	For diagnosis of AD, <sup>18</sup> F-FDG PET had sensitivity of 78% and specificity of 81% in this heterogeneous population. For differential diagnosis of other dementias, including FTD, <sup>18</sup> F-FDG PET had specificity > 95%.

Panegyres et al. reported a prospective study of 102 individuals presenting consecutively to a primary care center for examination of suspected early-onset dementia (35). Patients were evaluated using standard clinical criteria for the diagnosis of dementia. Functional neuroimaging data were obtained, and nuclear medicine physicians who were not aware of the clinical diagnosis generated <sup>18</sup>F-FDG PET diagnoses. Final clinical diagnoses based on all available data were then established and compared against PET diagnoses. Forty-nine patients received a final clinical diagnosis of early-stage AD (Mini-Mental State Examination score, 21 ± 5). There were 31 non-AD demented patients, 11 depressed patients, and a miscellaneous group of 11 nonprogressive or nondemented patients. Among patients with AD, the sensitivity and specificity of <sup>18</sup>F-FDG PET were 78% (95% confidence interval [CI], 66%–90%) and 81% (95% CI, 68%–86%), respectively. The positive likelihood ratio for a <sup>18</sup>F-FDG PET scan positive for the diagnosis of AD was 4.11 (95% CI, 2.29–7.32), and the negative likelihood ratio for a negative <sup>18</sup>F-FDG PET scan in the absence of AD was 0.27 (95% CI, 0.16–0.46). The pretest AD probability was 48%, and the posttest probability was 79%. The specificity of <sup>18</sup>F-FDG PET in the differential diagnosis of other dementias, including FTD, was greater than 95%.

**<sup>18</sup>F-FDG PET STUDIES OF AD AND DEMENTIA USING PATHOLOGIC CONFIRMATION AS THE REFERENCE STANDARD**

Most existing studies compared <sup>18</sup>F-FDG PET to a clinical diagnosis, which may be inaccurate and therefore is not

an ideal diagnostic gold standard (7,36–38). In addition, the use of clinical diagnosis as a criterion does not permit a comparison of the relative accuracies of <sup>18</sup>F-FDG PET diagnosis versus clinical diagnosis to the gold standard neuropathologic diagnosis (39). However, several studies have compared the accuracy of <sup>18</sup>F-FDG PET with the accuracy of clinical and neuropathologic diagnosis in dementia patients (Table 3) (16,39–43). Some of the smaller previous *in vivo* PET–postmortem pathology correlation studies were not included in the present analysis, as subjects in these earlier studies were included in subsequent larger-scale studies that are included here (e.g., subjects in the Hoffman et al. study (40) were again reported in the Silverman et al. study (42); and subjects of the Albin et al. study (44) were included subsequently in the larger study of Minoshima et al. (41)).

In the largest series to date, Silverman et al. reported evaluation of <sup>18</sup>F-FDG PET for diagnosis of AD versus other causes of dementia (42). This study reported on 2 populations: a prospective cohort with long-term clinical follow-up and a retrospective cohort with a histopathologic reference standard. The retrospective cohort study was a multicenter study from an international consortium of clinical facilities that had collected both brain <sup>18</sup>F-FDG PET and histopathologic data for patients undergoing evaluation for dementia. Among 97 patients with a histopathologic AD diagnosis, the sensitivity of <sup>18</sup>F-FDG PET for diagnosing AD was 94% (95% CI, 89%–99%) and the specificity among 41 patients without AD was 73% (95% CI, 60%–87%). This study included a stratified examination of the subset of patients with

**TABLE 3**  
Cohort Studies with Postmortem Diagnosis

Reference and AAN level	Diagnostic standard	Study type	Subjects	Major findings
Silverman et al., 2001 (42), AAN level II	Autopsy confirmation and clinical follow-up	Multicenter retrospective analysis based on postmortem diagnosis	AD ( $n = 97$ ); non-AD ( $n = 41$ ), such as progressive supranuclear palsy, Parkinson disease, cerebrovascular disease, or mixed	AD was identified in 85/89 (sensitivity, 96%) AD-only cases and 6/8 AD-plus cases (overall sensitivity, 94%). Absence of AD was confirmed in 30/41 cases (specificity, 73%), including 23 with other neurodegenerative dementias. Absence of neurodegenerative disease was confirmed in 14/18 cases (specificity, 78%). Negative PET scan indicated that pathologic progression of cognitive impairment during mean 3-y follow-up was unlikely.
Jagust et al., 2007 (39), AAN level II	Autopsy confirmation	Retrospective study with 4-y clinical follow-up and 5 y until death and autopsy	Forty-four subjects with dementia, cognitive impairment, or normal cognitive functions; postmortem diagnosis included AD ( $n = 20$ ), FTD, DLB, mixed, and vascular dementia	For diagnosing AD, accuracy of $^{18}\text{F}$ -FDG PET (sensitivity, 84%; specificity, 74%) was better than that of initial clinical evaluation (sensitivity, 76%; specificity, 58%). $^{18}\text{F}$ -FDG PET (78%) also had better NPV than did initial clinical evaluation (65%).
Minoshima et al., 2001 (41), AAN level II	Autopsy confirmation and clinical follow-up	Retrospective $^{18}\text{F}$ -FDG PET analysis based on postmortem diagnosis, and retrospective $^{18}\text{F}$ -FDG PET diagnosis based on clinical follow-up	AD ( $n = 10$ ); autopsy-confirmed DLB ( $n = 11$ ); additional 53 patients with clinically probable diagnosis of AD ( $n = 40$ ) or DLB ( $n = 13$ ) based on follow-up evaluation	$^{18}\text{F}$ -FDG PET can distinguish AD from DLB with 90% sensitivity and 80% specificity.
Foster et al., 2007 (16), AAN level II	Autopsy confirmation	Retrospective consensus study of 6 dementia experts reviewing clinical history and $^{18}\text{F}$ -FDG PET studies	AD ( $n = 31$ ); FTD ( $n = 14$ ); controls ( $n = 33$ )	$^{18}\text{F}$ -FDG PET is significantly more accurate in distinguishing FTD from AD than clinical methods. $^{18}\text{F}$ -FDG PET adds important information that appropriately increases diagnostic confidence, even among experienced dementia specialists. Mean interrater $\kappa$ was 0.31–0.42 for clinical information and 0.73–0.78 for $^{18}\text{F}$ -FDG PET. For AD diagnosis compared with FTD, sensitivity was 96.7% and specificity was 85.7%.

mild disease at the time of PET for whom performance of  $^{18}\text{F}$ -FDG PET with respect to sensitivity (95%), specificity (71%), and overall diagnostic accuracy (89%) was nearly the same as for the entire group (42).

Jagust et al. reported results of a single-center historical cohort study of a mixed sample of 44 subjects with variable levels of cognitive impairment who underwent initial clinical examination and  $^{18}\text{F}$ -FDG PET and had approximately 4 y until the final clinical diagnosis and an additional average of 5 y until death and autopsy (39). Results showed that the sensitivity of the initial clinical evaluation for the pathologic diagnosis of AD was 76%, and specificity was 58%; PET had values of 84% and 74%, respectively, and final clinical evaluation had values of 88% and 63%, respectively. Positive predictive values for initial clinical evaluation, PET, and final clinical evaluation were 70%, 81%, and 76%. Negative predictive values were 65%, 78%, and 80%. Results were similar in a subgroup analysis limited to subjects with less severe cognitive impairment at entry. The diagnosis of AD was associated with a 70% probability of detecting AD pathology; with a positive PET scan this increased to 84%, and with a negative PET scan this decreased to 31%. A diagnosis of "not AD" at initial clinical evaluation was associated with a 35% probability of AD pathology, increasing to 70% with a positive PET scan. The probability of a postmortem diagnosis of AD for an initial normal cognitive assessment and negative  $^{18}\text{F}$ -FDG PET findings was 17%. Overall, these results indicate that diagnostic sensitivity and specificity available with  $^{18}\text{F}$ -FDG PET at an initial clinical evaluation are similar to longitudinal clinical diagnosis over approximately 4 y (39). Furthermore, the addition of  $^{18}\text{F}$ -FDG PET to clinical diagnosis at initial clinical evaluation had a substantial effect on the likelihood of finding AD pathology at postmortem examination and was particularly important when PET disagreed with the clinical diagnosis. For example, a positive  $^{18}\text{F}$ -FDG PET scan increased the likelihood of AD pathology by 14% if the clinical diagnosis was AD but by 35% if the clinical diagnosis was not AD. Conversely, a negative PET scan decreased the diagnosis by 18% if the clinical diagnosis was not AD but by 39% if the diagnosis was AD. In both situations when  $^{18}\text{F}$ -FDG PET disagreed with the clinical diagnosis, the correct pathologic diagnosis was in fact more likely to be congruent with  $^{18}\text{F}$ -FDG PET than with the initial clinical diagnosis. The data reported here agree with the 2 largest previously reported studies in demonstrating that PET sensitivity is superior to specificity (40,42).

#### **$^{18}\text{F}$ -FDG PET DIFFERENTIAL DIAGNOSIS OF AD VERSUS OTHER DEMENTIAS**

Although most functional neuroimaging research has focused on identifying AD, the sensitivity and specificity of PET in diagnosing other dementia conditions has also been investigated. Specific patterns of  $^{18}\text{F}$ -FDG hypometabolism are now identified in association with the most

common neurodegenerative dementia (Fig. 1) as discussed [Fig. 1] below.

#### **AD Versus DLB**

DLB is the second most frequent type of dementia and appears to represent a clinical phenotypic subtype of patients who have marked neuropsychiatric disturbances (such as prominent visual hallucinations or depression), variability in arousal and attention antedating or shortly after the onset of spontaneous and more variable extrapyramidal motor symptoms (45). Consistent observation of a metabolic reduction in the medial occipital cortex in DLB suggests the use of functional brain imaging as a potential clinical diagnostic aid to differentiate DLB from AD (41). Minoshima et al. found that the presence of occipital hypometabolism distinguished DLB from AD with 90% sensitivity and 80% specificity in a study using a postmortem diagnostic validation (41). Minoshima et al. found that the sensitivity in discriminating DLB and AD using  $^{18}\text{F}$ -FDG PET was greater than that with clinical diagnostic criteria applied retrospectively to the data from medical charts (41,46). The sensitivity was also greater than a carefully designed prospective clinicopathologic correlation study (47), but direct comparison is difficult because of the different populations of patients in these studies.

#### **AD Versus FTD**

FTD, especially the behaviorally variant, is characterized clinically by prominent initial changes in personality and behavior, such as apathy or disinhibition, whereas memory impairment may be less conspicuous (48). Some patients may present with more prominent language changes, such as a progressive fluent aphasia (which can be seen with semantic dementia and more prominent temporal lobe atrophy) (49). FTD is readily identified on  $^{18}\text{F}$ -FDG PET scans by distinct frontal or frontotemporal metabolic impairments that typically are quite asymmetrically centered in the frontolateral cortex and the anterior pole of the temporal lobe, from where they may extend to other association areas (50,51). Results of a historical cohort study with postmortem validation showed that  $^{18}\text{F}$ -FDG PET was more accurate than clinical judgment in predicting histopathologic diagnosis in patients with AD and FTD (16).

Panegyres et al. reported a specificity of greater than 95% for  $^{18}\text{F}$ -FDG PET in the differential diagnosis of other dementias, including FTD, DLB, and primary progressive aphasia, in a prospective cohort study of 102 individuals presenting consecutively to a primary care center for examination of suspected early-onset dementing diseases (35). The high specificity of  $^{18}\text{F}$ -FDG PET in AD, FTD, and DLB implies that negative or normal scan findings, in the presence of the suspicion of dementia, make a dementia diagnosis unlikely.

Table 4 summarizes the differential diagnostic performance for classification of AD versus other types of neurodegenerative dementia. Although dementia subjects and

control subjects included in individual studies were somewhat heterogeneous, pooled diagnostic performance provides values that can be compared with other studies.

### LARGE MULTICENTER STUDIES

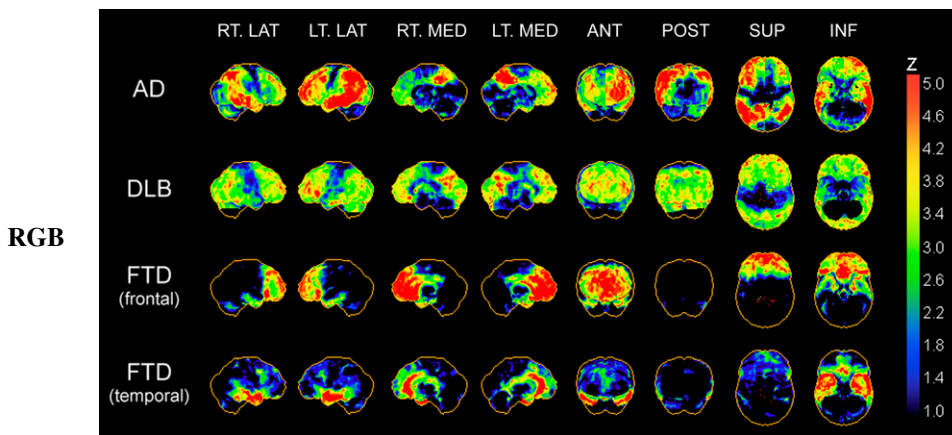
Mosconi et al., in a large multicenter study, examined  $^{18}\text{F}$ -FDG PET measures in the differentiation of AD, FTD, and DLB from normal aging and from each other (total subjects,  $n = 548$ ) (52). Patients were classified according to established clinical criteria, and quantitative and computer-aided visual assessment was used. Overall, disease-specific PET patterns yielded 96% accuracy in discriminating among healthy, AD, DLB, and FTD subjects in the testing cohort, with 94% healthy, 95% AD, 92% DLB, and 94% FTD subjects correctly classified in an independent group of patients (52). There was no difference in the proportion of mild versus moderate-to-severe dementia patients correctly classified by clinical group. This study demonstrated the feasibility of using  $^{18}\text{F}$ -FDG PET in the differential diagnosis of the major neurodegenerative disorders, including mild dementia, across multiple sites. Across centers, as compared with cognitively normal subjects, most AD patients showed a characteristic profile of hypometabolism in the parietotemporal and posterior cingulate cortices and, more variably, frontal regions, and in the hippocampus. In comparison with AD, DLB patients showed more prominent hypometabolism in the occipital cortices, and FTD patients showed more prominent hypometabolism in the frontal or temporal cortices, consistent with previous reports (41,44,53–55). However, 29% of DLB patients and 35% of FTD patients showed a pattern of cortical deficits similar to that of AD patients. Therefore, the presence of cortical abnormalities discriminated AD from DLB and FTD with a high sensitivity (>90%) though a lower specificity (71% and 65%, respectively). The large multicenter study by Silverman et al. (42) has been discussed above.

### PHYSICIAN CONFIDENCE LEVEL AND PREDICTIVE VALUE OF $^{18}\text{F}$ -FDG PET

The treating physician's confidence in a dementia diagnosis can be challenging, especially when symptoms are subtle or arise at a younger age (13,14). A recent historical cohort study examined the role of  $^{18}\text{F}$ -FDG PET in the diagnosis of atypical or unclear dementias in a memory clinic setting (56). A total of 94 patients with a diagnosis of mild cognitive impairment or dementia who had a PET study within 2 mo of their diagnosis were reevaluated at 5 and 18 mo. The results showed that PET was associated with a change in diagnosis in 29% of patients. Specifically, PET significantly lowered the number of unclear diagnoses from 39% to 16%, and nearly 30% of these were found to have a typical AD pattern of hypometabolism (56). This study also addressed the clinicians' impression of the contribution of  $^{18}\text{F}$ -FDG PET in the diagnostic process. The results showed that, overall,  $^{18}\text{F}$ -FDG PET helped, clarified, and oriented the diagnosis in 56% of cases; confirmed clinical impression in 16% of cases; and had no impact in 28% of cases. This study provides guiding evidence about the true value of  $^{18}\text{F}$ -FDG PET in the day-to-day challenge of dementia diagnosis.

Treating physicians have a strong need not only for a disease-confirmatory test but also for an exclusionary test, especially in the clinical setting of atypical presentations and only subjective memory complaints. In this respect, a normal  $^{18}\text{F}$ -FDG PET result helps to provide assurance that cognitive abilities are likely to remain stable for several years after the study (17).

The accuracy of PET diagnosis is frequently discussed only in terms of sensitivity and specificity. Sensitivity refers to the probability of a positive test among patients with disease, whereas specificity refers to the probability of a negative test among patients without disease. Ideally, one would like to know what the probability of disease is, given a positive or negative test. For this purpose, likelihood



**FIGURE 1.** Typical regional cerebral  $^{18}\text{F}$ -FDG hypometabolism patterns in AD, DLB, and frontal and temporal FTD. Patterns are presented as z score maps based on significantly hypometabolic voxels relative to nondemented comparison population. AD pattern of glucose hypometabolism involves predominantly temporoparietal association cortices and posterior cingulate and precuneus cortices. In advanced disease, prefrontal association cortices show additional hypometabolism. Primary sensorimotor and visual neocortices are relatively spared. DLB has cortical hypometabolism similar to that of AD but with additional involvement of occipital cortex. FTD demonstrates frontal lobar or frontal and temporal polar cortical

hypometabolism with relative sparing of parietal association cortex and preservation of primary somatomotor and visual cortices. ANT = anterior; INF = inferior; LAT = lateral; MED = medial; POST = posterior; SUP = superior.

**TABLE 4**  
Differential Diagnosis of AD vs. Other Dementias

Reference and AAN level	Cohort A	Cohort B	TP	FN	FP	TN	Sensitivity	Specificity	Accuracy
Silverman et al., 2001 (42), AAN level II	AD	Non-AD/nondementia	91	11	6	30	89%	83%	88%
Minoshima et al., 2001 (41), AAN level II	AD	DLB	9	1	2	9	90%	82%	86%
Foster et al., 2007 (16), AAN level II	AD	FTD	30	1	2	12	97%	86%	93%
Jagust et al., 2007 (39), AAN level II	AD and mixed	Non-AD	21	4	5	14	84%	74%	80%
Panegyres et al., 2009 (35), AAN level I	AD	Non-AD	38	11	10	43	78%	81%	79%
		Total	189	28	25	108	87%	81%	85%

FN = false-negative; FP = false-positive; TN = true-negative; TP = true-positive.

ratios can be calculated to assess the a posteriori likelihood of disease. The positive likelihood ratio indicates the increase in probability of disease after a positive test result, whereas the negative likelihood ratio represents the reduction in probability of disease after a negative test result. Likelihood ratio is the probability that a given test result would be expected in a patient with the target disorder divided by the probability that the same result would be expected in a patient without the disorder. A positive likelihood ratio greater than 1 produces a posttest probability that is higher than the pretest probability. A very low negative likelihood ratio (e.g., <0.1) virtually rules out the chance that the patient has the disease.

**[Table 5]** Table 5 lists studies that reported likelihood ratios for <sup>18</sup>F-FDG PET and AD diagnosis. These data indicate that a negative (i.e., normal) <sup>18</sup>F-FDG PET result strongly favors a normal (nonprogressive) outcome at follow-up over several years.

Foster et al. studied the effect of adding <sup>18</sup>F-FDG PET to clinical diagnostic information on diagnostic accuracy and physician's confidence in the diagnosis of AD versus FTD (16). Diagnostic confidence appears to be a meaningful measure, because it appropriately reflects raters' true diagnostic accuracy. Using a dedicated assessment scale ranging from unsure to somewhat confident to very confident, these investigators found that clinical raters often had limited confidence in their clinical diagnosis. However, adding <sup>18</sup>F-FDG PET increased not only the diagnostic accuracy but also the treating physician's level of confidence in making the diagnosis of AD or FTD.

#### COMPUTER-ASSISTED QUANTITATIVE INTERPRETATION OF BRAIN <sup>18</sup>F-FDG PET

Similar to other imaging modalities, accurate diagnostic interpretation of brain <sup>18</sup>F-FDG PET scans depends on the interpreting observer's experience and skill. However, given the presently limited clinical use of brain <sup>18</sup>F-FDG PET scans, not all radiologists and nuclear medicine specialists are familiar with brain <sup>18</sup>F-FDG PET interpretation. The reliance on qualitative interpretation by visual reading is admittedly one issue in the clinical application of brain <sup>18</sup>F-FDG PET (51). Visual ratings depend heavily on the

observer's prior experience and training, and <sup>18</sup>F-FDG PET measurements often lack clearly defined cutoffs to distinguish between normal and pathologic findings. Several automated tools are used in neuroimaging studies to examine and sample brain regions (57). Foremost, voxel-based analysis techniques with statistical parametric mapping procedures can provide unbiased statistically defined measures of abnormality throughout the whole brain on a voxel-by-voxel basis. This technique was initially developed for functional brain mapping research applications (58,59) but subsequently was applied to clinical interpretations of individual cases of dementia and other neurologic disorders (58,59). The basic procedure in voxel-based analysis involves the spatial normalization and smoothing of each individual's PET scan to an anatomically defined standard brain reference volume (the template or atlas volume) in the stereotactic space. This enables voxel-by-voxel statistical comparison of the <sup>18</sup>F-FDG pattern in the individual brain against the mean and SD of a control population (58,59). Objective image analysis procedures can be easily applied and shared across different imaging centers (51). These procedures result in an observer-independent, quantitative mapping of regional glucose metabolic abnormalities (58,60). Currently, some of the computer-assisted methods for brain <sup>18</sup>F-FDG PET interpretations are Food and Drug Administration 510(k)-approved and are commercially distributed. This type of secondary analysis provides a tool for physicians to achieve an objective and accurate diagnosis of dementia and an accurate interpretation of potential scan abnormalities, as well as an educational opportunity to improve their scan interpretation skills.

#### PATHOPHYSIOLOGY OF <sup>18</sup>F-FDG METABOLISM AND INVESTIGATIONAL STUDIES

Mosconi et al. presented results of longitudinal clinical and <sup>18</sup>F-FDG PET assessments in a case series of 7 subjects who has postmortem diagnostic validation and whose <sup>18</sup>F-FDG PET profiles in life were consistent with the postmortem diagnosis (43). Four subjects from a university aging study were initially classified as cognitively normal, but 2 had subsequent development of mild cognitive impairment and 2 of AD. Three subjects diagnosed as AD initially were



**TABLE 5**  
<sup>18</sup>F-FDG PET and AD Diagnostic Studies Reporting Likelihood Ratios

Reference and study type	Diagnostic standard	Subjects	Likelihood ratios
Panegyres et al. 2009 (35), prospective cohort study of diagnostic utility of <sup>18</sup> F-FDG PET	Clinical diagnosis based on longitudinal long-term assessment	Community-dwelling subjects presented to primary care center for cognitive complaints. Final clinical diagnosis was early-stage AD ( <i>n</i> = 49), non-AD dementia ( <i>n</i> = 29), depression ( <i>n</i> = 11), or miscellaneous ( <i>n</i> = 13).	Positive likelihood ratio for <sup>18</sup> F-FDG PET scan considered consistent with AD was 4.11 (95% CI, 2.29–7.32), suggesting increase in likelihood of final diagnosis of AD when diagnosed on <sup>18</sup> F-FDG PET with AD. Negative likelihood ratio for AD was 0.27 (95% CI, 0.16–0.46), suggesting more significant decrease in likelihood of final diagnosis of AD when <sup>18</sup> F-FDG PET findings are negative for AD. Probability before <sup>18</sup> F-FDG PET that patient had AD was 48%. After <sup>18</sup> F-FDG PET, probability increased to 79%, indicating that <sup>18</sup> F-FDG PET increases diagnosis probability of early-onset AD from 48% to 79%.
Jagust et al., 2007 (39), historical cohort study	Postmortem diagnosis	Forty-four individuals with dementia, cognitive impairment, or normal cognitive function underwent clinical initial evaluation and PET and were followed up for approximately 4 y until final evaluation and 5 y until death and autopsy. Clinical, pathologic, and imaging diagnoses were categorized as AD or not AD.	Positive likelihood ratio of <sup>18</sup> F-FDG PET for AD diagnosis was 3.2, and negative likelihood ratio was 0.21.
Silverman et al., 2001 (42), multicenter retrospective analysis	Postmortem diagnosis	Multicenter retrospective analysis was performed on heterogeneous patient population.	Positive likelihood ratio of <sup>18</sup> F-FDG PET for AD diagnosis was 3.5, and negative likelihood ratio was 0.08. Positive likelihood ratio of <sup>18</sup> F-FDG PET for presence of neurodegenerative disease of any kind was 4.2, and negative likelihood ratio was 0.075.

also followed longitudinally till autopsy verification. Longitudinal <sup>18</sup>F-FDG PET examinations in this cohort demonstrated that glucose metabolic reductions precede the onset of clinical symptoms by years and correlate with dementia severity in life and pathologic diagnosis of AD. Furthermore, the present results offer temporal and topographic in vivo information on the progressive involvement of different brain regions in the development of AD. Although <sup>18</sup>F-FDG PET profiles somewhat varied across subjects, glucose metabolic reductions were consistently detected in the hippocampus, followed by the parietotemporal and posterior cingulate cortices at the mild cognitive impairment or mild dementia stages. Hippocampal glucose metabolic reductions appeared to precede those in the cortical regions in cognitively normal individuals declining to AD, whereas the cortical hypometabolism became evident by the time that symptoms were expressed. These <sup>18</sup>F-FDG PET findings substantiate prior longitudinal observations without postmortem examinations by showing a progression of glucose metabolic deficits from the hippocampus to the association cortices in pathologically confirmed cognitively normal individuals who developed

mild cognitive impairment and AD and in patients with mild AD who further deteriorated over time. These in vivo imaging findings are consistent with the idea of progressive pathologic spreading in AD from the hippocampal formation to the association cortex (61) and with the Braak and Braak staging model of neurofibrillary tangle pathology in AD (62). Studies have shown that the progression of neurofibrillary tangles in the brain can be staged and that the pathologic changes develop many years before clinical manifestations of the disease become apparent using standard approaches to assessment (62,63). The pattern of hypometabolism seen in the progression of individuals from normal aging to AD is consistent with Braak stages of neurofibrillary tangle pathology determined at autopsy. Moreover, glucose metabolic changes in AD-related regions correlated with Braak stages of neurofibrillary tangles and with dementia severity in life (43). These data indicate also that cerebral glucose metabolic changes consistent with AD can be detected before the onset of dementia and progress with dementia severity. This perspective is also supported by recent findings based on longitudinal analysis of data acquired by the Alzheimer Disease

Neuroimaging Initiative (64,65).  $^{18}\text{F}$ -FDG PET is therefore also being considered as an imaging biomarker for AD before onset of dementia (66) and in clinical trials (67). Some authors emphasize early hippocampal involvement on  $^{18}\text{F}$ -FDG PET in AD (43). However, this finding remains controversial, because assessment of the magnitude of hippocampal hypometabolism on  $^{18}\text{F}$ -FDG PET is less reliable and as such is less recognized on visual inspection. Furthermore, hippocampal and medial temporal glucose hypometabolism can be prominent in some subtypes of FTD (68,69).

Cerebral glucose metabolic activity is an index of synaptic function and density (19,20), but hypometabolism is not specific for AD and is observed in other neurodegenerative disorders. AD-related glucose metabolic reductions could reflect reductions in the density or activity of terminal neuronal fields or perisynaptic glial cells (70–72), a metabolic dysfunction in neurons or glial cells not related to neuronal activity (73,74), or a combination of these factors. Diaschisis may represent another mechanism of regional glucose hypometabolism in neurodegeneration because of dysfunction of hippocampal output pathways resulting in hypometabolism of remotely connected brain regions, such as the posterior cingulate cortex (75). Remote deafferentation effects, including reduced posterior cingulate blood flow activity, have also been observed after temporal lobectomy in epilepsy patients (76). Therefore, metabolic reductions in the posterior cingulate in early AD may be explained in part by the loss of entorhinal efferents due to AD pathology (76).

Cerebral metabolic rate for glucose abnormalities in  $^{18}\text{F}$ -FDG PET studies of AD may be associated also with reduced neuronal expression of nuclear genes encoding subunits of the mitochondrial electron transport chain. For example, results from a genomewide transcriptomic study using neurons from autopsy brains of AD patients and cognitively normal controls found evidence of significantly reduced expression of energy metabolism genes that was most prominent in posterior cingulate neurons in AD brains (77). Reduction of genes encoding subunits of the mitochondrial electron transport chain in the posterior cingulate cortex was 70% lower in AD subjects than in cognitively normal subjects. Reductions in other AD brain areas were as follows: 65% reduction in the middle temporal gyrus, 61% in the hippocampal CA1 regions, 16% in the visual cortex, and 5% in the superior frontal gyrus (77). The topography of regional cerebral reduction of these energy metabolism genes parallels the typical  $^{18}\text{F}$ -FDG hypometabolism in AD.

## SAFETY

No safety issues have been raised in the multitude of papers that have studied the application of  $^{18}\text{F}$ -FDG PET in AD, AD-related dementia, or other neurodegenerative disorders, including posterior cortical atrophy, primary progressive aphasia, and Creutzfeldt-Jakob disease. A recent reference specifically mentioned the absence of any adverse effects related to the administration of the radiopharmaceu-

tical (15). The average dose of administered  $^{18}\text{F}$ -FDG activity was 185–370 MBq (5–10 mCi).

## LIMITATIONS

Although postmortem diagnosis of AD is considered the gold standard, even pathologic diagnosis is not beyond reproach. There is no universally accepted set of pathologic diagnostic criteria, and the various diagnostic algorithms place discordant degrees of reliance on varying diagnostic factors. Depending on the criteria used, a patient may not always receive the same autopsy diagnosis (78). Furthermore, mixed pathologies can be detected in patients diagnosed with AD at the time of autopsy (79), thus potentially limiting the specificity of any studies correlating  $^{18}\text{F}$ -FDG PET in vivo with postmortem diagnosis. For example, analysis of a multicenter brain bank study from 3,303 individuals found that 53.3% of brains had evidence of mixed pathologies, such as AD, vascular, and Lewy body pathologies (80). In these instances, it can be difficult, if not impossible, to determine the relative pathologic contributions to the patient's cognitive abnormalities.

The specificity of  $^{18}\text{F}$ -FDG PET diagnosis when clinically diagnosed AD patients are compared with cognitively normal subjects may also be limited because of emerging evidence of presymptomatic AD in otherwise healthy elderly persons (81).

The scope of this review does not include applications of  $^{18}\text{F}$ -FDG PET to mild cognitive impairment, as this concept has been evolving recently and thus may be inconsistently defined across studies. Furthermore, those studies that use a more consistent diagnosis of mild cognitive impairment are often limited to the amnesic subtype and may not reflect the entire spectrum of mild cognitive changes.

## TEMPORAL PROFILE OF $^{18}\text{F}$ -FDG PET IN RELATIONSHIP TO OTHER BIOMARKERS OF AD

Previous studies have shown that cerebrospinal fluid markers of amyloid  $\beta$ 42 and  $\tau$ -protein levels and imaging markers of  $^{18}\text{F}$ -FDG, fibrillary  $\beta$ -amyloid PET, and hippocampal volume using MRI are biomarkers associated with AD (43,82–84). Longitudinal analysis of Alzheimer Disease Neuroimaging Initiative data have allowed delineation of the temporal profiles of the different fluid and imaging biomarkers of AD. The results have shown that amyloid changes precede glucose hypometabolism or hippocampal atrophy (64,65,85). Elevated cerebrospinal fluid levels of phosphorylated  $\tau$ -protein have been associated with reduced glucose metabolism in the posterior cingulate, precuneus, and parahippocampal regions (86). More importantly, changes in glucose metabolism and hippocampal volume accelerate at the time of critical cognitive deterioration (85).

## LITERATURE REVIEW AND COMMENTS

Review of the scientific literature published since 2000 indicates several high-quality studies that have overcome

previously noted methodologic shortcomings in the  $^{18}\text{F}$ -FDG PET and AD literature (32,33,87). Although a previous meta-analysis showed a summary sensitivity of 86% for  $^{18}\text{F}$ -FDG PET for AD diagnosis and a summary specificity of 86%, the clinical utility of  $^{18}\text{F}$ -FDG PET was challenged and considered uncertain because of a lack of studies that included verification of AD diagnosis, a lack of studies using representative samples of patients (such as studies performed in a primary care setting), and a lack of studies that evaluated possible effects of the severity of dementia (33).

The present review identified a total of 11 subsequent papers that met the stringent review eligibility criteria. These papers included 4 studies using postmortem diagnosis as a gold standard to determine the diagnostic accuracy of  $^{18}\text{F}$ -FDG PET for AD (16,39,41,42), 2 studies using longitudinal clinical assessment of at least 1 y as an acceptable gold standard to determine the diagnostic accuracy of  $^{18}\text{F}$ -FDG PET for AD (34,35), 2 large multicenter studies (42,51), 2 studies from a predominantly primary care setting (34,35), 8 studies using comparison groups that included subjects with other types of dementia or cognitive complaints (16,34,35,39,41,42,51,94), and 3 studies that performed subgroup analyses of the severity of dementia (39,42,88).

These studies address the previously noted methodologic shortcomings in the literature before 2001. This review of the recent  $^{18}\text{F}$ -FDG PET AD literature demonstrates that the previously noted robust diagnostic accuracy of  $^{18}\text{F}$ -FDG PET in the diagnosis of AD prevails when studied under circumstances of a strict gold standard diagnostic reference, more heterogeneous comparison groups, application in primary care settings or across multiple centers, and subgroup analyses including mild symptomatic severity of disease. Therefore, the available evidence, including recent cohort studies based on postmortem and longitudinal clinical diagnosis, support the role of  $^{18}\text{F}$ -FDG PET as an effective and useful adjunct for the early diagnosis and differential diagnosis of AD. The diagnostic accuracy of  $^{18}\text{F}$ -FDG PET is high in patients with mild disease, for whom the clinical diagnosis and differential diagnosis are especially challenging. The identification and differential diagnosis of AD is especially challenging in its early stages, partly because of the difficulty in distinguishing it from the mild decline in memory than can occur with normal aging and from cognitive manifestations of other neuropsychiatric conditions, such as depression, as well as other causes of dementia (89).

Currently available data indicate that  $^{18}\text{F}$ -FDG PET brings added value to diagnostic evaluation of dementia over and above a routine, high-quality clinical assessment. For example, findings from a cohort study have shown that the sensitivity and specificity available with  $^{18}\text{F}$ -FDG PET near the time of initial diagnosis of AD is similar to longitudinal clinical diagnosis over 3–4 y (39). Thus, the use of  $^{18}\text{F}$ -FDG PET in the evaluation of patients with dementia can improve diagnostic accuracy and lead to earlier treatment, better planning for future care, and less suffering and uncertainty for patients and their families (34,56,90).

A significant further advancement in the use of  $^{18}\text{F}$ -FDG PET for suspected AD is the capacity to distinguish other neurodegeneration, such as DLB and FTD, in initial clinical evaluation (16,41). Moreover,  $^{18}\text{F}$ -FDG PET scans have received approval in the United States for Medicare reimbursement to aid in the distinction of AD from FTD (91).

The addition of  $^{18}\text{F}$ -FDG PET to clinical information alone increases not only diagnostic accuracy but also physician confidence in AD and FTD diagnoses (16). Furthermore, the value of  $^{18}\text{F}$ -FDG PET extends beyond diagnosis in dementia by also offering information on cortical metabolic status. The increase in diagnostic accuracy obtained by  $^{18}\text{F}$ -FDG PET is also recognized by the recently proposed diagnostic changes to the 1984 criteria of McKhann et al. (3), an initiative of the National Institute on Aging and the Alzheimer Association, in which the presence of biomarker evidence, including  $^{18}\text{F}$ -FDG PET temporoparietal hypometabolism, may increase the certainty that the clinical dementia syndrome is AD (92). As such,  $^{18}\text{F}$ -FDG PET has fulfilled the main criteria set forward for molecular and biochemical markers of AD by the Ronald and Nancy Reagan Research Institute of the Alzheimer Association and the National Institute on Aging Working Group (93).

## CONCLUSION

During the last decade, the evidence for  $^{18}\text{F}$ -FDG PET in AD and dementia has increased significantly with new papers that include autopsy confirmation, wide-diagnostic-spectrum recruitment, and multicenter data analysis. On the basis of these data,  $^{18}\text{F}$ -FDG PET is an effective and safe modality to identify diagnostic patterns of glucose hypometabolism in neurodegenerative dementias and is an effective and useful adjunct to other diagnostic information in the assessment of patients with progressive cognitive impairment.

## ACKNOWLEDGMENTS

We thank Jennifer Mills and Laura Grant for administrative assistance and Dr. Norman Foster for reviewing the manuscript.

## REFERENCES

1. Kung HC, Hoyert DL, Xu J, Murphy SL. Deaths: final data for 2005. *Natl Vital Stat Rep.* 2008;56:1–120.
2. Gauthier S, Reisberg B, Zaudig M, et al. Mild cognitive impairment. *Lancet.* 2006;367:1262–1270.
3. McKhann G, Drachman D, Folstein M, Katzman R, Price D, Stadlan EM. Clinical diagnosis of Alzheimer's disease: report of the NINCDS-ADRDA work group under the auspices of Department of Health and Human Services Task Force on Alzheimer's disease. *Neurology.* 1984;34:939–944.
4. Mirra SS, Heyman A, McKeel D, et al. The Consortium to Establish a Registry for Alzheimer's Disease (CERAD). Part II. Standardization of the neuropathological assessment of Alzheimer's disease. *Neurology.* 1991;41:479–486.
5. Selkoe DJ. Alzheimer's disease: genotypes, phenotypes, and treatments. *Science.* 1997;275:630–631.
6. Price JL, Morris JC. Tangles and plaques in nondemented aging and "preclinical" Alzheimer's disease. *Ann Neurol.* 1999;45:358–368.
7. Knopman DS, DeKosky ST, Cummings JL, et al. Practice parameter: diagnosis of dementia (an evidence-based review)—report of the Quality Standards

- Subcommittee of the American Academy of Neurology. *Neurology*. 2001;56:1143–1153.
8. DSM-III-R. *Diagnostic and Statistical Manual of Mental Disorders*. 3rd ed., revised. Washington, DC: American Psychiatric Association; 1987.
  9. Lim A, Tsuang D, Kukull W, et al. Clinico-neuropathological correlation of Alzheimer's disease in a community-based case series. *J Am Geriatr Soc*. 1999; 47:564–569.
  10. Jobst KA, Barnetson LP, Shepstone BJ. Accurate prediction of histologically confirmed Alzheimer's disease and the differential diagnosis of dementia: the use of NINCDS-ADRDA and DSM-III-R criteria, SPECT, x-ray CT, and Apo E4 in medial temporal lobe dementias. Oxford Project to Investigate Memory and Aging. *Int Psychogeriatr*. 1998;10:271–302.
  11. Galasko D, Hansen LA, Katzman R, et al. Clinical-neuropathological correlations in Alzheimer's disease and related dementias. *Arch Neurol*. 1994;51:888–895.
  12. Massoud F, Devi G, Stern Y, et al. A clinicopathological comparison of community-based and clinic-based cohorts of patients with dementia. *Arch Neurol*. 1999;56:1368–1373.
  13. Löppönen M, Raiha I, Isoaho R, Vahlberg T, Kivela SL. Diagnosing cognitive impairment and dementia in primary health care: a more active approach is needed. *Age Ageing*. 2003;32:606–612.
  14. Storandt M, Morris JC. Ascertainment bias in the clinical diagnosis of Alzheimer disease. *Arch Neurol*. 2010;67:1364–1369.
  15. Lowe VJ, Kemp BJ, Jack CR Jr, et al. Comparison of <sup>18</sup>F-FDG and PiB PET in cognitive impairment. *J Nucl Med*. 2009;50:878–886.
  16. Foster NL, Heidebrink JL, Clark CM, et al. FDG-PET improves accuracy in distinguishing frontotemporal dementia and Alzheimer's disease. *Brain*. 2007; 130:2616–2635.
  17. Herholz K, Nordberg A, Salmon E, et al. Impairment of neocortical metabolism predicts progression in Alzheimer's disease. *Dement Geriatr Cogn Disord*. 1999; 10:494–504.
  18. Kuhl DE. Imaging local brain function with emission computed tomography. *Radiology*. 1984;150:625–631.
  19. Sokoloff L. Relation between physiological function and energy metabolism in the central nervous system. *J Neurochem*. 1977;29:13–26.
  20. Liu X, Erikson C, Brun A. Cortical synaptic changes and gliosis in normal aging, Alzheimer's disease and frontal lobe degeneration. *Dementia*. 1996;7:128–134.
  21. Minoshima S, Foster NL, Kuhl DE. Posterior cingulate cortex in Alzheimer's disease. *Lancet*. 1994;344:895.
  22. Foster NL, Chase TN, Mansi L, et al. Cortical abnormalities in Alzheimer's disease. *Ann Neurol*. 1984;16:649–654.
  23. Kuhl DE, Metter J, Benson DF, et al. Similarities in cerebral glucose metabolism in Alzheimer's and parkinsonian dementia. *J Cereb Blood Flow Metab*. 1985;5 (suppl 1):S169–S170.
  24. Friedland RP, Brun A, Budinger TF. Pathological and positron emission tomographic correlations in Alzheimer's disease [letter]. *Lancet*. 1985;1:228.
  25. Mielke R, Schroder R, Fink GR, Kessler J, Herholz K, Heis WD. Regional cerebral glucose metabolism and postmortem pathology in Alzheimer's disease. *Acta Neuropathol*. 1996;91:174–179.
  26. Minoshima S, Giordani B, Berent S, Frey KA, Foster NL, Kuhl DE. Metabolic reduction in the posterior cingulate cortex in very early Alzheimer's disease. *Ann Neurol*. 1997;42:85–94.
  27. Reiman EM, Caselli RJ, Yun LS, et al. Preclinical evidence of Alzheimer's disease in persons homozygous for the e4 allele for apolipoprotein E. *N Engl J Med*. 1996;334:752–758.
  28. Womack KB, Diaz-Arrastia R, Aizenstein HJ, et al. Temporoparietal hypometabolism in frontotemporal lobar degeneration and associated imaging diagnostic errors. *Arch Neurol*. 2011;68:329–337.
  29. Weaver JD, Espinoza R, Weintraub NT. The utility of PET brain imaging in the initial evaluation of dementia. *J Am Med Dir Assoc*. 2007;8:150–157.
  30. Mielke R, Heiss WD. Positron emission tomography for diagnosis of Alzheimer's disease and vascular dementia. *J Neural Transm Suppl*. 1998;53:237–250.
  31. Herholz K, Schopphoff H, Schmidt M, et al. Direct comparison of spatially normalized PET and SPECT scans in Alzheimer's disease. *J Nucl Med*. 2002;43:21–26.
  32. Gill SS, Rochon PA, Guttman M, Laupacis A. The value of positron emission tomography in the clinical evaluation of dementia. *J Am Geriatr Soc*. 2003;51: 258–264.
  33. Patwardhan MB, McCrory DC, Matchar DB, Samsa GP, Rutschmann OT. Alzheimer disease: operating characteristics of PET—a meta-analysis. *Radiology*. 2004;231:73–80.
  34. Döbert N, Pantel J, Frolich L, Hamscho N, Menzel C, Grunwald F. Diagnostic value of FDG-PET and HMPAO-SPET in patients with mild dementia and mild cognitive impairment: metabolic index and perfusion index. *Dement Geriatr Cogn Disord*. 2005;20:63–70.
  35. Panegyres PK, Rogers JM, McCarthy M, Campbell A, Wu JS. Fluorodeoxyglucose-positron emission tomography in the differential diagnosis of early-onset dementia: a prospective, community-based study. *BMC Neurol*. 2009;9:41.
  36. Varma AR, Snowden JS, Lloyd JJ, Talbot PR, Mann DM, Neary D. Evaluation of the NINCDS-ADRDA criteria in the differentiation of Alzheimer's disease and frontotemporal dementia. *J Neurol Neurosurg Psychiatry*. 1999;66:184–188.
  37. Mendez M, Perryman K, Patton R, Frey W. Alzheimer's disease with and without the neuropathology of Parkinson's disease: clinical and epidemiological differences [abstract]. *Neurology*. 1998;50(suppl 4):A281.
  38. Burke JF, Albin RL, Koeppe RA, et al. Assessment of mild dementia with amyloid and dopamine terminal positron emission tomography. *Brain*. 2011;134:1647–1657.
  39. Jagust W, Reed B, Mungas D, Ellis W, Decarli C. What does fluorodeoxyglucose PET imaging add to a clinical diagnosis of dementia? *Neurology*. 2007;69:871–877.
  40. Hoffman JM, Welsh-Bohmer KA, Hanson M, et al. FDG PET imaging in patients with pathologically verified dementia. *J Nucl Med*. 2000;41:1920–1928.
  41. Minoshima S, Foster NL, Sima AA, Frey KA, Albin RL, Kuhl DE. Alzheimer's disease versus dementia with Lewy bodies: cerebral metabolic distinction with autopsy confirmation. *Ann Neurol*. 2001;50:358–365.
  42. Silverman DH, Small GW, Chang CY, et al. Positron emission tomography in evaluation of dementia: regional brain metabolism and long-term outcome. *JAMA*. 2001;286:2120–2127.
  43. Mosconi L, Mistur R, Switalski R, et al. FDG-PET changes in brain glucose metabolism from normal cognition to pathologically verified Alzheimer's disease. *Eur J Nucl Med Mol Imaging*. 2009;36:811–822.
  44. Albin RL, Minoshima S, D'Amato CJ, Frey KA, Kuhl DE, Sima AAF. Fluorodeoxyglucose positron emission tomography in diffuse Lewy body disease. *Neurology*. 1996;47:462–466.
  45. McKeith IG, Dickson DW, Lowe J, et al. Diagnosis and management of dementia with Lewy bodies: third report of the DLB Consortium. *Neurology*. 2005;65:1863–1872.
  46. Luis CA, Barker WW, Gajraj K, et al. Sensitivity and specificity of three clinical criteria for dementia with Lewy bodies in an autopsy-verified sample. *Int J Geriatr Psychiatry*. 1999;14:526–533.
  47. McKeith IG, Ballard CG, Perry RH, et al. Prospective validation of consensus criteria for the diagnosis of dementia with Lewy bodies. *Neurology*. 2000;54:1050–1058.
  48. Neary D, Snowden JS, Gustafson L, et al. Frontotemporal lobar degeneration: a consensus on clinical diagnostic criteria. *Neurology*. 1998;51:1546–1554.
  49. Hodges JR, Patterson K, Oxbury S, Funnell E. Semantic dementia: progressive fluent aphasia with temporal lobe atrophy. *Brain*. 1992;115:1783–1806.
  50. Friedland RP, Koss E, Lerner A, et al. Functional imaging, the frontal lobes, and dementia. *Dementia*. 1993;4:192–203.
  51. Diehl-Schmid J, Grimmer T, Drzezga A, et al. Decline of cerebral glucose metabolism in frontotemporal dementia: a longitudinal <sup>18</sup>F-FDG-PET-study. *Neurobiol Aging*. 2007;28:42–50.
  52. Mosconi L, Tsui WH, Herholz K, et al. Multicenter standardized <sup>18</sup>F-FDG PET diagnosis of mild cognitive impairment, Alzheimer's disease, and other dementias. *J Nucl Med*. 2008;49:390–398.
  53. Ishii K, Sakamoto S, Sasaki M, et al. Cerebral glucose metabolism in patients with frontotemporal dementia. *J Nucl Med*. 1998;39:1875–1878.
  54. Jeong Y, Park KC, Cho SS, et al. Pattern of glucose hypometabolism in frontotemporal dementia with motor neuron disease. *Neurology*. 2005;64:734–736.
  55. Diehl-Schmid J, Grimmer T, Drzezga A, et al. Longitudinal changes of cerebral glucose metabolism in semantic dementia. *Dement Geriatr Cogn Disord*. 2006; 22:346–351.
  56. Laforce R Jr, Buteau JP, Paquet N, Verret L, Houde M, Bouchard RW. The value of PET in mild cognitive impairment, typical and atypical/unclear dementias: a retrospective memory clinic study. *Am J Alzheimers Dis Other Demen*. 2010; 25:324–332.
  57. Li Y, Rinne JO, Mosconi L, et al. Regional analysis of FDG and PiB-PET images in normal aging, mild cognitive impairment, and Alzheimer's disease. *Eur J Nucl Med Mol Imaging*. 2008;35:2169–2181.
  58. Minoshima S, Frey KA, Koeppe RA, Foster NL, Kuhl DE. A diagnostic approach in Alzheimer's disease using three-dimensional stereotactic surface projections of fluorine-18-FDG PET. *J Nucl Med*. 1995;36:1238–1248.
  59. Friston K, Holmes A, Worsley K, Poline J-B, Frith C, Frackowiak R. Statistical parametric maps in functional imaging: a general linear approach. *Hum Brain Mapp*. 1995;2:189–210.
  60. Herholz K, Salmon E, Perani D, et al. Discrimination between Alzheimer dementia and controls by automated analysis of multicenter FDG PET. *Neuroimage*. 2002;17:302–316.
  61. Ball MJ, Fisman M, Hachinski V, et al. A new definition of Alzheimer's disease: a hippocampal dementia. *Lancet*. 1985;1:14–16.
  62. Braak H, Braak E. Neuropathological staging of Alzheimer-related changes. *Acta Neuropathol*. 1991;82:239–259.

63. Braak H, Braak E. Development of Alzheimer-related neurofibrillary changes in the neocortex inversely recapitulates cortical myelogenesis. *Acta Neuropathol.* 1996;92:197–201.
64. Landau SM, Harvey D, Madison CM, et al. Associations between cognitive, functional, and FDG-PET measures of decline in AD and MCI. *Neurobiol Aging.* 2011;32:1207–1218.
65. Chen K, Langbaum JB, Fleisher AS, et al. Twelve-month metabolic declines in probable Alzheimer's disease and amnesic mild cognitive impairment assessed using an empirically pre-defined statistical region-of-interest: findings from the Alzheimer's Disease Neuroimaging Initiative. *Neuroimage.* 2010;51:654–664.
66. Dubois B, Feldman HH, Jacova C, et al. Revising the definition of Alzheimer's disease: a new lexicon. *Lancet Neurol.* 2010;9:1118–1127.
67. Hampel H, Frank R, Broich K, et al. Biomarkers for Alzheimer's disease: academic, industry and regulatory perspectives. *Nat Rev Drug Discov.* 2010;9:560–574.
68. Garraux G, Salmon E, Degueldre C, Lemaire C, Franck G. Medial temporal lobe metabolic impairment in dementia associated with motor neuron disease. *J Neurol Sci.* 1999;168:145–150.
69. Franceschi M, Anchisi D, Pelati O, et al. Glucose metabolism and serotonin receptors in the frontotemporal lobe degeneration. *Ann Neurol.* 2005;57:216–225.
70. Schwartz WJ, Smith CB, Davidsen L, et al. Metabolic mapping of functional activity in the hypothalamo-neurohypophysial system of the rat. *Science.* 1979;205:723–725.
71. Magistretti PJ, Pellerin L. Cellular mechanisms of brain energy metabolism and their relevance to functional brain imaging. *Philos Trans R Soc Lond B Biol Sci.* 1999;354:1155–1163.
72. Magistretti PJ. Neuron-glia metabolic coupling and plasticity. *J Exp Biol.* 2006;209:2304–2311.
73. Piert M, Koeppe RA, Giordani B, Berent S, Kuhl DE. Diminished glucose transport and phosphorylation in Alzheimer's disease determined by dynamic FDG-PET. *J Nucl Med.* 1996;37:201–208.
74. Mark RJ, Pang Z, Geddes JW, Uchida K, Mattson MP. Amyloid beta-peptide impairs glucose transport in hippocampal and cortical neurons: involvement of membrane lipid peroxidation. *J Neurosci.* 1997;17:1046–1054.
75. Yakushev I, Schreckenberger M, Müller MJ, et al. Functional implications of hippocampal degeneration in early Alzheimer's disease: a combined DTI and PET study. *Eur J Nucl Med Mol Imaging.* 2011;38:2219–2227.
76. Minoshima S, Cross DJ, Foster NL, Henry TR, Kuhl DE. Discordance between traditional pathologic and energy metabolic changes in very early Alzheimer's disease: pathophysiological implications. *Ann N Y Acad Sci.* 1999;893:350–352.
77. Liang WS, Reiman EM, Valla J, et al. Alzheimer's disease is associated with reduced expression of energy metabolism genes in posterior cingulate neurons. *Proc Natl Acad Sci USA.* 2008;105:4441–4446.
78. Paulus W, Bancher C, Jellinger K. Interrater reliability in the neuropathologic diagnosis of Alzheimer's disease. *Neurology.* 1992;42:329–332.
79. Schneider JA, Arvanitakis Z, Leurgans SE, Bennett DA. The neuropathology of probable Alzheimer disease and mild cognitive impairment. *Ann Neurol.* 2009;66:200–208.
80. Kovacs GG, Alafuzoff I, Al-Sarraj S, et al. Mixed brain pathologies in dementia: the BrainNet Europe consortium experience. *Dement Geriatr Cogn Disord.* 2008;26:343–350.
81. Aizenstein HJ, Nebes RD, Saxton JA, et al. Frequent amyloid deposition without significant cognitive impairment among the elderly. *Arch Neurol.* 2008;65:1509–1517.
82. Sunderland T, Linker G, Mirza N, et al. Decreased beta-amyloid1-42 and increased tau levels in cerebrospinal fluid of patients with Alzheimer disease. *JAMA.* 2003;289:2094–2103.
83. Jack CR Jr, Petersen RC, O'Brien PC, Tangalos EG. MR-based hippocampal volumetry in the diagnosis of Alzheimer's disease. *Neurology.* 1992;42:183–188.
84. Klunk WE, Engler E, Nordberg A, et al. Imaging brain amyloid in Alzheimer's disease using the novel positron emission tomography tracer, Pittsburgh Compound-B. *Ann Neurol.* 2004;55:306–319.
85. Lo RY, Hubbard AE, Shaw LM, et al. Longitudinal change of biomarkers in cognitive decline. *Arch Neurol.* 2011;68:1257–1266.
86. Petrie EC, Cross DJ, Galasko D, et al. Preclinical evidence of Alzheimer changes: convergent cerebrospinal fluid biomarker and fluorodeoxyglucose positron emission tomography findings. *Arch Neurol.* 2009;66:632–637.
87. Lucignani G, Nobili F. FDG-PET for early assessment of Alzheimer's disease: isn't the evidence base large enough? *Eur J Nucl Med Mol Imaging.* 2010;37:1604–1609.
88. Mosconi L, Tsui WH, Pupi A, et al. <sup>18</sup>F-FDG PET database of longitudinally confirmed healthy elderly individuals improves detection of mild cognitive impairment and Alzheimer's disease. *J Nucl Med.* 2007;48:1129–1134.
89. Silverman DH, Mosconi L, Ercoli L, Chen W, Small GW. Positron emission tomography scans obtained for the evaluation of cognitive dysfunction. *Semin Nucl Med.* 2008;38:251–261.
90. McMurtray AM, Licht E, Yeo T, Krisztal E, Saul RE, Mendez MF. Positron emission tomography facilitates diagnosis of early-onset Alzheimer's disease. *Eur Neurol.* 2008;59:31–37.
91. Medicare National Coverage Determinations Manual: Chapter 1, Part 4 (Sections 200–310.1)—Coverage Determinations. Centers for Medicare and Medicaid Services Web site. Available at: [http://www.cms.gov/manuals/downloads/ncd103c1\\_Part4.pdf](http://www.cms.gov/manuals/downloads/ncd103c1_Part4.pdf). Accessed November 21, 2011.
92. McKhann GM, Knopman DS, Chertkow H, et al. The diagnosis of dementia due to Alzheimer's disease: recommendations from the National Institute on Aging-Alzheimer's Association workgroups on diagnostic guidelines for Alzheimer's disease. *Alzheimers Dement.* 2011;7:263–269.
93. Consensus report of the working group on: "Molecular and Biochemical Markers of Alzheimer's Disease". The Ronald and Nancy Reagan Research Institute of the Alzheimer's Association and the National Institute on Aging Working Group. *Neurobiol Aging.* 1998;19:109–116.
94. Ng S, Villemagne VL, Berlangieri S, et al. Visual assessment versus quantitative assessment of <sup>11</sup>C-PIB PET and <sup>18</sup>F-FDG PET for detection of Alzheimer's disease. *J Nucl Med.* 2007;48:547–552.
95. Chen WP, Samuraki M, Yanase D, et al. Effect of sample size for normal database on diagnostic performance of brain FDG PET for the detection of Alzheimer's disease using automated image analysis. *Nucl Med Commun.* 2008;29:270–276.