

# Nuclear Arthrography: Combined Scintigraphic and Radiographic Procedure for Diagnosis of Total Hip Prosthesis Loosening

Wim J.G. Oyen, J. Albert M. Lemmens, Roland A.M.J. Claessens, James R. van Horn, Tom J.J.H. Slooff and Frans H.M. Corstens

Departments of Nuclear Medicine, Radiology and Orthopedics, University Hospital Nijmegen, Nijmegen, The Netherlands

Radiographic arthrography and bone scintigraphy are common diagnostic procedures used for evaluating total hip prostheses. In this study, both techniques are combined, and nuclear contrast imaging (nuclear arthrography) is added. The efficacy of the procedures is evaluated. **Methods:** After intravenous injection of  $^{99m}\text{Tc}$ -methylene diphosphonate (MDP), standard radiographic arthrography was performed in 105 patients (107 prostheses). The radiographic contrast medium was mixed with insoluble  $^{111}\text{In}$ -colloid (5 MBq/20 ml). After completion of the radiographic arthrography, nuclear arthrography was performed, and multiple-view dual-isotope images ( $^{111}\text{In}$ , 247-keV peak only) were recorded. Images were interpreted by superposition of the  $^{111}\text{In}$  image and the corresponding  $^{99m}\text{Tc}$ -MDP image, the latter serving as a landmark for the position of the prosthesis and osseous structures. Findings at surgery were used as the gold standard. **Results:** In both cemented and uncemented acetabular and femoral components, nuclear arthrography performed better than or equal to radiographic arthrography (70%–90% and 60%–75%, respectively). Nuclear arthrography had higher diagnostic accuracy than  $^{99m}\text{Tc}$ -MDP images alone. **Conclusion:** Nuclear arthrography is a sensitive technique for detection of loosening of prostheses, offering added value over radiographic arthrography and bone scanning alone, especially for evaluation of the femoral component. Radiographic arthrography remains necessary not only for adequate deposition of contrast agents but also for detailed evaluation of osseous structures.

**Key Words:** bone scintigraphy; hip prosthesis loosening; nuclear arthrography; radiographic arthrography; technetium-99m-MDP; indium-111-colloid

**J Nucl Med 1996; 37:62–70**

At present, joint arthroplasty is a procedure performed with increasing frequency as the population ages. Because joint prostheses have a limited life, loosening of the prosthesis is a common event (1,2). Revision of a loose prosthesis may be indicated, depending on the patient's condition and complaints and the presence of infection. Because revision of a total hip prosthesis implies major surgery with its inherent complications, reliable preoperative evaluating very important with regard to patient management (1). In addition to clinical evaluation, several radiographic and scintigraphic techniques are currently available for evaluating possible loosening of total hip prosthesis, such as plain radiography of the pelvis, radiographic contrast examination of the prosthetic joint and  $^{99m}\text{Tc}$ -methylene diphosphonate (MDP) bone scintigraphy (3). Several reports have suggested the added value of nuclear arthrography, which involves intra-articular injection of a radionuclide performed in combination with radiographic contrast arthrography (4–6). In 1988, Wellman et al. (4) reported a

modified approach by including  $^{99m}\text{Tc}$ -MDP bone scintigraphy and  $^{111}\text{In}$  as the radionuclide contrast agent in the study protocol, thereby allowing correlation of the arthrographic radionuclide distribution with the bone scan.

The aim of the present study was to evaluate the usefulness of radiographic contrast arthrography (including photographic subtraction) and scintigraphic studies (bone scan and nuclear arthrography) to define guidelines for optimal assessment of a painful total hip prosthesis.

## METHODS

### Patients

Patients who were referred for radiographic contrast arthrography for evaluation of possible loosening of total hip prosthesis were eligible for the study. Over a period of 3 yr, 107 prostheses in 105 patients were studied. Clinical characteristics are summarized in Table 1. All patients underwent surgical revision of the prosthesis, the gold standard for loosening. In 46 patients both the acetabular and femoral components were loose, in 30 the acetabular component only, in 20 the femoral component only and in 10 neither component. The underlying condition that caused the hip joint destruction, the type of total hip prosthesis and the life of the prosthesis were recorded (Table 1).

### Preparation of Radiographic and Scintigraphic Contrast Agent

Omnipaque 300 isotonic contrast (Iohexol 647 mg/ml; Nycomed Imaging AS, Oslo, Norway) was used as the radiographic contrast agent. For the purpose of the present study, a 20:1 mixture of Omnipaque 300 and the scintigraphic contrast agent  $^{111}\text{In}$  (indium chloride; Amersham International Ltd., Buckinghamshire, UK) was prepared. In the first 10 patients, 10 MBq  $^{111}\text{In}$  in 1 ml was added to 20 ml Omnipaque 300. In 5 of these 10 patients, low  $^{111}\text{In}$  activity in the joint space and significant  $^{111}\text{In}$  activity in the bladder were observed, indicating resorption of the intra-articularly injected  $^{111}\text{In}$ . Therefore, an  $^{111}\text{In}$ -colloid solution, known to have only minimal tissue resorption, was used in the subsequent patients. Indium-111-ferric hydroxide colloid was produced by adding 1 mg ferric chloride ( $\text{FeCl}_3$ ; E. Merck, Darmstadt, Germany) in acidic solution (0.04 M hydrochloric acid) to the  $^{111}\text{In}$  solution and increasing the pH in two steps to 5.6. Large particles in the  $^{111}\text{In}$ -colloid were removed using a 0.2-mm filter (Millipore SA, Molsheim, France). The Omnipaque/ $^{111}\text{In}$ -colloid mixture was prepared as previously described. Because only minimal  $^{111}\text{In}$  resorption from the joint space was observed when using the  $^{111}\text{In}$ -colloid, the  $^{111}\text{In}$  dose was reduced to 5 MBq/ml.

### Imaging Protocol

Approximately 1 hr before radiographic contrast arthrography, 600 MBq of the bone scanning agent  $^{99m}\text{Tc}$ -MDP was injected intravenously. The radiographic arthrography technique was performed as described by Barents et al. (7) and Hendrix and

Received Dec. 16, 1994; revision accepted May 15, 1995.

For correspondence or reprints contact: Wim J.G. Oyen, MD, Department of Nuclear Medicine, University Hospital Nijmegen, P.O. Box 9101, 6500 HB Nijmegen, The Netherlands.

**TABLE 1**

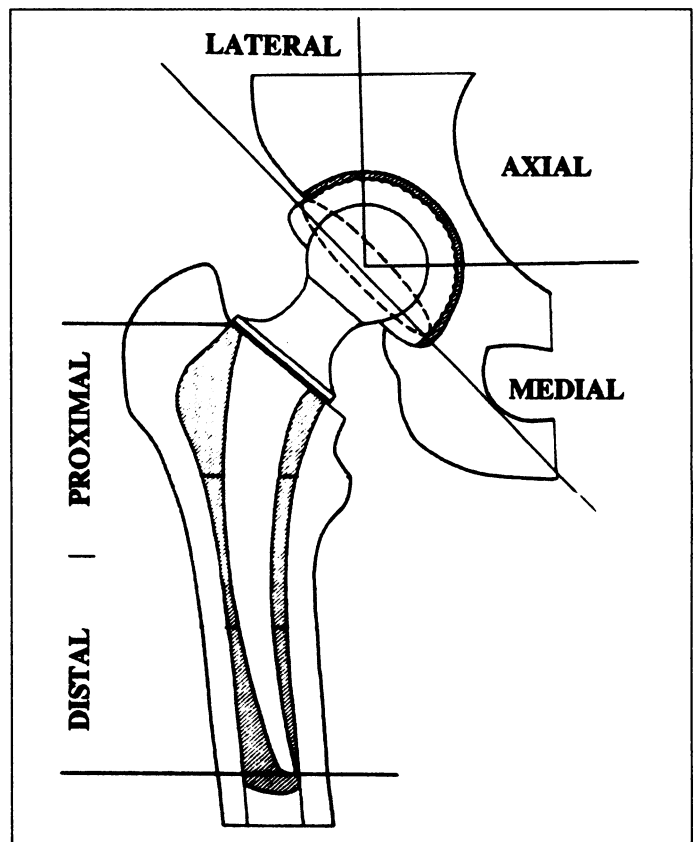
Clinical Characteristics of 107 Patients with Total Hip Prostheses

Male	29 (27.1%)
Female	78 (72.9%)
Age (yr)	
Mean	62.8
Range	28-85
Underlying hip disease	
Degenerative osteoarthritis	62 (58.0%)
Femoral head necrosis	18 (16.8%)
After femoral neck fracture	13 (12.1%)
Perthes disease	3 (2.8%)
Cortisone induced	2 (1.9%)
Rheumatoid arthritis	13 (12.1%)
Congenital hip dysplasia	14 (13.1%)
Acetabular component	
Cemented	72 (67.3%)
Uncemented	35 (32.7%)
Threaded socket	19 (17.8%)
Nonthreaded socket	16 (14.9%)
Femoral component	
Cemented	76 (71.0%)
Uncemented	31 (29.0%)
Primary prosthesis	74 (69.2%)
Revised prosthesis	33 (30.8%)
Prosthesis lifespan (yr)	
All	
Mean	6.3
Range	0.5-17
Primary	
Mean	7.4*
Range	1-17
Revised	
Mean	3.9*
Range	0.5-16

\*Lifespan of revised prostheses significantly shorter than that of primary prostheses (p < 0.001, two-tailed Wilcoxon test).

Anderson (8). In brief, the prosthetic joint space was reached under fluoroscopic guidance by lateral puncture using an 18 gauge needle with a blunt trocar. When possible, joint fluid was aspirated. Before injection of the contrast mixture, a template radiograph was made. After each 10-ml portion of contrast agent, additional radiographs were obtained. Contrast administration was stopped when the patient indicated increasing pain in the hip and upper leg region and when a clear increase in pressure was felt during contrast administration. When both pain and pressure increase were absent, a maximum dose of 40 ml of the contrast mixture was used. In most patients, a contrast dose of 10-20 ml was adequate. When contrast leakage was not apparent, the template radiograph and the radiograph with the largest contrast volume were photographically subtracted (7).

After radiographic arthrography, the patient walked to the nuclear medicine department when possible (approximately 200 m) to achieve an increase in intra-articular pressure. Approximately 3 hr after injection of <sup>99m</sup>Tc-MDP and 2 hr after radiographic arthrography, scintigraphic images of the prosthetic hip were recorded from four angles (anterior, posterior, lateral and medial-oblique; 300,000 counts per view). A gamma camera equipped with a medium-energy parallel-hole collimator was used for both the <sup>99m</sup>Tc-MDP bone scan images and the <sup>111</sup>In images. The bone scan images were obtained using the 140-keV photopeak with a symmetrical 10% window, thus reducing <sup>111</sup>In scatter in the <sup>99m</sup>Tc photopeak. Images of the intra-articularly injected <sup>111</sup>In were



**FIGURE 1.** Diagram of a total hip prosthesis indicating the divisions of the acetabular and femoral components.

obtained using the 247-keV photopeak only, with a symmetrical 15% window. All scintigraphic images were recorded in digital format in a 256 × 256 matrix for a preset time of 5 min.

**Image Interpretation**

The radiographs and scintigrams were read independently and without knowledge of either clinical data or surgical findings. As indicated in Figure 1, the acetabular component was divided into three segments for estimation of contrast leakage: medial, axial and lateral. The femoral component was divided into two segments: proximal and distal (7).

The radiographic arthrography included estimation of contrast leakage around the acetabular and femoral components on the contrast radiographs and subtraction photograph (7) and registration of additional findings, such as trochanteric bursa, bone resorption and lymph vessel filling.

Scintigraphic assessment included evaluation of the findings on

**TABLE 2**  
Surgical Findings for Loosening

Acetabular component	
Total	76/107 (71.0%)
Cemented	55/72 (76.4%)
Uncemented	21/35 (60.0%)
Threaded socket	15/19 (78.9%)
Nonthreaded socket	6/16 (37.5%)
Femoral component	
Total	66/107 (61.7%)
Cemented	49/76 (64.5%)
Uncemented	17/31 (54.8%)

**TABLE 3**  
Positive Results of Intraoperative Microbiological Cultures in 20 Patients

Culture result	No. of positive cultures			Loosening at surgery	
	P	R	Total	Acetabular	Femoral
<i>Corynebacterium</i>	—	1	1	1	1
<i>Propionibacterium acnes</i> *	1	2	3	2	2
<i>Staphylococcus epidermidis</i>	7†	3	10	9	10
<i>Staphylococcus aureus</i>	—	3	3	3	3
<i>Streptococcus faecalis</i>	1	—	1	1	1
<i>Beta-hemolytic streptococci</i>	2	—	2	2	2
Total	11 (14.9%)	9 (27.3%)	20 (18.7%)	18	19

\*Contaminants.  
†In one patient one positive culture in very low Tc counts, considered contaminant.  
P = primary prosthesis; R = revised prosthesis.

the bone scan alone (scored as increased periprosthetic uptake or normal periprosthetic uptake). Increased uptake of <sup>99m</sup>Tc-MDP in the femoral neck region was not considered indicative of loosening because it is indicative of active periarticular ossifications (9). Furthermore, <sup>111</sup>In leakage around the acetabular and femoral components was estimated using the <sup>99m</sup>Tc-MDP images as a landmark for the osseous structures and prosthesis (4).

From the data obtained during revision arthroplasty, diagnostic criteria for radiographic and scintigraphic loosening of total hip prosthesis in both cemented and uncemented prostheses were derived.

### Statistics

Sensitivity, specificity, negative predictive value, positive predictive value and diagnostic accuracy were calculated. The number of correct and incorrect diagnostic observations were compared using the chi square test with the Yates correction.

## RESULTS

### Patients

The overall surgical findings with regard to loosening are summarized in Table 2. In 20 patients (12 with cemented, 8 with uncemented total hip prostheses), positive microbiological culture results were obtained (Table 3). These results indicated an infected prosthesis in 16 patients (9 with a primary prosthesis, 7 with a revised prosthesis; 15.0% of the study cohort). Of these 16 patients, bone scan showed elevated periprosthetic

uptake in the acetabular region in 15 and the femoral region in 13. In the remaining four patients, the cultured microorganism was considered a contaminant (*Staphylococcus epidermidis* in one patient in one culture only, *Propionibacterium acnes* in three patients).

### Acetabular Component

**Cemented Acetabulum.** Tables 4 and 5 show the results of radiographic arthrography and nuclear arthrography compared with the surgical findings for the cemented acetabular components (n = 72). As shown in Table 4, both examinations show many false-positive examination results, no matter what criteria for loosening were considered.

When loosening criteria were derived from these data, nuclear arthrography had the highest diagnostic accuracy for contrast leakage seen at least in the axial segment (MAL, MA or AL in Table 4) (p < 0.05). For radiographic arthrography, both the requirement of contrast leakage around the entire acetabulum (MAL in Table 4) and the optimal nuclear arthrography criterion (MAL, MA or AL in Table 4) yielded equal diagnostic accuracy. No statistically significant differences could be observed between nuclear arthrography and radiographic arthrography when the two procedures were compared.

Of 51 patients with elevated periacetabular uptake by bone scan alone, the acetabulum was surgically loose in 41. Of 21 patients with normal periacetabular <sup>99m</sup>Tc-MDP uptake, the acetabulum proved to be loose in 14. These findings indicate that bone scan alone is neither very sensitive nor very specific (75% and 41%, respectively) (Table 5) and is significantly less accurate than nuclear arthrography (p = 0.05).

**TABLE 4**  
Results of NA and RGA Compared with Surgical Findings for 72 Cemented Acetabular Components

Segment with contrast agent	NA		RGA	
	Loose	Not loose	Loose	Not loose
MAL	37	9	44	8
MA	14	3	6	4
AL	3	—	—	—
M	—	2	2	2
L	—	—	—	1
None	1	3	3	2

M = medial; A = axial; L = lateral.

**TABLE 5**  
Analysis of Diagnostic Procedures in 72 Cemented Acetabular Components for Contrast Leakage Visualized in Axial Segment\* for Both Nuclear Arthrography and Radiographic Arthrography

	Bone scan	NA	RGA
Sensitivity (%)	75	98	91
Specificity (%)	41	29	29
Positive predictive value (%)	80	82	81
Negative predictive value (%)	33	83	50
Diagnostic accuracy (%)	67	82	76

\*MAL, MA or AL in Table 4.

**TABLE 6**  
Results of Nuclear Arthrography and Radiographic Arthrography Compared with Surgical Findings for 35 Uncemented Acetabular Components

Segment with contrast agent	NA				RGA			
	All uncemented acetabular components		Threaded uncemented acetabular components		All uncemented acetabular components		Threaded uncemented acetabular components	
	Loose	Not loose	Loose	Not loose	Loose	Not loose	Loose	Not loose
MAL	13	3	6	2	17	4	12	3
MA	6	1	8	—	1	3	1	1
AL	1	—	1	—	—	2	—	—
M	—	7	—	1	1	5	1	—
L	—	2	—	1	—	—	—	—
None	1	1	—	—	2	—	1	—

M = medial; A = axial; L = lateral.

**Uncemented Acetabulum.** Tables 6 and 7 show the results of radiographic arthrography and nuclear arthrography compared with surgical findings for uncemented acetabular components (n = 35). When loosening criteria were derived from these data, no statistically significant difference was found between the diagnostic accuracy achieved when leakage around the entire acetabulum (MAL in Table 6) was considered loosening or when the optimal criterion for cemented acetabula (MAL, MA or AL in Table 6) was used. This finding applies to both nuclear arthrography and radiographic arthrography. When the results of nuclear arthrography and radiographic arthrography were compared, nuclear arthrography performed marginally better than radiographic arthrography (p < 0.10).

Bone scan alone showed increased uptake around the acetabulum in 24 patients, 16 of whom had a loose acetabulum at operation. Of 11 patients with normal scan results in this region, the acetabulum proved to be loose in 5, again indicating relatively low sensitivity and specificity (Table 7) and significantly less accuracy than nuclear arthrography (p = 0.05).

When the threaded socket type of uncemented acetabular component was considered separately, results were similar for the whole group of uncemented acetabular prostheses for both scintigraphic procedures (Tables 6 and 7). Although the numbers are small in this subgroup of patients, significant leakage was identified on radiographic arthrography in all patients, resulting in extremely low specificity.

**Femoral Component**

**Cemented Femoral Component.** Tables 8 and 9 show the results of radiographic arthrography and nuclear arthrography compared with surgical findings for cemented femoral components (n = 76). On the basis of loosening criteria derived from these data, both nuclear arthrography and radiographic arthrography had marginally better diagnostic accuracy when contrast leakage was seen in the distal segment at least (Tip or PD in Table 8) than when contrast leakage all the way down to the tip of the prosthesis was required (Tip in Table 8) (p < 0.10). Nuclear arthrography performed significantly better than radiographic arthrography in this group of patients (p < 0.05). Examples of scintigraphic and radiographic images are shown in Figures 2–4, with concordant nuclear arthrography and radiographic arthrography findings seen in Figures 2 and 3. In Figure 4, which shows the images from a patient with confirmed loosening of both components of the prosthesis, however, nuclear arthrography provides adequate depiction, whereas radiographic arthrography shows no contrast leakage.

Bone scanning alone showed elevated periprosthetic uptake in 46 patients, 39 of whom had a loose femoral component at operation (21 with activity at the tip only, 18 with loosening). Twenty-five patients had more diffusely elevated uptake, including 10 with an infected prosthesis. Of 30 patients with normal bone scan results in the femoral region, the femoral component was considered loose at surgery in 10. Although not

**TABLE 7**  
Analysis of Diagnostic Procedures in 35 Uncemented Acetabular Components for Both Nuclear Arthrography and Radiographic Arthrography Contrast Leakage Visualized in Axial Segment\*

	Bone scan		NA		RGA	
	All uncemented acetabular components	Threaded uncemented acetabular components	All uncemented acetabular components	Threaded uncemented acetabular components	All uncemented acetabular components	Threaded uncemented acetabular components
Sensitivity (%)	76	67	95	100	86	87
Specificity (%)	43	50	71	50	36	0
Positive predictive value (%)	67	83	83	88	67	76
Negative predictive value (%)	55	29	91	100	63	0
Diagnostic accuracy (%)	63	63	86	89	66	68

\*MAL, MA or AL in Table 6.

**TABLE 8**  
Results of Nuclear Arthrography and Radiographic Arthrography Compared with Surgical Findings for 76 Cemented Femoral Components

Segment with contrast agent	NA		RGA	
	Loose	Not loose	Loose	Not loose
Tip	33	1	18	—
PD	12	4	19	8
P	2	11	6	5
None	2	11	6	14

Tip = tip of femoral component; P = proximal; D = distal.

**TABLE 9**  
Analysis of Diagnostic Procedures in 76 Cemented Femoral Components for Contrast Leakage Visualized in Distal Segment\* for Both Nuclear Arthrography and Radiographic Arthrography

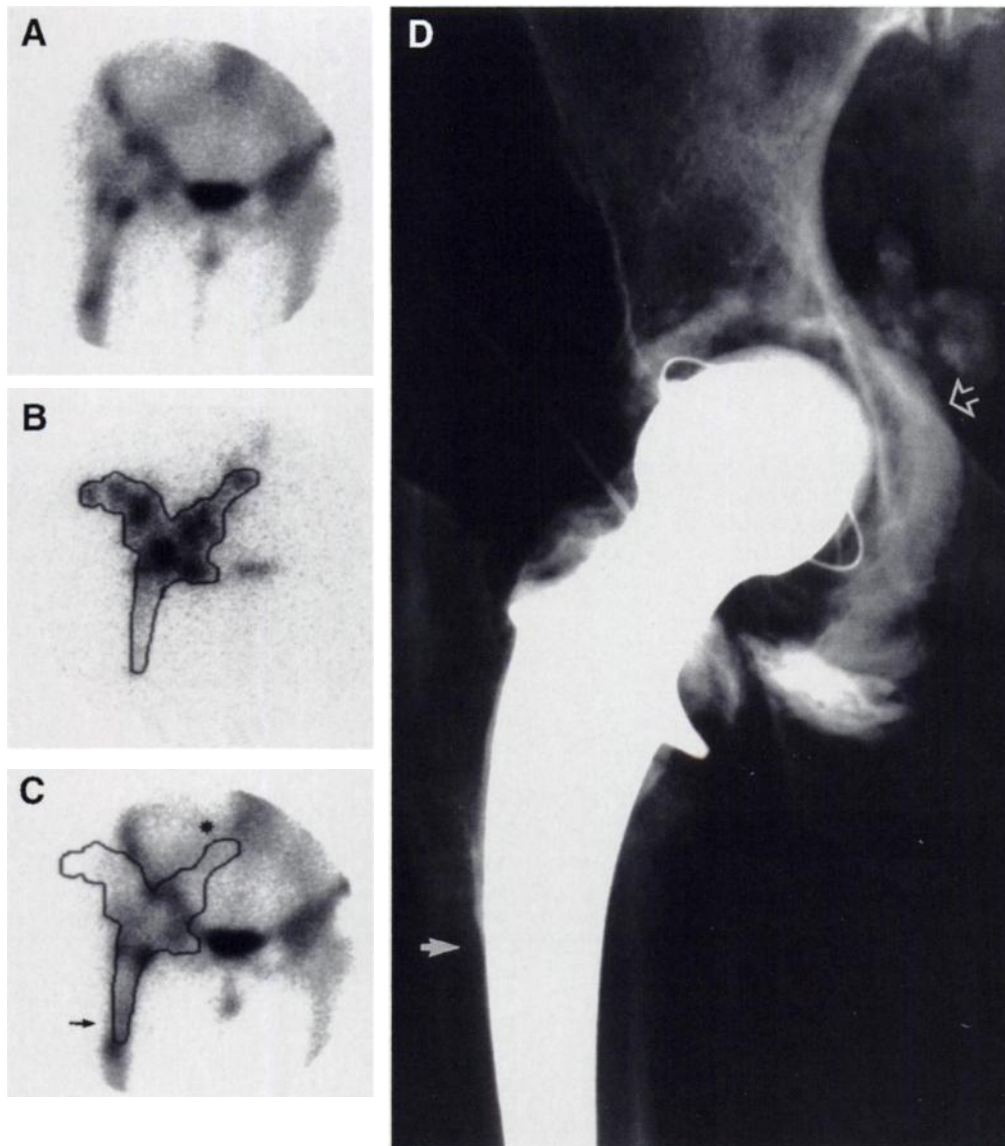
	Bone scan	NA	RGA
Sensitivity (%)	80	92	76
Specificity (%)	74	81	70
Positive predictive value (%)	85	90	82
Negative predictive value (%)	67	85	61
Diagnostic accuracy (%)	78	88	74

\*Tip or PD in Table 8.

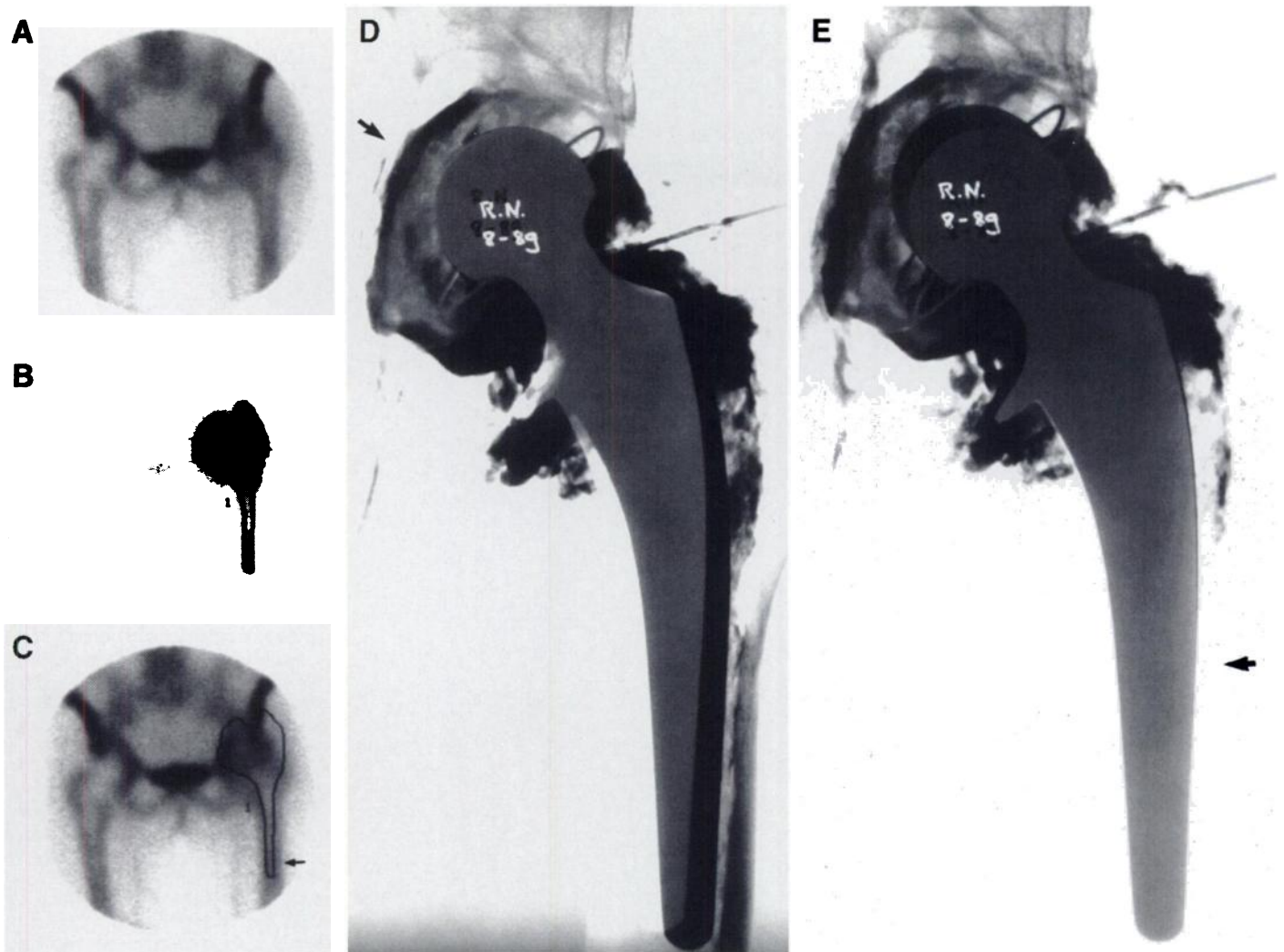
statistically significant, these findings indicate that bone scan alone is neither as sensitive nor as specific as nuclear arthrography. As indicated by Table 9, however, bone scan results are very similar to those for radiographic arthrography.

*Uncemented Femoral Component.* Tables 10 and 11 show the surgically confirmed results of radiographic arthrography and nuclear arthrography for uncemented femoral components (n =

31). In contrast to cemented femoral components, diagnostic accuracy in this group appeared not to be influenced by confining the loosening criterion to either contrast leakage in the distal segment at least (Tip or PD in Table 10) or to contrast leakage all the way down to the tip of the prosthesis (Tip in Table 10). Specificity was relatively low with the first criterion, and sensitivity for detection of loosening decreased consider-



**FIGURE 2.** Images from a 55-yr-old man with loosening of both components of a cemented prosthesis 8 yr after primary joint replacement. (A–C) Nuclear arthrographic images showing loosening of both. (A) Anterior bone scan showing moderately increased uptake around the acetabulum, in the intertrochanteric region and at the tip of the prosthesis. (B) Indium-111 colloid image with region of interest shown. (C) Indium-111 region projected in the bone scan: leakage to the tip of the femoral component (arrow) and around the acetabular component. Note leakage in the pelvic soft tissues (asterisk). (D) Radiographic arthrographic image after 10 ml of contrast agent showing leakage around the acetabular component (open arrow) and in the lateral, distal segment of the femoral component (solid arrow), indicating loosening of both components.



**FIGURE 3.** Images from a 75-yr-old woman with loosening of both components of the left cemented prosthesis 12 yr after primary hip joint replacement. Asymptomatic right prosthesis. (A–C) Nuclear arthrographic images showing loosening of both components. (A) Anterior bone scan showing moderately increased intertrochanteric uptake. (B) Indium-111-colloid image showing region of interest. (C) Indium-111 region projected in the bone scan showing leakage to the tip of the femoral component (arrow) and around the acetabular component. (D and E) Subtraction radiographs. After 40 ml of contrast agent, leakage is seen around the whole acetabular component (arrow) (D) and in the lateral, distal segment of the femoral component (arrow) (E), indicating loosening of both components.

ably with the second. When the presence of any contrast leakage was defined as loosening, specificity decreased significantly.

Bone scanning alone showed elevated periprosthetic uptake in 22 patients, 14 of whom had a loose femoral component at surgery. Fourteen patients had activity at the tip only, 9 of those were surgically loose. Eight patients had more diffusely elevated uptake, including three with an infected prosthesis. In three of nine patients with normal scan results, the femoral component had surgically loosened. These results again show the low specificity of bone scan compared with the other diagnostic procedures.

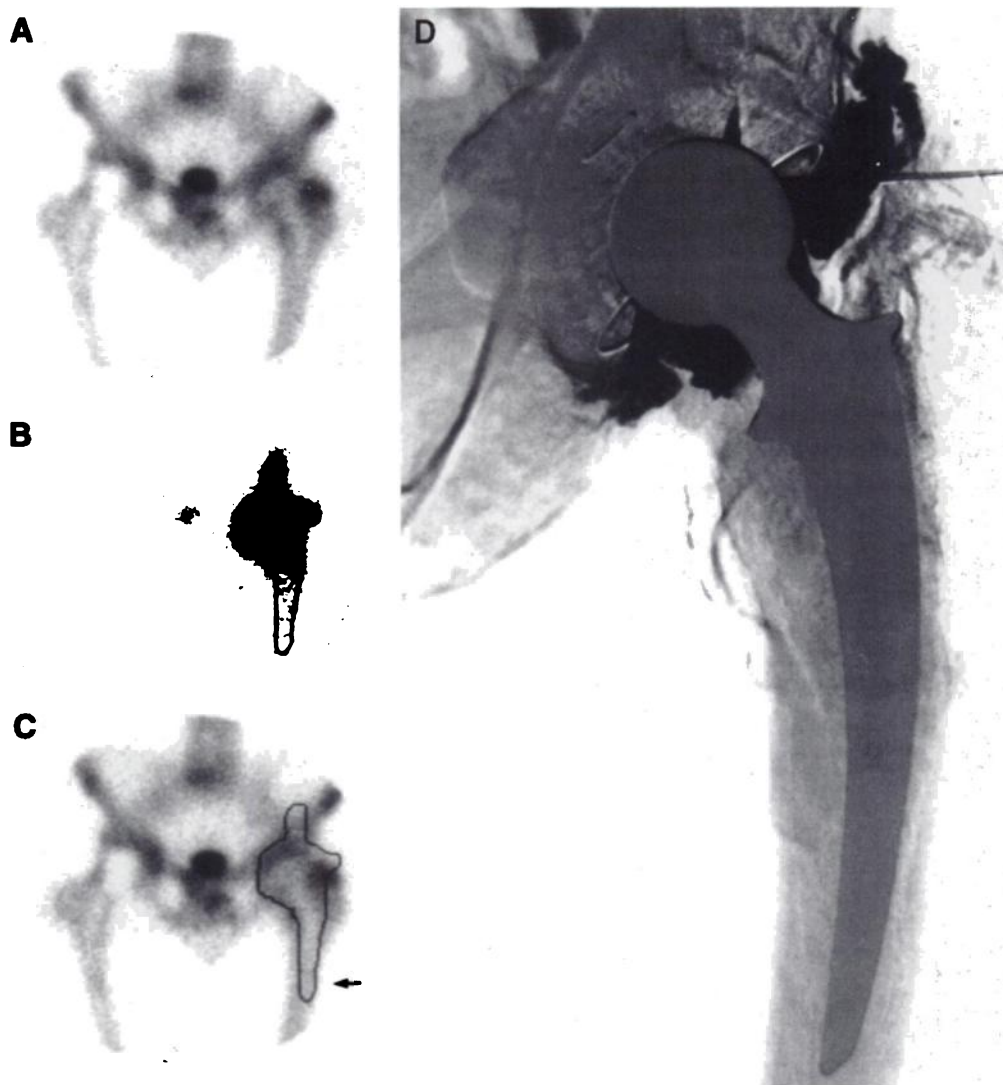
#### Trochanteric Bursa

The diagnostic results were reanalyzed for patients with filling of the bursae in the major trochanteric region during radiographic arthrography. Because filling of a bursa necessitates the use of large amounts of radiographic contrast agents which can prevent intracapsular pressure buildup, the filled bursae may theoretically decrease sensitivity for detection of contrast leakage. Filling of a bursa in the major trochanteric region was observed in 13 patients (12.1%) (both acetabular and

femoral components: eight cemented, five uncemented; acetabulum: nine loose; femoral: six loose). Table 12 summarizes the results of nuclear arthrography and radiographic arthrography. Nuclear arthrography was 100% accurate in this subgroup of patients. In contrast, both for the acetabular and for the femoral component in particular, sensitivity of radiographic arthrography decreased to 56% and 33%, respectively. The diagnostic accuracy of nuclear arthrography compared with radiographic arthrography was marginally better for the acetabular component ( $p < 0.10$ ) but significantly better for the femoral component ( $p < 0.05$ ).

#### DISCUSSION

In general, the diagnostic accuracy of nuclear arthrography is better than that of radiographic arthrography with regard to evaluation of both the acetabular and femoral components. Both procedures, however, have limitations in the interpretation of the acetabular component. Although the positive predictive values for both nuclear arthrography and radiographic arthrography are good ( $>80\%$ ), specificity is low for the cemented acetabular prosthesis. This observation differs from data from



**FIGURE 4.** Images from a 65-yr-old man with loosening of both components of the left cemented prosthesis 6 yr after revision surgery. Asymptomatic right prosthesis. (A-C) Nuclear arthrography showing loosening of both components. (A) Anterior bone scan showing moderately increased uptake around the acetabulum with normal femoral uptake. (B) Indium-111-colloid image showing region of interest. (C) Indium-111 region projected in the bone scan showing leakage to the tip of the femoral component (arrow) and around the acetabular component. (D) Subtraction radiograph after 20 ml of contrast agent showing no contrast leakage, resulting in false-negative study results.

another study (10) in a small group of patients with mainly cemented prostheses where both procedures were accurate. Other studies (8) also report diagnostic problems using radiographic arthrography in the acetabular region. One might consider tightening the diagnostic criteria for loosening in cemented acetabular grafts (e.g., adapting only medial [M], axial [A] and lateral [L] leakage as loose compared with MAL, AL and MA leakage in the present evaluation). This change would almost certainly lead to an improvement in specificity to

approximately 50%. Sensitivity and accuracy, however, would decrease to unacceptably low levels (~60%). One can only speculate about the cause of low specificity or overreading of the images. One explanation might be the spherical shape, which needs only little cement fixation.

The results of nuclear arthrography for uncemented and especially threaded acetabula are much more acceptable, with accuracies of 86% and 89%, respectively. The results for radiographic arthrography were similar in this group, as well as

**TABLE 10**

Results of Nuclear Arthrography and Radiographic Arthrography Compared with Surgical Findings for 31 Uncemented Femoral Components

Segment with contrast agent	NA		RGA	
	Loose	Not loose	Loose	Not loose
Tip	7	4	3	—
PD	4	—	7	5
P	3	5	3	2
None	3	5	4	7

Tip = tip of femoral component; P = proximal; D = distal.

**TABLE 11**

Analysis of Diagnostic Procedures in 31 Uncemented Femoral Components for Contrast Leakage Visualized in Distal Segment\* for Both Nuclear Arthrography and Radiographic Arthrography

	Bone scan	NA	RGA
Sensitivity (%)	82	65	59
Specificity (%)	43	71	64
Positive predictive value (%)	64	73	67
Negative predictive value (%)	67	63	56
Diagnostic accuracy (%)	65	68	61

\*Tip or PD in Table 10.

TABLE 12

Results of Nuclear Arthrography and Radiographic Arthrography Compared with Surgical Findings for 13 Patients with Filled Bursae in the Major Trochanteric Region

Segment with contrast agent	NA		RGA	
	Loose	Not loose	Loose	Not loose
<b>Acetabular component</b>				
MAL	7	—	5	—
MA	2	—	—	—
AL	—	—	—	—
M	—	2	1	2
L	—	—	—	1
None	—	2	3	1
<b>Femoral component</b>				
Tip	3	—	—	—
PD	3	—	2	1
P	—	4	1	2
None	—	3	3	4

M = medial; A = axial; L = lateral; Tip = tip of femoral component; P = proximal; D = distal.

in the group with cemented acetabula, especially because of its poor performance in ruling out threaded-cup loosening. In studies of intra-articular  $^{111}\text{In}$  and bone scan superposition, several investigators did not evaluate the acetabulum (4,5,11). Nuclear arthrography was not considered useful for detecting acetabular loosening when  $^{99\text{m}}\text{Tc}$ -sulfur colloid was used as the nuclidic contrast agent (6,12). Anatomic reference for  $^{99\text{m}}\text{Tc}$ -colloid leakage can be obtained by recording a transmission image with a  $^{57}\text{Co}$  flood source, but for the femoral component only (13).

Nuclear arthrography performed better in detecting femoral loosening, in agreement with published reports (4–6,10–12). In patients with femoral loosening, the sensitivity of both nuclear arthrography and radiographic arthrography is surprisingly low in those with uncemented femoral components (65% and 59%, respectively). Accurate intraoperative assessment of loosening might have been one reason for this finding (5). Other reasons might be the formation of fibrous tissue around the prosthesis or the press fit, hampering contrast leakage (1,14).

There are several possible reasons for the relatively better performance of nuclear arthrography:

1. Radionuclidic contrast agents have the advantage of intrinsically high detection sensitivity but interfaces that do not interfere with image interpretation (4).
2. Whereas subtraction radiographic arthrography is only possible from one angle, the possibility of obtaining four views of superposition images with nuclear arthrography amplifies the likelihood for detection of contrast agent.
3. With nuclear arthrography the patient performs weight-bearing activity, such as walking before scintigraphic imaging, thereby dramatically increasing the intracapsular pressure (7,15).

This latter factor is emphasized by our findings in the group of patients with trochanteric bursae. Radiographic arthrography identified only about 50% of the loose components because the radiologist could not induce an increase in intracapsular pressure. In these patients, walking before nuclear arthrography is particularly advantageous for the outcome of this diagnostic tool. For radiographic arthrography, adequate subtraction is

considered the key procedure, along with preventing the introduction of any patient movement.

The use of  $^{111}\text{In}$ -colloid is a modification of the  $^{111}\text{In}$  radionuclide contrast agents used by others, such as  $^{111}\text{In}$ -chloride and  $^{111}\text{In}$ -DTPA (4,5,10,11). The advantage of this radiopharmaceutical is its near insolubility over at least 2 hr, which allowed us to image the total intra-articularly injected dose without any unpredictable resorption phenomena. The amount of  $^{111}\text{In}$  could be minimized to approximately 5 MBq per patient.

When increased  $^{99\text{m}}\text{Tc}$ -MDP activity was seen only at the tip of the femoral component, it indicated loosening in 75% of patients that was of septic origin in none. Infection was always depicted as more diffusely increased uptake in the femur. When bone scintigraphy was compared with nuclear arthrography with  $^{99\text{m}}\text{Tc}$ -MDP imaging alone, both specificity and sensitivity of bone scintigraphy were relatively low. This finding not only applied to the detection of acetabular loosening (sensitivity ~75%), but to femoral loosening as well (sensitivity ~80%), in concert with the observations of Wellman et al. (4). In contrast, other studies (3,16) recommend skeletal scintigraphy as the key procedure in the diagnostic strategy for painful total hip replacements. The use of a pinhole collimator may improve image quality for more accurate assessment.

Some observations in the group of patients with revised prostheses merit additional comments: (a) The lifespan of a revised prosthesis is significantly shorter than a primary prosthesis (3.9 versus 7.4 yr, respectively), confirming published reports (1). (b) It appears that relatively more intraoperatively obtained culture results are positive in patients with a revised prosthesis (7 [21%] of 33) than in those with a primary prosthesis (9 [12%] of 12). This difference, however, is not statistically significant.

## CONCLUSION

Nuclear arthrography is a useful and simple additional diagnostic technique with added value over bone scanning alone for the assessment of total hip prosthesis loosening. Moreover, nuclear arthrography offers improved diagnostic accuracy for the femoral component compared with radiographic arthrography. When logistic procedures are accurately organized, nuclear arthrography provides no additional discomfort to the patient than radiographic arthrography and bone scanning alone, two tests that are already in routine use. It should be stressed, however, that nuclear arthrography can only be performed correctly when done in conjunction with radiographic arthrography, not only for fluoroscopic guidance of the puncture, but also for appreciation of anatomic details, such as migration of the prosthesis, bone resorption, fractures, fissures and fistulae.

## REFERENCES

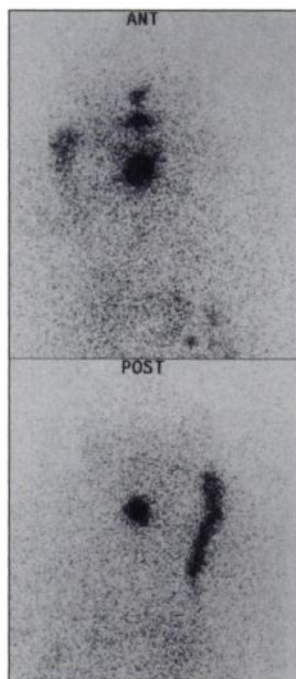
1. Harris WH, Sledge CB. Total hip and total knee replacement. *N Engl J Med* 1990;323:725–731.
2. Dobbs HS. Survivorship of total hip replacements. *J Bone Joint Surg [Br]* 1980;62:168–174.
3. Tehranzadeh J, Schneider R, Freiburger RH. Radiological evaluation of painful total hip replacement. *Radiology* 1981;141:355–362.
4. Wellman HN, Schauwecker DS, Capello WN. Evaluation of metallic osseous implants with nuclear medicine. *Semin Nucl Med* 1988;18:126–136.
5. Swan JS, Braunstein EM, Wellman HN, et al. Contrast and nuclear arthrography in loosening of the uncemented hip prosthesis. *Skeletal Radiol* 1991;20:15–19.
6. Miniaci A, Bailey WH, Bourne RB, et al. Analysis of radionuclide arthrograms, radiographic arthrograms, and sequential plain radiographs in the assessment of painful hip arthroplasty. *J Arthroplasty* 1990;5:143–149.
7. Barentsz JO, Lemmens JAM, Slooff TJH. The use of subtraction arthrography in total hip arthroplasties. *Fortschr GebRoentgenstr Nuklearmed* 1986;144:440–446.
8. Hendrix RW, Anderson TM. Arthrographic and radiologic evaluation of prosthetic joints. *Radiol Clin N Am* 1981;19:349–364.



9. Williamson BR, McLaughlin RE, Wang GW, et al. Radionuclide bone imaging as a means of differentiating loosening and infection in patients with a painful total hip prosthesis. *Radiology* 1979;133:723-725.
10. Maxon HR, Schneider HJ, Hopson CN, et al. A comparative study of indium-111 DTPA radionuclide and iothalamate meglumine roentgenographic arthrography in the evaluation of painful total hip arthroplasty. *Clin Orthop* 1989;156-159.
11. Capello WN, Uri BG, Wellman HN, Robb JA, Stiver PL. Comparison of radiographic and radionuclide hip arthrography in determination of femoral component loosening of hip arthroplasties. In: Fitzgerald RH Jr, ed. *The hip*. Mosby: St. Louis; 1985:157-168.
12. Resnik CS, Fratkin MJ, Cardea JA. Arthroscintigraphic evaluation of the painful total hip prosthesis. *Clin Nucl Med* 1986;11:242-244.
13. Hayes AA, Bower GD. Radionuclide arthrography and transmission imaging for assessment of painful hip prostheses. *J Nucl Med* 1994;35:851-854.
14. Lette J, Eybalin MA, Roy A, et al. Bone imaging after cementless press fit total hip arthroplasty. *Clin Nucl Med* 1989;14:614-622.
15. Hendrix RW, Wixson RL, Rana NA, et al. Arthrography after total hip arthroplasty: a modified technique used in the diagnosis of pain. *Radiology* 1983;148:647-652.
16. Weiss PE, Mall JC, Hoffer PB, et al. Technetium-99m-methylene diphosphonate imaging in the evaluation of total hip prostheses. *Radiology* 1979;133:727-729.

## FIRST IMPRESSIONS

An 80-yr-old woman underwent whole-body imaging 72 hr after a therapeutic dose of  $^{131}\text{I}$ . Why was the tracer visualized in a linear area of abnormal activity on the lateral aspect of the neck?  
For acquisition information, turn to page 75.



**Figure 1.**