

CASE REPORT

Cerebral Venous Angioma: Correlation of Radionuclide Brain Scan, Transmission Computed Tomography, And Angiography

C. Leon Partain, Faustino C. Guinto, James H. Scatliff, John Limbacher, Paul Janicki, and C. Craig Heindel

University of North Carolina, Chapel Hill, North Carolina, University of Texas, San Antonio, Texas and Kingsport, Tennessee

Three cases of intracerebral venous angioma, a rare vascular malformation, were studied by radionuclide brain scan, transmission computed tomography (TCT) and angiography. In each case, the radionuclide flow study demonstrated a typical area of abnormal increase in activity during the venous phase; in two of the cases the arterial phase was also abnormal. Each contrast angiogram demonstrated a normal arterial distribution and a characteristic network of abnormal veins that converged to a large transcerebral draining vein. The TCT scans showed enhancing, curvilinear densities; while not specific, this finding should suggest the possibility of venous angioma in the brain.

J Nucl Med 20: 1166-1169, 1979

Cerebral venous angioma is the rarest vascular malformation of the brain. Angiographic demonstration of this lesion was first reported in 1967 (1). Since then, angiographic findings have been presented in five additional cases (2-5). More recently, three other cases have been evaluated, comparing radionuclide flow studies and contrast angiography (6). Six cases were added to the literature in 1977, with a comparison of transmission computed tomography (TCT) and angiography (7). Another case compared radionuclide and contrast angiography (8). Four cases comparing TCT and angiography have been published (9). Hence, a total of only 20 venous angiomas of the brain have been studied; each case presented angiography, or angiography with TCT, or angiography with the dynamic brain scan. The purpose of this report is to add three new cases, correlating radionuclide brain scan, TCT, and angiography.

CASE REPORTS

Case 1. A 32-year-old white female nurse was admitted with a recent history of seizure, fall, and fracture of the shoulder. One seizure episode was experienced 11 yr before admission. Subsequently she had abnormal EEGs over a 2-yr period, but when treated with primidone her EEG reverted to normal. There followed an asymptomatic period. A third seizure was observed in the emergency room. She denied headaches, except during menstrual periods. She denied difficulty with speech, vision, or swal-

lowing. She had no tinnitus, vertigo, scotomata, diplopia, incontinence, or difficulty in movement or strength.

She was not on medication at the time of admission. Physical examination was unremarkable except for increased reflexes in the lower extremities.

Skull films were negative. A radionuclide brain-flow study showed abnormal activity in the left hemisphere during the venous phase (Fig. 1A). The unenhanced TCT of the head was not helpful, but with enhancement a well-defined, linear enhancing lesion appeared in the left frontal lobe (Fig. 1B). Bilateral carotid angiography revealed normal vasculature of the right hemisphere and normal arterial supply to the left. In the venous phase, however, an abnormal tuft of vessels with a large transcerebral draining vein was demonstrated in the left frontal lobe (Figs. 1C,D).

The patient was discharged without surgery. She received seizure medication and was scheduled for follow-up examination.

Case 2. A 59-year-old white woman was admitted for evaluation of left trigeminal neuralgia. The patient had a 2-3-yr history of sensory abnormality starting over the left frontal area and progressing into the hairline. These sensory deficits were followed by fasciculation of the left upper eyelid. Later, the area around the left side of her mouth became numb. These episodes were generally not accompanied by pain. Physical activity seemed to exacerbate the fluttering of her eyelid. She had a tendency to slur or mumble words during these attacks. She denied recent head trauma and had no history of diabetes, atherosclerotic vascular disease, or hypertension. She complained of some malaise and nausea in the past.

On physical examination, a slight drooping of the left upper eyelid was observed without change in facial expression. Cranial nerves were normal except for decreased sensation in the ophthalmic and maxillary distributions of the left trigeminal nerve.

Received March 2, 1979; revision accepted May 1, 1979.

For reprints contact: C. Leon Partain, Imaging Division, Dept. of Radiology, University of North Carolina, Chapel Hill, NC 27514.

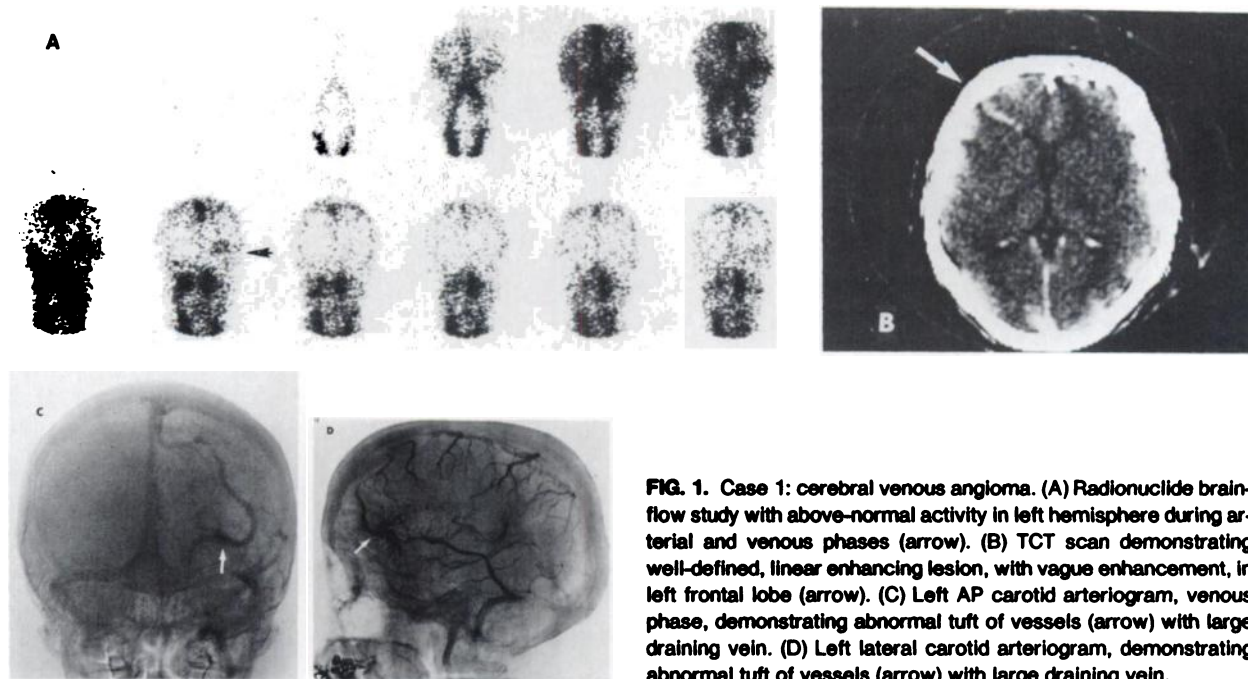


FIG. 1. Case 1: cerebral venous angioma. (A) Radionuclide brain-flow study with above-normal activity in left hemisphere during arterial and venous phases (arrow). (B) TCT scan demonstrating well-defined, linear enhancing lesion, with vague enhancement, in left frontal lobe (arrow). (C) Left AP carotid arteriogram, venous phase, demonstrating abnormal tuft of vessels (arrow) with large draining vein. (D) Left lateral carotid arteriogram, demonstrating abnormal tuft of vessels (arrow) with large draining vein.

A radionuclide brain flow study revealed an abnormal area of increased activity in the left hemisphere during the venous phase (Fig. 2A). TCT of the head, with contrast enhancement, revealed two well-defined enhancing lesions in the left temporal region (Fig. 2B). Angiography showed two areas of abnormal venous structures accompanied by large draining veins in the left temporal lobe (Figs.

2C,D). Arterial distribution to the left hemisphere was within normal limits.

No surgery was performed and the patient was scheduled for follow-up examination.

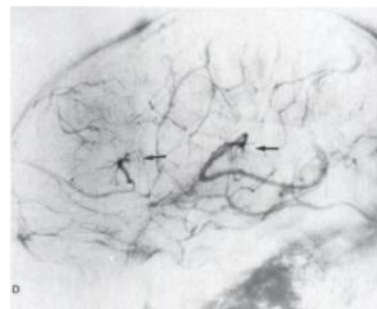
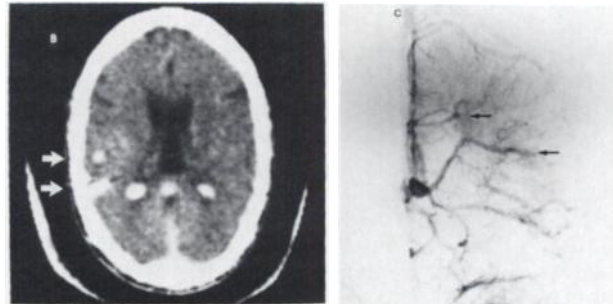
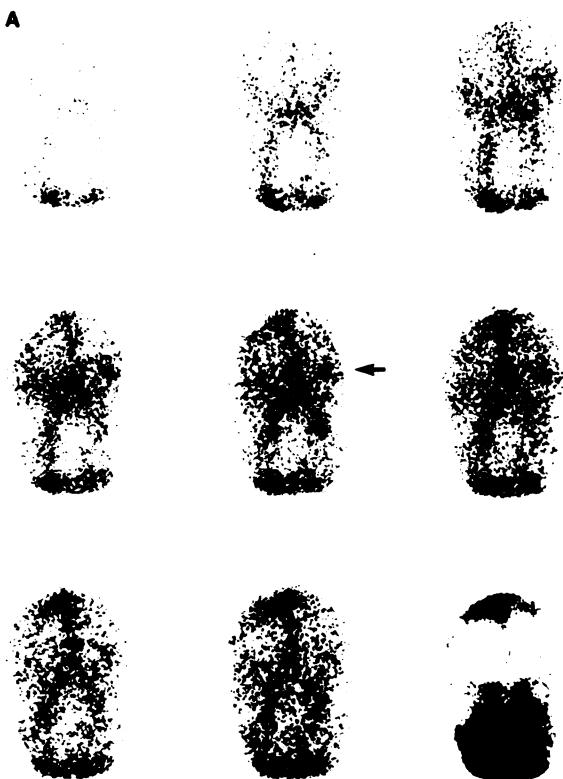


FIG. 2. Case 2: cerebral venous angioma. (A) Radionuclide brain-flow study with above-normal activity in left hemisphere during arterial and venous phases (arrow). (B) TCT scan demonstrating two well-defined enhancing lesions in left temporal region (arrow). (C) Left AP carotid angiogram, venous phase, demonstrates two areas of abnormal venous structures (arrows), accompanied by large draining veins, in left temporal lobe. (D) Left lateral carotid angiogram, venous phase, demonstrates two areas of abnormal venous structures (arrows), accompanied by large draining veins, in left temporal lobe.

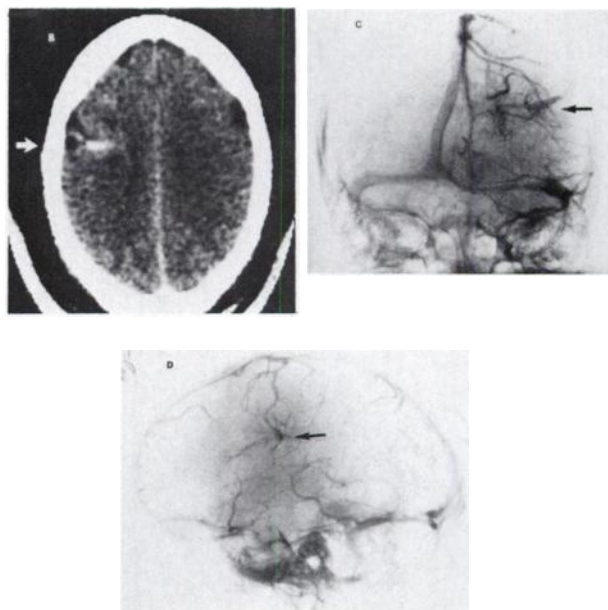
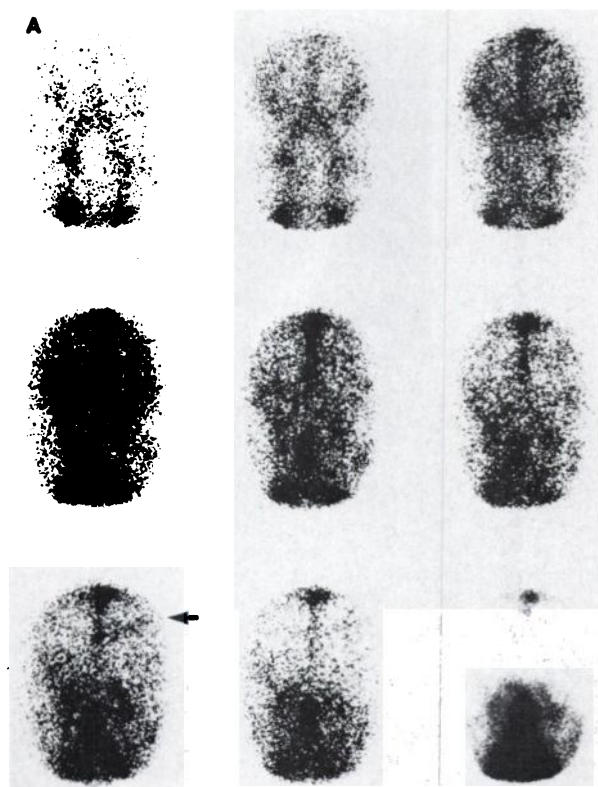


FIG. 3. Case 3: cerebral venous angioma. (A) Radionuclide brain-flow study with above-normal activity in left mid-hemisphere in capillary and venous phases (arrow). (B) TCT scan demonstrating well-defined enhancing lesion in deep left frontal region (arrow). (C) Left AP carotid arteriogram, venous phase, demonstrating abnormal tuft of venous vessels (arrow), with large draining vein, deep in left frontal area. (D) Left lateral carotid arteriogram, venous phase, demonstrating abnormal tuft of venous vessels (arrow), with large draining vein, deep in left frontal area.

Case 3. A 63-year-old white man was admitted to the hospital for evaluation of low back pain. An enlarged prostate gland and elevated acid phosphatase levels were noted. Neurologic examination was normal.

Because of persistent headache, a radionuclide brain scan was performed. The flow study revealed an abnormal area of increased uptake in the left mid-hemisphere in the venous phase (Fig. 3A). TCT scan demonstrated a well-defined, enhancing lesion in the same area, consistent with vascular malformation (Fig. 3B). Angiography demonstrated a deep, left frontal venous angioma (Figs. 3C,D).

The patient was not treated surgically for the intracerebral venous angioma. A prostatic biopsy was normal. On follow-up examination his condition remained unchanged.

A summary of clinical presentation for these three patients, with results of imaging studies and treatment, is presented in Table 1.

DISCUSSION

Vascular malformations of the central nervous system have been classified into four basic categories: capillary telangiectasia, cavernous angioma, arteriovenous malformation, and venous angioma (10), the last being the rarest type. Histologically, the lesion is characterized by many irregular and dilated venous channels. Smooth muscle or connective tissue is found in the walls of these vessels, but no elastic tissue. Both grossly and microscopically, a venous malformation resembles an arteriovenous malformation, except that arteries are absent. In contrast to the cavernous angioma, the dilated vessels in venous angioma are separated by neural tissue.

Vascular malformations of the brain are congenital anomalies (6). The term "angioma" is widely used, but is not strictly correct because these lesions show no evidence of cellular proliferation and therefore are not true neoplasms. On the other hand, they do resemble neoplasms in their clinical behavior since they may grow and inflict progressive destruction on the adjacent brain.

Radionuclide brain scanning strongly suggests a vascular malformation where the initial flow study shows an abnormal area of increased activity followed by normal, delayed static images (8). Documented cerebral venous angiomas have shown vascular abnormalities during the arterial phase of the radionuclide flow study, as well as in the venous phase (6). Hence, the brain scan is a sensitive test for detecting vascular malformations, including venous angiomas, but it is insufficiently specific to differentiate between the various types of anomaly. If significant symptoms are present and surgical intervention is a reasonable treatment option, a brain scan positive for vascular malformation should be followed by cerebral angiography. Thus, definitive diagnosis and identification of the type of vascular anomaly are provided before surgery. In this situation, a TCT scan is unnecessary.

However, most patients with significant neurological symptoms are likely to be screened by TCT scan of the head. In TCT scans of a cerebral venous angioma, the unenhanced study is typically normal, whereas the enhanced study will demonstrate a well-defined, linear enhancing lesion that represents the large transcerebral vein. This is a characteristic angiographic feature of this entity. In addition, TCT is likely to demonstrate associated hematomas very well. In the past, the next study has usually been cerebral angiography. However, if cerebral venous angioma is suspected and if symptoms are relatively mild, a radionuclide brain-flow study may support the diagnostic suspicion, and thus justify the need for angiography.

Angiography remains indicated for confirmation of the diagnosis of cerebral venous angioma, especially when surgical treatment is contemplated. The angiographic diagnostic criteria include the following:

1. Multiple small veins, arising at the periphery of a deep lesion, which converge centrally into a much larger transcerebral vein. It courses to reach a cortical surface, where it empties into larger

TABLE 1. SUMMARY OF FINDINGS IN THREE CASES OF CEREBRAL VENOUS ANGIOMA

| | Cases | | |
|--------------------------|--------------------------------------|--|--------------------------------------|
| | 1 | 2 | 3 |
| 1. Age (yr) | 32 | 59 | 63 |
| 2. Sex | Female | Female | Male |
| 3. Clinical presentation | Seizures | Left trigeminal neuralgia, slurred speech, malaise, nausea | Headache |
| 4. Dynamic scintigraphy | | | |
| a. arterial phase | + | + | - |
| b. venous phase | + | + | + |
| 5. Static scintigraphy | - | - | - |
| 6. Unenhanced TCT | - | - | - |
| 7. Enhanced TCT | + | + | + |
| 8. Angiography | 1 venous angioma, transcerebral vein | 2 venous angiomas, transcerebral vein | 1 venous angioma, transcerebral vein |
| 9. Location | Left frontal | Left temporal | Left frontal |
| 10. Treatment | Medical | Medical | Medical |

cortical veins or a dural sinus (6). Alternatively, the large transcerebral vein may drain into a subependymal vein in the wall of a lateral ventricle (2).

2. Opacification of the venous network may occur early in the arterial or capillary phase (6). In the three cases reported here, the arterial and capillary phases of the arteriogram were normal.

3. The large transcerebral vein typically remains opacified through the late venous phase.

4. No vascular displacement is seen unless the malformation bleeds into the substance of the brain.

The above criteria are quite different from those for the more common arteriovenous malformations, where grossly enlarged arteries supply the lesion and the venous drainage is typically more rapid, through multiple venous channels arising and draining peripherally (6).

The radionuclide flow study is a useful screening test for suspected cerebral vascular malformation. The abnormal flow pattern in venous angioma is generally the same as the pattern in arteriovenous malformation. The differential diagnosis should include cerebral venous angioma for any patient with a normal unenhanced TCT study and a demonstration of a well-defined, linear enhancing lesion on the enhanced TCT scan.

ACKNOWLEDGMENTS

The authors express their appreciation to DeLois Popp and Margery Westray for their assistance in preparing this manuscript, and to Robert Strain for photographic assistance.

REFERENCES

1. WOLF PA, ROSMAN NP, NEW PFJ: Multiple small cryptic venous angiomas of the brain mimicking cerebral metastases. A clinical, pathological, and angiographic study. *Neurology* 17: 491-501, 1967
2. CONSTANS JP, DILENGE D, VEDRENNE CL: Angiomes veineux cerebraux. *Neuro-chirurgie* 14: 641-650, 1968
3. HEINZ ER: Pathology involving the supratentorial veins and dural sinuses. In *Radiology of the Skull and Brain*, Newton TH, Potts DG, eds. St. Louis, C. V. Mosby, 1974, pp 1878-1902
4. HEINZ ER, HARDMAN DR: Current problems in neuroradiology. *Current Problems Radiology* 4: No. 5, 1-48, 1974
5. SCOTTI LN, GOLDMAN RL, RAO GR, et al: Cerebral venous angioma. *Neuroradiology* 9: 125-128, 1975
6. WENDLING LR, MOORE JS, KIEFFER SA, et al: Intracerebral venous angioma. *Radiology* 119: 141-147, 1976
7. MICHELS LG, BENTSON JR, WINTER J: Computed tomography of cerebral venous angiomas. *J. Comput Assist Tomogr* 1: 149-154, 1977
8. PREISSIG RS, PREISSIG SH, GOREE JA: Angiographic demonstration of a cerebral venous angioma. *J. Neurosurg* 44: 628-631, 1976
9. MAEHARA T, TASAKA A: Cerebral venous angioma: Computerized tomography and angiographic diagnosis. *Neuroradiology* 16: 296-298, 1978
10. RUSSELL DS, RUBINSTEIN LJ: *Pathology of Tumors of the Nervous System*, 3rd edition. Baltimore, Williams & Wilkins, 1971, pp 85-108