

**Ultrasonography of the Testis—Correlation with  
Radiotracer Perfusion**

M. A. Winston, S. J. Handler, and J. H. Pritchard

*Veterans Administration Wadsworth Hospital Center and University of  
California at Los Angeles, Los Angeles, California*

*Ultrasonic study of testicular disease and paratesticular masses was carried out in 20 cases. In eight of these, comparison was made with pertechnetate perfusion studies performed concurrently. Testicular torsion was well revealed by both techniques. Acute orchitis, in the early stages, was shown more clearly by radiotracer, unless there was associated epididymal swelling or hydrocele. Chronic complications of inflammation, particularly abscess formation, were seen best by ultrasonography. Paratesticular masses could be studied only by ultrasound. These included both solid and cystic masses due to chronic epididymitis.*

**J Nucl Med 19: 615–618, 1978**

Although the testis is readily examined by simple measures such as palpation and transillumination, the diagnosis of various diseased states is not always clear. It may be anticipated that sonography would have much to add, since the organ and surrounding structures may be studied in great detail with high-frequency transducers. Several early studies employing bistable equipment have been published (1,2) and recently updated (3).

We present here the results of such studies in 20 patients, using gray-scale imaging. All cases have been followed for a minimum of 6 mo; four have had surgical or biopsy confirmation of diagnosis, and the rest have been followed to a satisfactory medical outcome. In eight instances, correlation with a radionuclide perfusion study was also available.

**METHOD**

The patients were men ranging in age from 24 to 40 yr. All were referred for examination because of either pain or a palpable scrotal mass. The ultrasonic examinations were performed with a 5-megahertz transducer having a short internal focus and a gray-scale readout\*. The patient was examined in the supine position and the scrotum was coated with a copious amount of aqueous gel; the individual testis was grasped in the hand and suspended between the

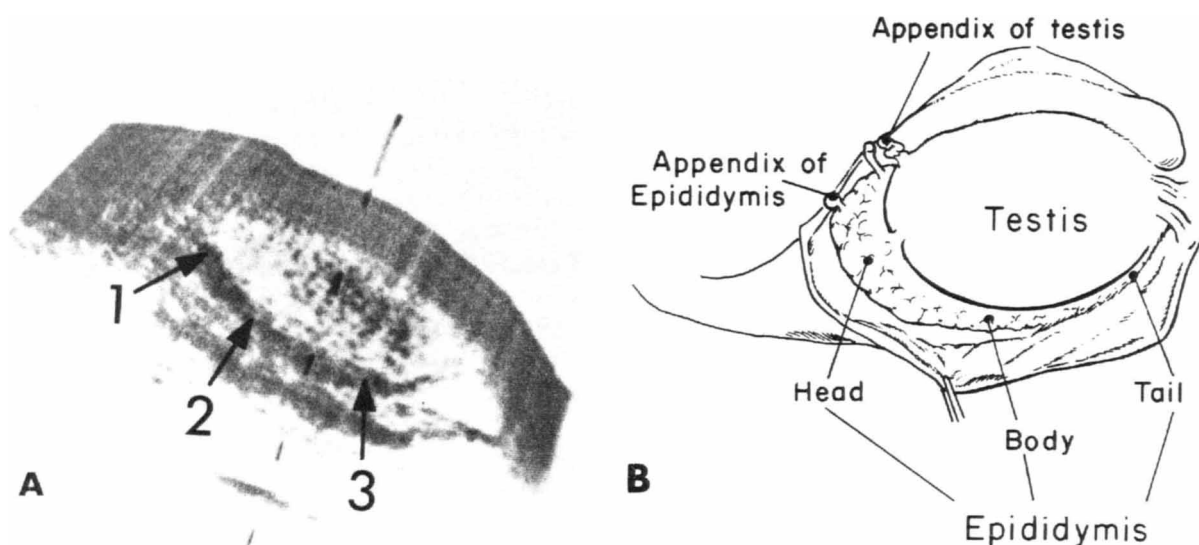
thumb and forefinger. The transducer was then passed between the fingers, and the longitudinal scan of the testis was made from the superior to the inferior pole. Multiple longitudinal scans were obtained at half-centimeter intervals. Transverse scans were attempted in certain cases, but these proved to be technically difficult. The images were recorded on standard Polaroid film. In several instances, additional views were obtained employing a hand-held oscillating 10-MHz contact probe with a real-time television display†. Radionuclide perfusion was performed by the method of Datta and Mishkin (4), employing 10 mCi [<sup>99m</sup>Tc] pertechnetate.

**RESULTS**

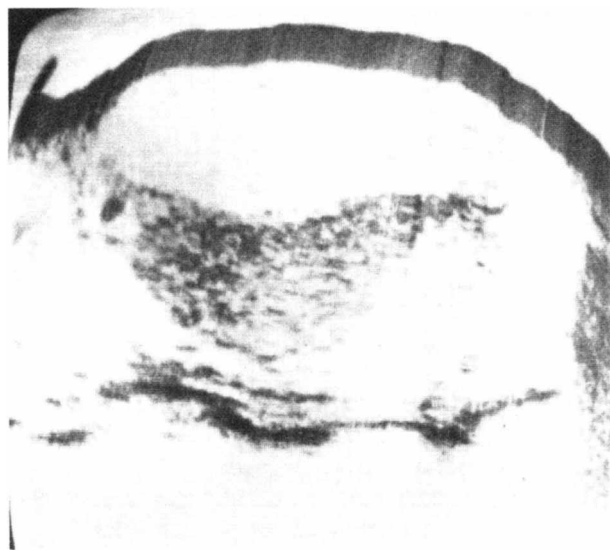
Six patients had normal studies. In two the diagnosis was resolved epididymitis; in three, referred pain; and in two others, minor palpable enlargement of the testis or cord. In two of this group, tracer perfusion studies were also obtained and were uninformative.

With gray-scale equipment, the normal testis ap-

Received Sept. 26, 1977; revision accepted Dec. 8, 1977.  
For reprints contact: M. A. Winston, Nuclear Medicine Service (691/115), VA Wadsworth Hospital Ctr., Los Angeles, CA 90073.



**FIG. 1.** (A) Normal testis, longitudinal sonogram. Upper pole is to left. Epididymis is seen behind testis. Numbers 1, 2, and 3 correspond, respectively, to head, body, tail of epididymis. (B) Diagram of testis and epididymis.



**FIG. 2.** Orchitis with purulent hydrocele. Sonogram shows scattered echoes within fluid, and compression of testicular surface by tense rapidly accumulating fluid.

appears as an oval structure with a fairly homogenous medium-gray to dark-gray internal echo pattern (Fig. 1A). The borders of the testis are usually well circumscribed and distinguishable from the surrounding structures. Various anatomy texts have reported on the normal testicular measurements, which can be measured fairly accurately from the ultrasound reproduction.

The posterolateral border of the testis contains the epididymis, which is divided into the head, body, and tail (Fig. 1B). The head is located on the superolateral aspect of the testis and can be visualized in most cases by slight internal or external rotation of

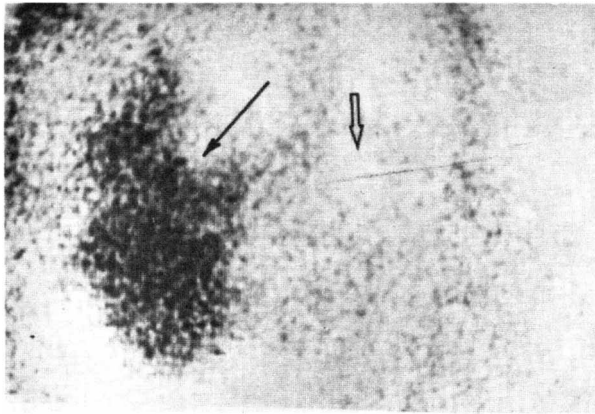
the testis as it is being examined. The body and tail region of the epididymis are slightly more difficult to visualize due to sound attenuation by the intervening testicular parenchyma. These portions of the epididymis, therefore, did not always fill in with gray tones as well as the head did. With slight internal rotation of the testis, the body and tail region are most distinct. However, as a result of these maneuvers, the normal anatomic relationship of epididymis to testis may be somewhat distorted.

Just beneath the head of the epididymis is located the appendix of the testis. This represents the remnant of the superior portion of the Müllerian duct. Occasionally this is seen on gray scale as a solitary dark echo adjacent to the epididymal head (Fig. 1B).

There were four cases of acute epididymo-orchitis. In one, which was clinically advanced, ultrasound revealed irregular cystic, partially sonolucent areas



**FIG. 3.** Epididymo-orchitis. Epididymis (arrows) appears swollen and sonolucent, but testis appears normal.



**FIG. 4.** Acute epididymo-orchitis: radionuclide perfusion study, postperfusion image. Note greatly increased activity of right testis and epididymis (solid arrow). Open arrow indicates normal testis.

within the testis containing scattered debris. In three other cases of more recent onset, the testicular consistency was relatively normal, although in one of these a sympathetic hydrocele developed. This contained scattered echoes, shown on aspiration to represent purulent matter (Fig. 2), and caused a compression deformity of the testis. In another, epididymal swelling was evident (Fig. 3). In two of this latter group of acute epididymo-orchitis, radiotracer perfusion studies were performed and demonstrated evident hypervascularity (Fig. 4).

There were three cases of acute torsion. Ultrasonography revealed an enlarged testis with a coarse echo pattern that was probably due to interstitial edema (Fig. 5A). In two of these cases, in which tracer studies were also done, the perfusion was reduced and a void in activity was particularly well seen in the postperfusion images (Fig. 5B).

Nine patients had paratesticular masses. Five were solid—all due to chronic epididymitis (Fig. 6); four were cystic: three spermatoceles (Fig. 7) and one epididymal abscess. The solid masses resulted in a variety of nonspecific echo patterns. The studies, however, were of great help in that the testis itself could clearly be seen to be uninvolved. Radionuclide

perfusion was performed in only one of these patients and was uninformative.

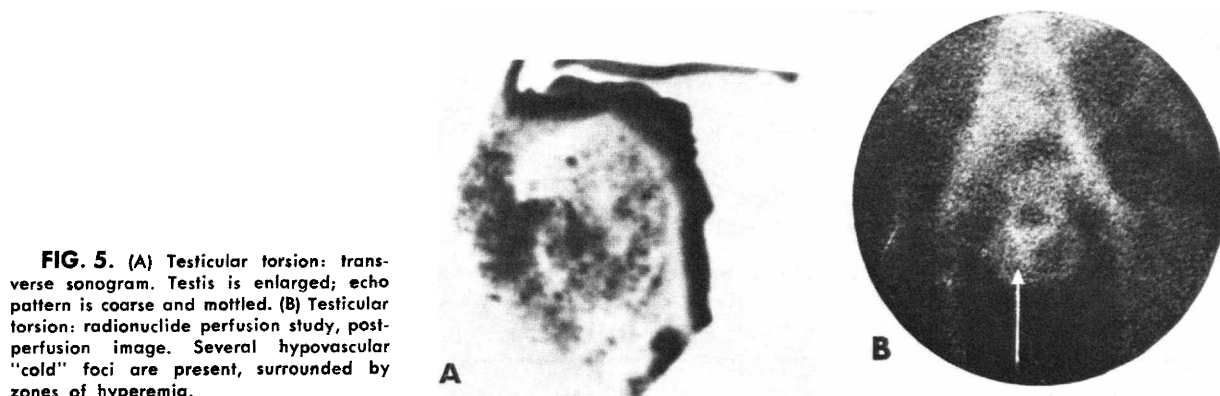
There were three cases of hydrocele and one of combined hydrocele-varicocele. Ultrasound clearly revealed the fluid, and was of interest in the varicocele because individual venous channels could be clearly demonstrated on the real-time study. The perfusion study in one case of hydrocele appeared normal.

#### DISCUSSION

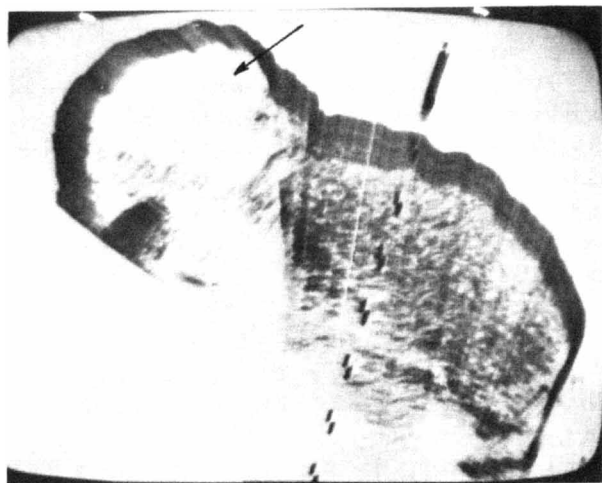Testicular ultrasonography has been a generally rewarding procedure because of its simplicity in delineating testicular and paratesticular architecture, and because of its noninvasiveness. It is weak, however, in detecting early orchitis, where there is little difference from the normal pattern. Radionuclide perfusion, which reflects functional rather than anatomic change, is more sensitive in this condition. Later in the course, when tissue breakdown and abscess formation occur, ultrasound is of more value. At this stage, in fact, a tracer study may well become misleading, since regions of abscess or necrotic tissue will appear hypo-perfused, suggesting the appearance caused by torsion.

In torsion, ultrasonic scanning shows a deviation from the normal, due to swelling and interstitial edema. Since the clinical entity most closely resembling torsion is acute orchitis, in which the testicular echo pattern is unaffected, the tracer technique appears to make differentiation possible. Whether this will prove to be a sufficiently reliable and specific finding with which to make a diagnosis could not be determined on the basis of the few cases in this series.

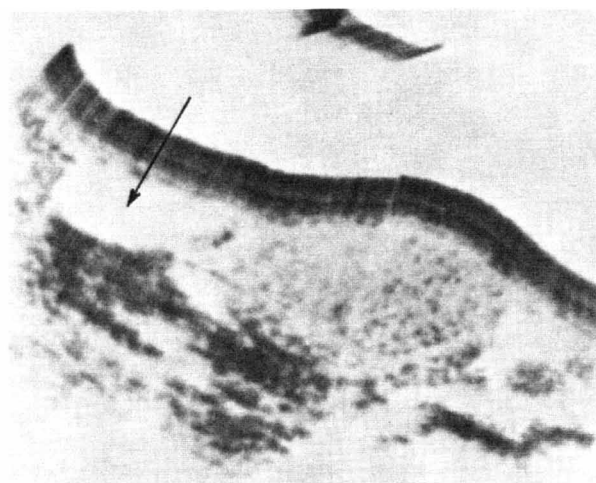
Pederson et al. have used Doppler ultrasonography to detect diminished arterial perfusion (5). Although one might postulate that reduced arterial inflow as detected by Doppler or radiotracer perfusion may be more informative in the early phase of torsion than the swelling and edema detected by sonographic scanning, we have no data yet to support or refute this supposition.



**FIG. 5.** (A) Testicular torsion: transverse sonogram. Testis is enlarged; echo pattern is coarse and mottled. (B) Testicular torsion: radionuclide perfusion study, postperfusion image. Several hypovascular "cold" foci are present, surrounded by zones of hyperemia.



**FIG. 6.** Sonogram in chronic epididymitis: hemorrhagic, fibrotic tissue at upper pole of testis.



**FIG. 7.** Sonogram of spermatocele (arrow) at upper pole of testis.

Sonography is clearly the best means of approaching paratesticular masses. As is typical of other areas, the most reliable function was to differentiate solid from cystic tissue, and to pinpoint the structure involved. Although the diagnosis of hydrocele is clinically apparent, the additional value of sonography here lies in ascertaining the condition of the underlying testis, or in finding abnormalities within the hydrocele sac, as in the case of hydrocele associated with orchitis in this series. Although we encountered no solid testicular masses in this study, the possibilities for their detection have already been documented (1).

Finally, as to the role of real-time contact scanning in this area, we found that the limited range of gray shades and field of view made interpretation more difficult in most instances. The distal surface of the testis was not well delineated owing to attenuation occurring at 10 MHz, even in so small an or-

gan. This equipment was of particular value, however, in the case of small, highly mobile paratesticular masses which would have been displaced by the typical linear scan.

FOOTNOTES

\* Picker model EDC, Cleveland, Ohio.

† Bronson-Turner.

REFERENCES

1. MISKIN M, BAIN J: B-mode ultrasonic examination of the testis. *J Clin Ultras* 2: 307-311, 1974
2. SHAKER TH: B-mode ultrasonic evaluation of scrotal swellings. *Radiology* 118: 417-419, 1976
3. MISKIN M, BUCKSPAN M, BAIN J: Ultrasonographic examination of scrotal masses. *J Urol* 117: 185-188, 1977
4. DATTA NS, MISHKIN FS: Radionuclide imaging in intrascrotal lesions. *JAMA* 231: 1060-1062, 1975
5. PEDERSON JF, HOLM HH, HAHN T: Torsion of the testis diagnosed by ultrasound. *J Urol* 113: 66-68, 1975

**NOTICE OF THE NEXT ABNM CERTIFYING EXAMINATION**

The American Board of Nuclear Medicine announces that its Seventh Certifying Examination in Nuclear Medicine will be held on Saturday, September 30th, 1978.

Applications and information are available from:

**The American Board of Nuclear Medicine, Inc.**  
**475 Park Avenue South**  
**New York, New York 10016**  
**Telephone: (212) 889-0717**

Applications should be accompanied by an application fee of \$600 and submitted by the deadline of June 1, 1978.