

DYNAMIC BLOODFLOW STUDIES OF SPACE-OCCUPYING LESIONS IN THE LIVER

P. Ramanathan, R. D. Ganatra, and M. Blau*

Radiation Medicine Centre, BARC, Bombay, India

Blood flow to space-occupying lesions in the liver was studied by scintillation camera in a series of 170 patients after injection of ^{113m}In -colloid. The curves obtained show a biphasic curve over the normal liver, absence of portal flow over a malignant lesion, and avascularity over benign lesions such as cysts or abscesses. The usefulness and limitations of this technique in distinguishing between a benign and malignant lesion in the liver are discussed.

Almost half of our referrals for liver scanning are in cases of suspected amebic abscesses (1). Scintigraphy is of unquestionable value in establishing the presence of a space-occupying lesion in the liver but usually does not provide any clue to the nature of this lesion. Any investigation that helps in distinguishing between a benign and a malignant lesion in the liver is always worthwhile.

The liver derives its blood supply from two sources—the hepatic artery and the portal vein. A malignancy in the liver obtains its blood supply from the hepatic artery only (2) whereas the benign lesions such as abscesses or cysts are relatively avascular (3). One of us (PR) had earlier tried to exploit this difference in the blood supply by dynamic bloodflow studies with a scintillation camera after injection of ^{113m}In -chloride (4). We now report our experience with dynamic bloodflow studies of space-occupying lesions in the liver with ^{113m}In -colloid.

METHODS

These studies were carried out with a scintillation camera (Picker Dynacamera). The detector head of the camera was positioned in front of the liver and spleen with the patient lying in a supine position. Two to 3 mCi of ^{113m}In -colloid were injected rapidly

in the antecubital vein as a single bolus. All data from the detector for next 2 min were recorded and stored on videotape. During playback two areas of equal dimensions, one over the normal liver and the other over the cold area, were selected. A combined curve of counts versus time of both these areas and an individual curve of each area were obtained on an oscilloscope display through the data processor. Each data point on the display curve was at an interval of 1 sec and each point along the y-axis corresponded to 100 counts.

RESULTS

Figure 1A shows the curve over a normally functioning part of the liver. The curve shows two distinctly different slopes of rise of activity. The initial steep rise begins about 6 sec after the injection, lasts up to 12 sec postinjection, and is due to the hepatic artery inflow. The second phase of gradual rise seen after the initial phase is due to the portal blood flow. Figure 1B shows a representative curve obtained over a confirmed hepatoma. The initial rise shows a peak at around 8 sec and a subsequent decline because of absence of portal blood supply to the malignant area in the liver and the failure to trap the colloid, which reaches this area by the arterial supply. Figure 1C shows the static image of the liver in this case.

Figure 2A and B shows the curves over a normal area and over a cold area subsequently proved to be due to an amebic abscess. The flat curve in Fig.

Received Jan. 18, 1974; revision accepted June 4, 1974.

For reprints contact: R. D. Ganatra, Radiation Medicine Centre, Bio-Medical Group, Bhabha Atomic Research Centre, Tata Memorial Hospital, Parel, Bombay 12, India.

* Dept. of Nuclear Medicine, Roswell Park Memorial Institute, Buffalo, N.Y.

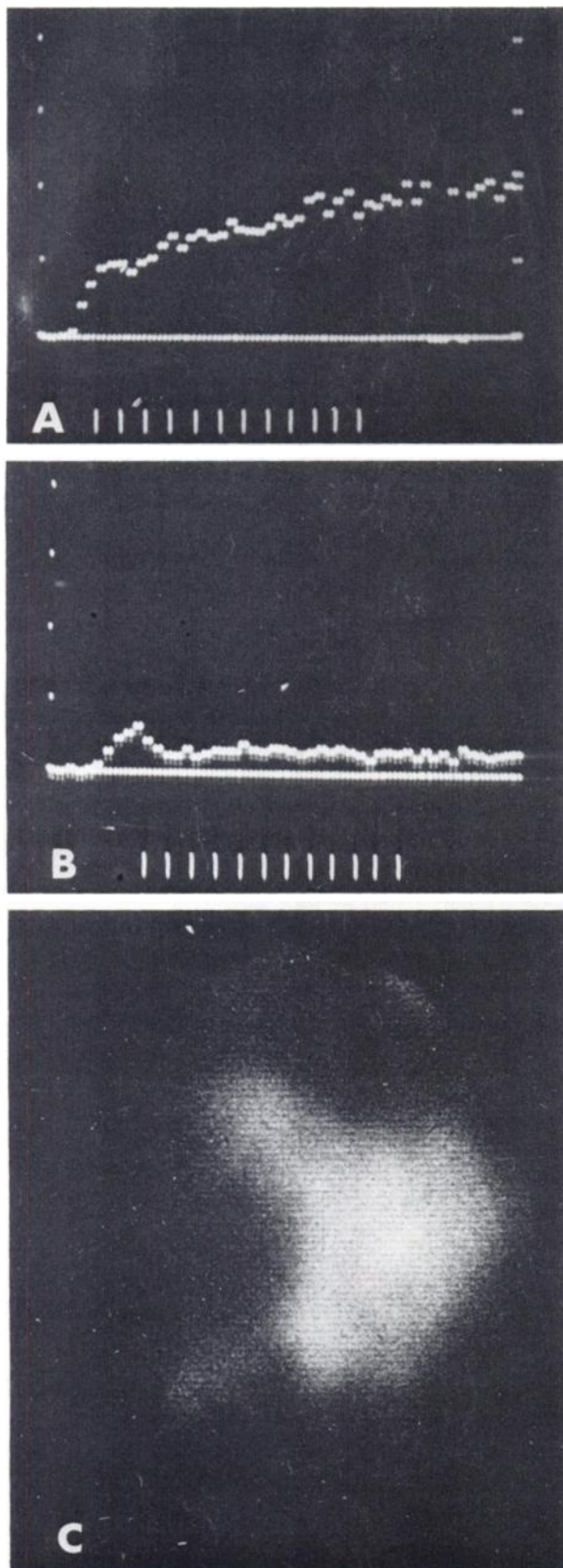


FIG. 1. Time versus counts histograms in case of hepatoma. (A) Curve over normally functioning liver; (B) curve over cold area showing arterial blood flow and absence of portal blood flow; and (C) static image of liver.

2B is evidently the result of relative avascularity of the abscess. Figure 2C shows the scintiphoto of the liver in this case.

Figure 3A, B, and C represents a case of metastases in the liver from carcinoma of colon.

Figure 4A, B, and C shows the curves in a case of hydatid cyst. The avascularity of this space-occupying lesion is well demonstrated by the flat curve over this area (Fig. 4B).

The pattern seen in Fig. 1B and Fig. 3B is considered representative of a malignancy in the liver whereas the pattern in Fig. 2B and Fig. 4B is representative of benign lesions such as abscesses or cysts. It can be seen that in space-occupying lesions that are vascular in nature, as in Fig. 3B, the initial rise due to hepatic arterial blood flow is up to a maximum of 100 counts and subsequently comes down to almost zero. Although we are dealing with low counts from a small region of interest, it is still 20 times more than the background counts to which the curve settles down after the hepatic arterial peak, and it is 100 times more than that one sees in an avascular lesion. The curve obtained in such an area is flat with no rise at all. Table 1 shows how often these representative patterns were seen in 170 patients in whom the final diagnosis was confirmed by aspiration or histology.

Excellent correlation was seen between the histology and the pattern of the curve described above for each of the cases. A false-positive pattern was obtained only in one case—an abscess in the left lobe, where the underlying descending aorta probably masked the avascularity of the abscess.

DISCUSSION

It is well established that both primary and secondary malignancies in the liver do not receive any significant amount of blood through the portal system. It was possible to obtain a biphasic curve over the liver in our previous studies when ^{113m}In -chloride was used and to show a distinct peak for hepatic arterial and portal venous blood flow separately in this curve (5). However, use of a vascular agent such as this requires recalling a patient for a second scan; the first scan with colloid is primarily used for locating a space-occupying lesion in the liver. Moreover, it was often found that cold areas were not sharply delineated on the monitor scope when ionic ^{113m}In was used for dynamic studies, thereby making it difficult to select the regions of interest.

The use of colloid alone for locating the cold area and for the dynamic study simplifies the technique considerably. The curves obtained did not show distinctly the two components of liver flow but it was still possible to demonstrate the absence

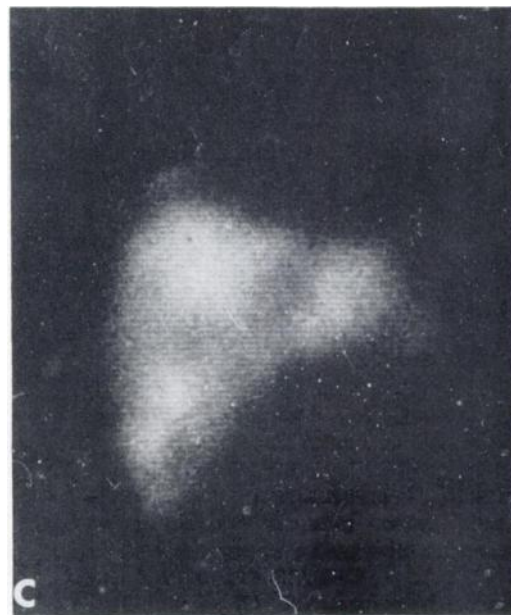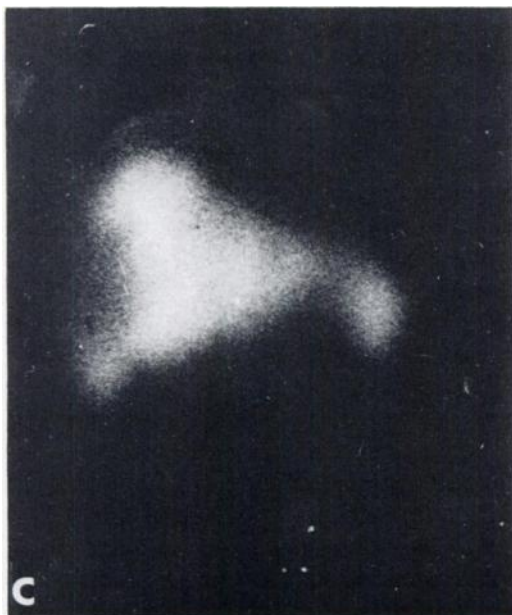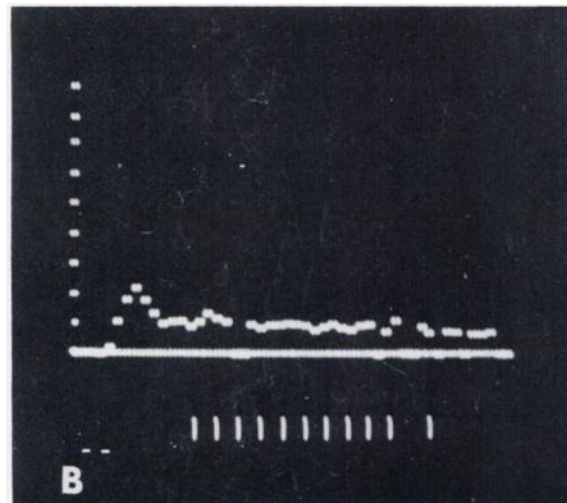
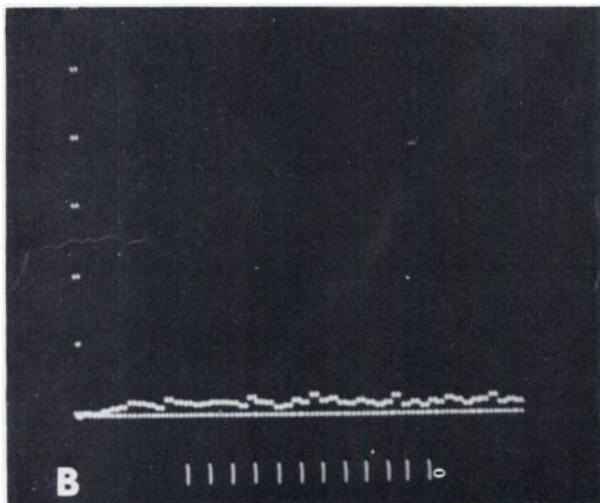
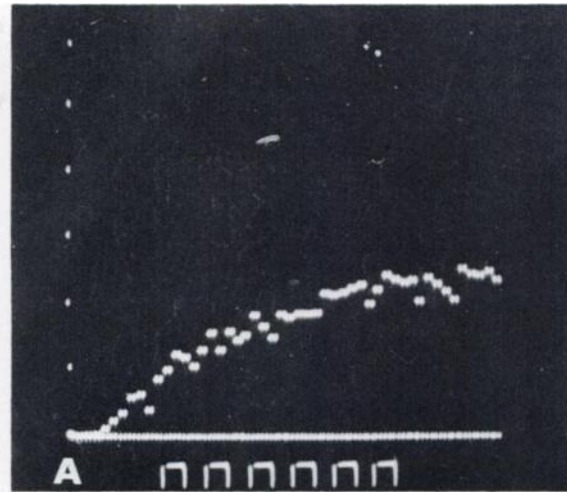
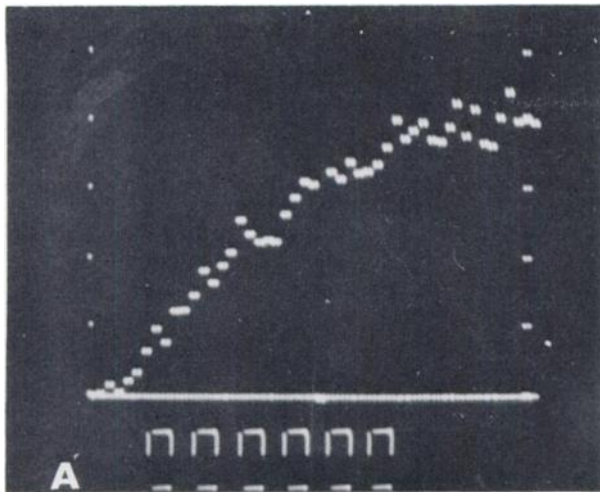


FIG. 2. Time versus counts histograms in case of amebic abscess. (A) Curve over normally functioning liver; (B) curve over cold area showing avascularity; and (C) static image of liver.

FIG. 3. Time versus counts histograms in case of metastases in liver from carcinoma of colon. (A) Curve over normally functioning liver; (B) curve over cold area, and (C) static image of liver.

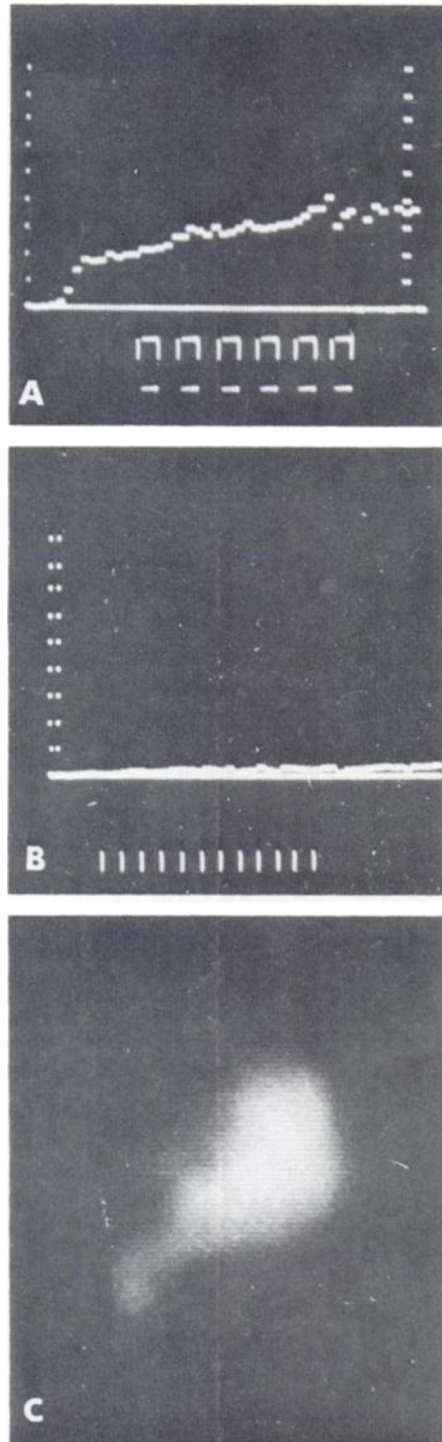


FIG. 4. Time versus counts histogram in case of hydatid cyst. (A) Curve over normally functioning liver; (B) curve over cold area; and (C) static image of liver.

TABLE 1. DYNAMIC BLOODFLOW STUDIES IN 170 PATIENTS WITH SPACE-OCCUPYING LESIONS OF THE LIVER

Pathology of lesion	Patients (No.)	Flat curves (No. of lesions)	Vascular curves (No. of lesions)
Hepatoma	15	0	15
Abscess	64	63	1 (left lobe)
Metastasis	84	0	84
Cyst	7	7	0
Total	170	—	—

of a portal phase in the curves over malignant liver lesions. In fact, the arterial peak of the curve over this kind of lesion was sharply defined because the tracer was not recycled.

As was pointed out by Taplin (5), the diagnostic information obtained by this technique is limited in the case of a small lesion in the liver; the underlying normal liver would not permit a curve truly representative of the lesion. This limitation, though valid, is less restraining in a tropical country where amebic abscesses are common and are usually large by the time the patients report for scan. Very frequently, however, history and clinical examination alone do not distinguish an abscess from a malignancy. We have found that dynamic bloodflow studies offer a useful aid in making this crucial distinction.

REFERENCES

1. GANATRA RD, et al: Radioisotopic investigations of some tropical diseases. In *Peaceful Uses of Atomic Energy*, Vienna, IAEA, 1971, pp 99-115
2. NEBESAR RA, POLLARD JJ, SONE DL: Angiographic diagnosis of malignant disease of the liver. *Radiology* 86: 284-292, 1966
3. UEDA H, et al: Visceral perfusion scintigraphy with ¹³¹I labelled albumin macroaggregates. In *Medical Radioisotope Scintigraphy*, Vienna, IAEA, vol 2, 1968, pp 431-435
4. YAMADA H, RAMANATHAN P, TAPLIN GV: Dual blood circulation studies in liver using magna camera. First Annual Conference of Northern and Southern California Chapters of Society of Nuclear Medicine, Los Angeles, Calif, 1969
5. TAPLIN GV: Dynamic studies of liver function with radioisotopes. In *Dynamic Studies with Radioisotopes in Medicine*, Vienna, IAEA, 1971, pp 373-392