

# Procedure Guideline for Diagnosis of Renovascular Hypertension

Andrew T. Taylor, Jr., James W. Fletcher, Joseph V. Nally, Jr., M. Donald Blaufox, Eva V. Dubovsky, Eugene J. Fine, Daniel Kahn, Kathryn A. Morton, Charles D. Russell, George N. Sfakianakis, Mattias Aurell, Maurizio Dondi, Enza Fommei, Gijsbert Geyskes, Goran Granerus and Hong-Yoe Oei

*Emory University School of Medicine, Atlanta, Georgia; St. Louis University School of Medicine, St. Louis, Missouri; Cleveland Clinic, Cleveland, Ohio; Albert Einstein College of Medicine and Montefiore Medical Center, Bronx, New York; University of Alabama Hospital, Birmingham, Alabama; Jacobi Medical Center, Bronx, New York; Veterans Administration Medical Center, University of Iowa College of Medicine, Iowa City, Iowa; Veterans Administration Medical Center, Portland, Oregon; University of Miami School of Medicine, Miami, Florida; Department of Nephrology, Shalgreńska Hospital, Goteborg, Sweden; Servizio de Medicina Nucleare, Ospedale per gli Infermi, Faenza, Italy; Institute of Clinical Physiology, University of Pisa, Pisa, Italy; Hospital New Nickerie, Suriname; Department of Clinical Physiology, University Hospital, Linköping, Sweden; and Department of Nuclear Medicine, University Hospital Dijkzigt, Rotterdam, The Netherlands*

**Key Words:** renovascular hypertension, procedure guideline

**J Nucl Med 1998; 39:1297-1302**

## PART I: PURPOSE

The purpose of this guideline is to assist nuclear medicine practitioners in recommending, performing, interpreting and reporting the results of renal procedures for diagnosis of renovascular hypertension.

## PART II: BACKGROUND INFORMATION AND DEFINITIONS

Renovascular hypertension is estimated to affect 1%–3% of the unselected hypertension population and up to 15%–30% of patients referred to a subspecialty center because of refractory hypertension. Clinical features should indicate which patients have moderate or high risk of renovascular hypertension. Clues include abrupt or severe hypertension, hypertension resistant to medical therapy, bruits in the abdomen or flank, unexplained azotemia or worsening renal function during therapy with angiotensin-converting enzyme inhibitors (ACEIs). It is important to distinguish between renovascular hypertension and stenosis of the renal artery. Stenosis of the renal artery is common in nonhypertensive elderly persons and is an associated but nonetiologic finding in a number of hypertensive patients. Renovascular hypertension is defined as an elevated blood pressure caused by renal hypoperfusion, usually due to anatomic stenosis of the renal artery and activation of the renin-angiotensin system. The goals of a screening test are to detect those patients who have renal artery stenosis as the cause of hypertension and, to predict curability of hypertension following intervention.

## PART III: COMMON INDICATIONS

The test is most cost-effective if used primarily in patients who have moderate to high risk of renovascular hypertension. Clinical features associated with moderate to high risk of

renovascular hypertension have been published and include the following:

- Abrupt or severe hypertension.
- Hypertension resistant to medical therapy.
- Abdominal or flank bruits.
- Unexplained azotemia.
- Worsening renal function during therapy with ACEIs.
- Grade 3 or 4 hypertensive retinopathy.
- Occlusive disease in other vascular beds.
- Onset of hypertension before age 30 or after age 55.

## PART IV: PROCEDURE

### A. Patient Preparation

The patient should be well hydrated before testing. If an oral ACEI is used, the patient should drink only water and should not eat a solid meal within 4 hr of the study. One suggested protocol is 7 ml water/kg body weight 30–60 min before the study. Hydration should continue between studies if two studies are performed on the same day. An intravenous line should be placed for normal saline infusion in high-risk patients and for those receiving intravenous enalaprilat (see Section IV.C, Precautions, below). Ideally, ACEIs should be withheld for 2–5 days (depending on half-life) before the study. Captopril and enalapril/lisinopril probably should be withheld for 48 hr and 96 hr, respectively. Some patients will present for the test on a therapeutic ACEI. In such a patient, it is reasonable to give the ACEI and perform captopril or enalaprilat renography, although the referring physician should understand that there may be a slight loss of sensitivity.

Chronic administration of diuretics may also decrease the sensitivity of the procedure, and chronic diuretic administration should be stopped several days before the study, if possible. In a well-hydrated patient, however, chronic diuretic administration probably will not affect test results. The effect of other hypertensive medications on ACEI renography is not completely understood, but it appears small. If hypertension is severe, it is not necessary to discontinue all antihypertensive medications before the procedure.

### B. Information Pertinent to Performing the Procedure

Relevant history, physical findings, patient medica-

For correspondence or reprints contact: Wendy J.M. Smith, Director of Health Care Policy, Society of Nuclear Medicine, 1850 Samuel Morse Dr., Reston, VA 20190-5316, or by e-mail at [wsmith@snm.org](mailto:wsmith@snm.org).

Note: All 26 SNM-approved procedure guidelines are available on the Society's home page. We encourage you to download these documents via the Internet at [www.snm.org](http://www.snm.org). If you would like information on the development of this guideline or to order a compendium of all 26 procedure guidelines for \$20.00, contact Marie Davis, Society of Nuclear Medicine, at (703) 708-9000, ext. 250, or by e-mail at [mdavis@snm.org](mailto:mdavis@snm.org).

**TABLE 1**  
Radiation Dosimetry for Adults with Normal Renal Function

Radiopharmaceutical	Administered activity MBq (mCi)	Organ receiving the largest radiation dose* mGy (rad)	Effective dose* mSv (rem)
<sup>99m</sup> Tc-DTPA†	37–370	0.065 Bladder wall (0.24)	0.0063 (0.023)
<sup>99m</sup> Tc-MAG3‡	37–370	0.11 Bladder wall (0.41)	0.0073 (0.027)
	(1–10)		

\*Per MBq (per mCi).  
†ICRP 53, page 188.  
‡ICRP, 62, page 17.

tions, when ACEIs were stopped, patient's serum creatinine and patient's resting blood pressure while sitting and standing.

#### C. Precautions

ACEIs can cause significant hypotension. Therefore, blood pressure and pulse should be monitored and recorded before administration and at least every 10–15 min thereafter. An intravenous line should be established in high-risk patients (e.g., history of carotid disease, stroke, transient ischemic attack, angina and recent myocardial infarction) and in patients who receive intravenous enalaprilat. A patient should not be sent home unless his or her standing blood pressure is at least 70% of baseline and he or she is asymptomatic when standing.

#### D. Radiopharmaceuticals (See Tables 1 and 2.)

The optimal radiopharmaceutical remains to be determined. However, <sup>99m</sup>Tc-mercaptoacetyl triglycine (MAG3) and <sup>99m</sup>Tc-diethylenetriaminepentaacetic acid (DTPA) are most commonly used. Radioiodinated hippuran has also been used. Technetium-99m-MAG3 is preferred over <sup>99m</sup>Tc-DTPA in patients with elevated creatinine because of its higher extraction.

#### E. Image Acquisition

**Study Protocol:** Both 1-day and 2-day protocols are acceptable. If there is a relatively low likelihood of renovascular disease, the 2-day protocol is preferred over the 1-day protocol. The 1-day protocol requires that the patient remain in the department for a longer time, but the entire study is completed in 1 day.

When the 2-day protocol is performed, ACEI renog-

raphy should be done on the first day. If the ACEI renogram is normal, the chance that the patient has renovascular hypertension is low, and there is no need to have the patient return on the second day for a baseline study. When the study result is abnormal, specificity can be improved by obtaining a baseline study.

When the 1-day protocol is performed, baseline renography should be performed first with only 37 MBq (1 mCi) of <sup>99m</sup>Tc-DTPA or <sup>99m</sup>Tc-MAG3. The administered activity for the ACEI renogram should be 200–400 MBq (5–10 mCi) to overwhelm any counts from the baseline study.

#### *Instrumentation, Positioning and Timing of Images:*

The study should be acquired with the gamma camera facing the lower back of the supine patient. A large-field-of-view camera is preferred so that the heart, kidneys and bladder can all be included in the field of view. If only two organs can be imaged, the kidney and bladder should be visualized. For <sup>99m</sup>Tc agents and 123-orthoiodohippurate (OIH), a low-energy or high-resolution, all-purpose collimator should be used. Matrix resolution is preferably 128 × 128, although 64 × 64 is acceptable. When a dynamic flow study is obtained, the time per frame should be 1–3 sec for the first 60 sec and 10–30 sec per frame for the remainder of the study. The total acquisition time should be 20–30 min. Patients should void before beginning the study, and a postvoid image is recommended.

#### F. Interventions

Although captopril has been most widely used, captopril and enalaprilat are both acceptable for ACEI

**TABLE 2**  
Radiation Dosimetry for Children with Normal Renal Function\* (5-yr-old)

Radiopharmaceutical	Administered activity MBq/kg (mCi/kg)	Organ receiving the largest radiation dose† mGy (rad)	Effective dose† mSv (rem)
<sup>99m</sup> Tc-DTPA	3.7	0.086 Bladder wall (0.32)	0.012 (0.044)
<sup>99m</sup> Tc-MAG3	3.7	0.18 Bladder wall (0.67)	0.015 (0.055)
	(0.1)		

\*Treves ST, *Pediatric Nuclear Medicine*, 2nd ed., New York: Springer-Verlag; 1995.

†Per MBq (per mCi).

renography. The recommended dose of captopril is 25–50 mg by mouth. Crushing the tablets and dissolving them in 150–250 ml water may enhance absorption. Unless the patient has delayed gastric emptying or poor absorption from the gastrointestinal tract, 25 mg is sufficient. Patients should not eat a solid meal within 4 hr of the study, as food in the gastrointestinal tract decreases captopril absorption. Radiopharmaceutical administration should be delayed for at least 60 min after captopril administration, as peak blood levels occur approximately 60 min after oral ingestion. Enalaprilat (Vasotec) can also be used, with 40 µg/kg administered intravenously over 3–5 min. A total dose of 2.5 mg should not be exceeded. Because the radiopharmaceutical can be given 15 min after enalaprilat administration, procedure time is shorter and potential problems with gastrointestinal tract absorption are also avoided. It is recommended that the radiopharmaceutical not be administered until at least 15 min after intravenous enalaprilat administration.

*Option:* Administration of furosemide with captopril or enalaprilat is not considered to be an essential component of ACEI renography. Since furosemide is a loop diuretic, it can wash the radiopharmaceutical out of the calyces and pelvis and improve evaluation of cortical retention of tubular agents MAG3 and OIH. It also can cause volume depletion and increase the risk of hypotension.

#### G. Processing

Background subtraction is recommended using a ring, elliptical or perirenal region of interest (ROI). The renal uptake of MAG3 and OIH should be measured in each kidney in the 1–2- or 1–2.5-min interval after injection of the radiopharmaceutical. After 2.5 min a portion of these tracers may have already left the renal ROI, thus leading to incorrect estimates of relative function. The relative renal uptake of DTPA should be measured from 2–3 min postinjection. Renogram curves should be generated from ROIs that are selectively assigned to the renal cortices or the whole kidney. Exclusion of the pelvis and calyces is important if there is retention of activity in these structures. The time to maximum activity ( $T_{max}$ ) should be determined. A 20 min/peak min (20 min/maximum) activity ratio should be calculated for MAG3 and OIH. Measurement of renal parenchymal transit time is recommended using a parenchymal ROI if the software algorithm is available.

#### H. Interpretation/Reporting

The most specific diagnostic criterion for renovascular hypertension is an ACEI-induced change in the renogram. Overall, ACEI renography has a sensitivity and specificity of about 90% for diagnosis of renal artery stenosis. Most importantly, ACEI-induced renographic findings of renovascular hypertension indicate a high probability that blood pressure will be reduced after intervention.

The post-test probability for disease cannot be determined solely based on the test results. The test results must be combined with the pretest probability. In the discussion of probability that follows, a pretest probability of 10%–30% is assumed for high-risk patients in whom ACEI renography should be performed. When this test is performed in lower-risk patients, the post-test probability will be lesser than the numbers cited below. Test results should be interpreted as consistent with high, low or intermediate probability of disease.

*Low Probability:* Normal findings on ACEI renography indicate a low probability (<10%) for renovascular hypertension. Abnormal baseline findings that improve after ACE inhibition also indicate low probability for renovascular hypertension.

*Intermediate Probability:* Patients with intermediate probability of disease have abnormal baseline findings but the renogram is unchanged after ACE inhibition. This group includes some azotemic patients and hypertensive patients who have a small, poorly functioning kidney. The sensitivity of abnormal baseline findings that are unchanged after ACE inhibition is quite high (>90%), but the specificity is poor, probably in the range of 50%–75%.

*High Probability:* The probability is considered high (>90%) when marked change of the renogram curve occurs after ACE inhibition compared to baseline findings. For DTPA, this change can be quantitated by measuring the change in relative function or absolute individual kidney function. For tubular agents, the change can be best quantitated by a change in the 20 min/peak count ratio or a prolongation of the  $T_{max}$ . In subjects with normal renal function and in the absence of pelvic or caliceal retention, a normal 20 min/peak ratio for OIH or MAG3 is <0.3. A 0.15 change (i.e., 0.3–0.45) after ACE inhibition usually is considered to be significant. A 0.1–0.15 change is considered to be borderline.

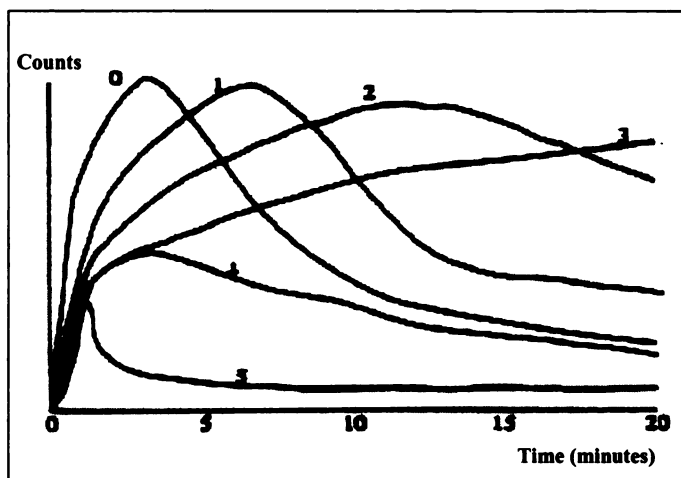
#### *General Interpretive Criteria:*

- A normal ACEI renogram indicates a low probability (< 10%) of renovascular hypertension.
- Criteria associated with renovascular hypertension include worsening of the renogram curve, reduction in relative uptake, prolongation of the renal and parenchymal transit time, increase in the 20 min/peak ratio and prolongation of the  $T_{max}$ .
- A small, poorly functioning kidney (<30% uptake with a  $T_{max} \leq 2$  min) that shows no change after ACEI renography and bilateral symmetrical change (cortical retention with tubular agents and decrease of DTPA uptake) are indicative of intermediate probability for renovascular hypertension.

#### *Specific Interpretive Criteria for MAG3 and OIH:*

Unilateral parenchymal retention after ACEI administration is the most important criterion for MAG3 and OIH and represents high probability (>90%) for renovascular hypertension. This can be measured by a change in the 20 min/peak ratio of 0.15 or greater, a significantly prolonged transit time or a change in the renogram grade (Fig. 1). It also can be detected as a delay in the excretion of the tracer into the renal pelvis >2 min after ACEI administration or an increase in the  $T_{max}$  of at least 2 min or 40%. A change in relative uptake of MAG3 or OIH >10% after ACEI administration is uncommon, but it represents a high probability for renovascular hypertension when present.

*Specific Interpretive Criteria for DTPA:* Reduction in relative uptake greater than 10% after ACEI administration indicates high probability for renovascular hypertension; 5%–9% indicates intermediate response. High probability is also associated with a



**FIGURE 1.** Patterns of renographic curves from normal to blood background-type curve. 0 = normal; 1 = minor abnormalities, but with  $T_{max} > 5$  min and (for OIH and MAG3) 20 min/max ratio  $> 0.3$ ; 2 = marked delayed excretion rate with preserved washout phase; 3 = delayed excretion rate without washout phase (accumulation curve); 4 = renal failure pattern with measurable kidney uptake; 5 = renal failure pattern without measurable kidney uptake (blood background-type curve).

10% decrease in calculated glomerular filtration rate of the ipsilateral kidney after ACEI administration. Marked unilateral parenchymal retention after ACEI administration compared to baseline study also represents high probability for renovascular hypertension.

#### I. Quality Control

Gamma camera and image displays as described in the *Society of Nuclear Medicine Procedure Guideline for General Imaging*. Images should be reviewed in a dynamic format to evaluate for presence of patient motion.

#### J. Sources of Error

Existing clinical and renographic results must be interpreted with some caution because the protocols are complex and the diagnostic criteria are not well standardized.

### PART V: DISCLAIMER

The Society of Nuclear Medicine has written and approved guidelines to promote the cost-effective use of high-quality nuclear medicine procedures. These generic recommendations cannot be applied to all patients in all practice settings. The guidelines should not be deemed inclusive of all proper procedures or exclusive of other procedures reasonably directed to obtaining the same results. The spectrum of patients seen in a specialized practice setting may be quite different than the spectrum of patients seen in a more general practice setting. The appropriateness of a procedure will depend in part on the prevalence of disease in the patient population. In addition, the resources available to care for patients may vary greatly from one medical facility to another. For these reasons, guidelines cannot be rigidly applied.

Advances in medicine occur at a rapid rate. The date of a guideline should always be considered in determining its current applicability.

### PART VI: ISSUES REQUIRING FURTHER CLARIFICATION

- A. It would be useful to know how high a patient's serum creatinine can be without significantly compromising test accuracy.

- B. The following sources of error should be discussed: (1) retained activity within the collecting system and (2) ROI selection, hepatic uptake of MAG3. The location of the right kidney background ROI may significantly affect the calculated relative uptake in patients with severely impaired renal function.
- C. The reference test or "gold standard" in future studies should be the *outcome*, the response to successful revascularization, not angiographic evidence of renal artery stenosis. Future studies also need to clearly define patient subgroups and the results of ACEI administration in these subgroups, (e.g., azotemic versus nonazotemic patients; results in patients taking diuretics, beta-blockers and ACEIs versus patients not taking these medications; and results in patients with normal baseline studies versus results in patients with abnormal baseline studies). The utility of 1–3-sec dynamic images in detection of renovascular hypertension is uncertain. Further information is needed correlating bilateral symmetrical changes in the renogram curve with angiography and with results of revascularization. Additional studies are needed in patients with solitary kidneys or renal transplants. Additional data are needed regarding the effect of chronic drug administration (diuretics, beta-blockers, ACEIs) on test sensitivity and specificity; regarding the utility of ACEI renography in assessing functional significance of stenosis of the least-affected kidney in patients with bilateral renal artery stenosis; on the effects of salt loading and the state of hydration; and on better characterization of the baseline abnormality in patients in whom the abnormal baseline does not change after ACEI administration.

### PART VII: CONCISE BIBLIOGRAPHY

1. Black HR, Bourgoignie JJ, Pickering T, et al. Report of the working party group for patient selection and preparation. *Am J Hypertens* 1991;4:7455–7465.
2. Black HR. Captopril renal scintigraphy—a way to distinguish functional from anatomic renal artery stenosis [Editorial; Comment]. *J Nucl Med* 1992;33:2045–2046.
3. Blaufox MD, Dubovsky EV, Hilson AJ, et al. Report of the working party group on determining the radionuclide of choice. *Am J Hypertens* 1991;4:7475–7485.
4. Blaufox MD. Captopril renography: considerations in the selection of radiopharmaceuticals, provocative agents, and hypertensive subjects. *Am J Hypertens* 1991;4:6755–6775.
5. Clorius JH, Hupp T, Schmidlin P, et al. The diagnosis of renovascular hypertension: the role of captopril renal scintigraphy and related issues [Letter; Comment]. *Eur J Nucl Med* 1994;21:264–267.
6. Derkx FH, van den Meiracker AH, Jaarsveld BC, et al. Captopril in the diagnostic work-up of hypertensive patients with suspected renal artery stenosis. *Neth J Med* 1993;43: S12–S19.
7. Dey HM, Hoffer PB, Lerner E, et al. Quantitative analysis of the technetium-99m-DTPA captopril renogram: contribution of washout parameters to the diagnosis of renal artery stenosis. *J Nucl Med* 1993;34:1416–1419.
8. Dondi M. Captopril renal scintigraphy with  $^{99m}\text{Tc}$ -mercap-

- toacetyltriglycine ( $^{99m}\text{Tc}$ -MAG3) for detecting renal artery stenosis. *Am J Hypertens* 1991;4:7375–7405.
9. Dondi M, Fanti S, Fabritiis AD, et al. Prognostic value of captopril renal scintigraphy in renovascular hypertension [see comments]. *J Nucl Med* 1992;33:2040–2044.
  10. Dondi M, Fanti S, Monetti N. Captopril renal scintigraphy: a viewpoint. *J Nucl Biol Med* 1993;37:259–263.
  11. Dubovsky EV, Russell CD. Diagnosis of renovascular hypertension after renal transplantation. *Am J Hypertens* 1991;4:7245–7305.
  12. Erley CM, Duda SH, Wakat JP, et al. Noninvasive procedures for diagnosis of renovascular hypertension in renal transplant recipients—a prospective analysis. *Transplantation* 1992;54:863–867.
  13. Fanti S, Dondi M, Barozzi L, et al. Detection of renal artery stenosis by means of captopril renal scintigraphy in patients with multiple renal arteries. *Clin Nucl Med* 1992;17:849–852.
  14. Fine EJ. Captopril scintirenography: a protocol to assess efficacy and methodology. A collaborative study. *Contrib Nephrol* 1990;79:211–218.
  15. Fine EJ, Blaufox MD. The Einstein/Cornell collaborative protocol to assess efficacy and methodology in captopril scintirenography: early results in patients with essential hypertension. Report of the Einstein/Cornell Collaborative Hypertension Group [published erratum appears in *Am J Hypertens* 1992;5:49]. *Am J Hypertens* 1991;4:7165–7205.
  16. Fine EJ. Nuclear medicine evaluation of hypertension. *Urol Radiol* 1992;14:85–95.
  17. Fleishman MJ, Greenspan RL, Heertum RV. The additional value of visual findings in captopril-enhanced renal scintigraphy with Tc-99m MAG3. *Clin Nucl Med* 1993;18:382–386.
  18. Fommei E, Mezzasalma L, Ghione S. Captopril radionuclide test in renovascular hypertension: a European multicenter study. *Contrib Nephrol* 1990;79:205–210.
  19. Fommei E, Mezzasalma L, Ghione S, et al. European captopril radionuclide test multicenter study: preliminary results. Inspective renographic analysis. The European Captopril Radionuclide Test Multicenter Study Group. *Am J Hypertens* 1991;4:6905–6975.
  20. Gale B, Zhang C, Lee HB, et al. The effect of captopril on glucoheptonate uptake in experimental renal artery stenosis. *Nucl Med Commun* 1992;13:110–113.
  21. Geyskes GG, Bruyn A. Captopril renography and the effect of percutaneous transluminal angioplasty on blood pressure in 94 patients with renal artery stenosis. *Am J Hypertens* 1991;4:6855–6895.
  22. Hillman BJ. The imaging diagnosis of renovascular hypertension. *Urol Radiol* 1990;12:130–131.
  23. Itoh K, Tsukamoto E, Nagao K, et al. Captopril renoscintigraphy with Tc-99m DTPA in patients with suspected renovascular hypertension: prospective and retrospective evaluation. *Clin Nucl Med* 1993;18:463–471.
  24. Jensen G, Moonen M, Aurell M, et al. Reliability of ACE inhibitor-enhanced  $^{99m}\text{Tc}$ -DTPA gamma camera renography in the detection of renovascular hypertension. *Nucl Med Commun* 1993;14:169–175.
  25. Kang Z, Chen F, Wang Z. Evaluation of captopril renography with  $^{99m}\text{Tc}$ -MAG3 in the diagnosis of renovascular hypertension [published erratum appears in *Chin Med Sci J* 1994;9:214]. *Chin Med Sci J* 1994;9:49–51.
  26. Kletter K, Mostbeck G, Duczak R. Captopril renography and duplex sonography: comparison of two noninvasive methods for the diagnosis and follow-up in renovascular hypertension. *Contrib Nephrol* 1990;79:190–195.
  27. Lee HB, Blaufox MD. Renal functional response to captopril during diuretic therapy. *J Nucl Med* 1992;33:739–743.
  28. Lu ZW, Liu LS. The value of the captopril test and the effect of captopril on renal function. *J Hum Hypertens* 1990;4:138–140.
  29. McLean AG, Hilson AJ, Scoble JE, et al. Screening for renovascular disease with captopril-enhanced renography. *Nephrol Dial Transplant* 1992;7:211–215.
  30. Meholic AJ, Saddler MC, Hallin GW, et al. The captopril renogram in percutaneous transluminal angioplasty of the renal arteries. *Am J Physiol Imaging* 1992;7:36–41.
  31. Meier GH, Sumpio B, Setaro JF, et al. Captopril renal scintigraphy: a new standard for predicting outcome after renal revascularization. *J Vasc Surg* 1993;17:280–285.
  32. Miralles M, Santiso A, Gimenez A, et al. Renal duplex scanning: correlation with angiography and isotopic renography. *Eur J Vasc Surg* 1993;7:188–194.
  33. Nally JV Jr, Bedoya LA, Park CH, et al. Captopril-stimulated renography versus renal vein renins in two-kidney, two-clip hypertension. *Contrib Nephrol* 1990;79:176–180.
  34. Nally JV Jr, Chen C, Fine E, et al. Diagnostic criteria of renovascular hypertension with captopril renography: a consensus statement. *Am J Hypertens* 1991;4:7495–7525.
  35. Nally JV Jr, Black HR. State-of-the-art review: captopril renography—pathophysiological considerations and clinical observations. *Semin Nucl Med* 1992;22:85–97.
  36. Nally JV Jr. Provocative captopril testing in the diagnosis of renovascular hypertension. *Urol Clin North Am* 1994;21:227–234.
  37. Nortier J, Wautrecht JC, Delcour C, et al. Role of the captopril test in renovascular hypertension: a case report. *Angiology* 1992;43:939–945.
  38. Oei HY. Captopril renography: early observations and diagnostic criteria. *Am J Hypertens* 1991;4:6785–6845.
  39. Pedersen EB. Angiotensin-converting enzyme inhibitor renography: pathophysiological, diagnostic and therapeutic aspects in renal artery stenosis. *Nephrol Dial Transplant* 1994;9:482–492.
  40. Pelsang RE, Rezai K. Abnormal captopril renogram in a patient without renovascular hypertension. *Clin Nucl Med* 1992;17:303–305.
  41. Piccoli A, Pillon L. Reasonable positive predictive values of captopril renography in renovascular hypertension [Letter; Comment]. *Am J Nephrol* 1993;13:298–299.
  42. Pickering TG. Diagnosis and evaluation of renovascular hypertension: indications for therapy. *Circulation* 1991;81 (suppl 2):I147–I154.
  43. Roccatello D, Picciotto G, Rabbia C, et al. Prospective study on captopril renography in hypertensive patients [see comments]. *Am J Nephrol* 1992;12:406–411.
  44. Sfakianakis GN, Sfakianaki E, Bourgoignie J. Lasix captopril renography in the diagnosis of renovascular hypertension. *Contrib Nephrol* 1990;79:219–227.
  45. Sheps SG, Blaufox MD, Nally JV Jr, et al. Radionuclide scintirenography in the evaluation of patients with hypertension: American College of Cardiology position statement. *J Am Coll Cardiol* 1993;21:838–839.
  46. Stansby GP, Hilson AJ, Hamilton G. Renovascular hypertension secondary to renal artery aneurysm detected by captopril-renography. *Eur J Vasc Surg* 1991;5:343–346.
  47. Stansby GP, Scoble J, Hilson A, et al. Captopril renal scintigraphy—an advance in the detection and treatment of

renovascular hypertension [Letter; Comment]. *J Vasc Surg* 1991;13:765-766.

48. Svetkey LP, Wilkinson R Jr, Dunnick NR, et al. Captopril renography in the diagnosis of renovascular disease. *Am J Hypertens* 1991;4:7115-7155.
49. Takata M, Yoshida K, Tomoda F, et al. Diagnostic value of captopril test in hypertensive patients with renal artery stenosis. *Angiology* 1994;45:181-186.
50. Taylor A Jr, Martin LG. The utility of <sup>99m</sup>Tc-mercaptoacetyltriglycine in captopril renography. *Am J Hypertens* 1991;4:7315-7365.
51. Trepashko DW, Warner D, Arruda J, et al. Positive captopril renal scintigraphy in a patient with extensive bilateral renal interlobar arterial disease. *Clin Nucl Med* 1994;19:727-730.
52. Wilcox CS. ACE inhibitors in the diagnosis of renovascular hypertension. *Hosp Pract (Off Ed)* 1992;27:117-121.

**PART VIII: LAST HOUSE OF DELEGATES APPROVAL DATE**  
January 14, 1996

**PART IX: NEXT ANTICIPATED APPROVAL DATE**  
1998

#### ACKNOWLEDGMENTS

Henry D. Royal, MD, immediate past-chair of the Guidelines and Communications Committee, Commission on Health Care Policy and Practice, for overall coordination and oversight of the Society of Nuclear Medicine Guideline Development Project; Wendy J.M. Smith, MPH, Director of Health Care Policy, Society of Nuclear Medicine, for project coordination, data collection and editing; and members of the Guideline Development Subcommittee, who contributed their time and expertise to the development of this information.

---

# Procedure Guideline for Tumor Imaging Using Fluorine-18-FDG

Heinrich R. Schelbert, Carl K. Hoh, Henry D. Royal, Manuel Brown, Magnus N. Dahlbom, Farrokh Dehdashti and Richard L. Wahl

*University of California Los Angeles School of Medicine, Los Angeles, California; Mallinckrodt Institute of Radiology, St. Louis, Missouri; University of Pittsburgh Medical Center, Pittsburgh, Pennsylvania; and University of Michigan Medical Center, Ann Arbor, Michigan*

---

**Key Words:** tumor imaging; fluorodeoxyglucose; PET; procedure guideline; positron imaging

**J Nucl Med 1998; 39:1302-1305**

---

## PART I: PURPOSE

The purpose of this guideline is to assist nuclear medicine practitioners in recommending, performing, interpreting and reporting the results of 18-fluoro-2-deoxyglucose (FDG) imaging in the evaluation of patients with suspected malignant disease, for staging malignant disease or for monitoring therapy.

## PART II: BACKGROUND INFORMATION AND DEFINITIONS

There is a growing body of evidence for the use of FDG in differentiating malignant from benign disease, staging and grading malignant disease, differentiating recurrent disease from therapy-induced changes and monitoring response to therapy.

Depending on the clinical question and type of equipment available, the FDG imaging procedure may include the following:

*Limited-Field Tomographic Images:* Usually performed when critical abnormalities are likely to be localized in a known

region of the body (e.g., probable lung carcinoma, evaluation of hilar lymph node involvement).

*Dynamic Tomographic Images:* Consist of multiple sequential three-dimensional images in a limited field. This type of acquisition often is used when quantitation of regional metabolic rates is needed.

*Whole-Body Tomographic Images:* Usually performed to survey the entire body to search for areas of abnormal FDG accumulation.

*Attenuation Correction:* The method for correcting emission photon attenuation by either:

*Transmission Imaging:* A set of corresponding images are acquired with an external source of radiation. Typically, these images are acquired with PET.

*Mathematical Attenuation Correction:* Typically used in brain imaging, where an estimated attenuation correction based on the emission data may be used instead of actually acquiring transmission data.

## PART III: COMMON INDICATIONS

- A. Differentiation of benign from malignant lesions (2,3,6,7).
- B. Staging of malignant disease (7,10,11).
- C. Grading of malignant brain lesions (2,3).
- D. Differentiation of recurrent malignant disease from therapy-induced changes (4,9,12).
- E. Monitoring response to therapy for breast cancer (13).

## PART IV: PROCEDURE

- A. Patient Preparation
  1. Prearrival

Patients fast for at least 4 hr to diminish physiologic

---

For correspondence or reprints, contact: Wendy J.M. Smith, Director of Health Care Policy, Society of Nuclear Medicine, 1850 Samuel Morse Dr., Reston, VA 20190-5316, or by e-mail at [wsmith@snm.org](mailto:wsmith@snm.org).

Note: All 26 SNM-approved procedure guidelines are available on the Society's home page. We encourage you to download these documents via the Internet at [www.snm.org](http://www.snm.org). If you would like information on the development of this guideline or to order a compendium of all 26 procedure guidelines for \$20.00, contact Marie Davis, Society of Nuclear Medicine, at (703) 708-9000, ext. 250, or by e-mail at [mdavis@snm.org](mailto:mdavis@snm.org).