Septal Perfusion and Wall Thickening in Patients with Left Bundle Branch Block Assessed by Technetium-99m-Sestamibi Gated Tomography

Hideki Sugihara, Nagara Tamaki, Masato Nozawa, Tomoko Ohmura, Yasuhiko Inamoto, Yoshimitsu Taniguchi, Etsuo Aoki, Kenichi Mitsunami and Masahiko Kinoshita

Takashima General Hospital; Department of Nuclear Medicine, Hokkaido University; First Department of Internal Medicine, Shiga University of Medical Science, Shiga-ken, Japan

Septal hypoperfusion is often observed in patients with complete left bundle branch block (LBBB) in myocardial perfusion imaging. Abnormal wall motion in the septal region may potentially cause artifactual perfusion abnormalities. To assess the effect of abnormal wall thickening on myocardial perfusion images, ECG-gated sestamibi SPECT was performed on 12 patients with LBBB and 10 normal subjects used as controls. **Methods:** After administration of 740 MBq ^{99m}Tc-sestamibi injection at rest, ECG-gated SPECT was obtained 60 min later with division of the cardiac cycle into eight frames. **Results:** Septal hypoperfusion was noted in 10 patients on nongated images and 11 patients on end-systolic (ES) images, whereas only two patients showed abnormalities on end-diastolic (ED) images. The septal to lateral wall count ratio in the LBBB group was lower (0.72 ± 0.09) than in the control group (0.84 ± 0.09) ($p < 0.01$) at nongated images, while it was similar at ED images (0.84 ± 0.11 versus 0.86 ± 0.12; ns). In addition, the count increase from ED to ES during a cardiac cycle in the septal region was smaller compared with the lateral region in the LBBB patients (25% ± 19% in the septal region, versus 48% ± 14% in the lateral region; $p < 0.01$), indicating less wall thickening in the septal region. **Conclusion:** Smaller count increase due to reduced wall thickening in the septal region may mimic hypoperfusion in patients with LBBB. This artifact can be eliminated with ECG-gated ^{99m}Tc-sestamibi SPECT, particularly with ED images.

Key Words: SPECT; myocardial perfusion; wall thickening; left bundle branch block

J Nucl Med 1997; 38:545–547

It is well known that stress-induced perfusion abnormalities are often detected on ^{201}Tl (*1–5*) and ^{99m}Tc-sestamibi (*6,7*) imaging in patients with complete left bundle branch block (LBBB) in the absence of coronary artery disease (CAD). In addition, some LBBB patients show hypoperfusion in the septal region even in a resting study. The pathophysiology of hypoperfusion and the relation between hypoperfusion and the sequence of abnormal wall motion remains poorly understood. A new myocardial perfusion agent, ^{99m}Tc-sestamibi, permits electrocardiogram-gated (ECG) perfusion tomography (*8–11*). Therefore, both regional myocardial perfusion and wall thickening can be assessed simultaneously. Accordingly, we have performed ECG-gated tomography using ^{99m}Tc-sestamibi in patients with LBBB to evaluate regional perfusion and wall thickening in the septal region. The purpose of this study was to clarify the effect of regional wall thickening on regional perfusion in LBBB patients.

Received Feb. 26, 1996; accepted Jul. 31, 1996.

For correspondence or reprints contact: Hideki Sugihara, MD, Dept. of Internal Medicine, Takashima General Hospital, 1667 Katsuno Takashima-cho, Takashima-gun, Shiga-ken, 520-11, Japan.

MATERIALS AND METHODS

Twelve patients with constant LBBB without history of myocardial infarction and 10 normal subjects were studied with ECG-gated SPECT. All the LBBB patients had a low likelihood of CAD based on clinical manifestations. Each patient and control subject received 740 MBq ^{99m}Tc-sestamibi injection at rest; 60 min later, ECG-gated SPECT was performed with division of the cardiac cycle into eight frames. A rotating gamma camera equipped with a low-energy, general purpose collimator was used for image acquisition. Thirty-two projections (40 beats each) were obtained from the left posterior oblique to the right anterior oblique projections over 180°. Reconstruction was performed using filtered backprojection with a Butterworth filter with a cutoff frequency of 0.4 cycles/cm. A series of short-axis images were displayed to determine the end-systolic images having the smallest cavity (often the fourth frame), and end-diastolic SPECT images were derived from the data of the first frame. In addition, nongated images were reconstructed from the projection data summed with the data of eight frames.

Septal perfusion of nongated, ED and ES images were visually scored into three grades: normal, mild hypoperfusion and severe hypoperfusion by the consensus of two independent observers (one nuclear physician and one cardiologist). In addition, for quantitative assessment of septal perfusion, 2 × 2 pixel (12 × 12 mm) square regions of interest (ROI) were taken in the septal and lateral regions of mid short-axis slices to calculate the septal to lateral wall count ratio. The radioactivity changes during a cardiac cycle in these regions were calculated and normalized by the peak count of the lateral wall.

Data are presented as mean ± s.d. The LBBB and normal group values were compared using the unpaired Student's t-test. A p value < 0.05 was considered significant.

RESULTS

In the qualitative assessment of septal perfusion, hypoperfusion was noted in the nongated images of 10 of the 12 LBBB patients and on the ES images of 11 patients, whereas only two patients showed hypoperfusion on ED images (Fig. 1). Furthermore, severe hypoperfusion was observed in two patients on nongated images and in eight patients on ES images, whereas no patient had severe hypoperfusion on ED images (Figs. 2 and 3).

In the quantitative assessment, the septal to lateral wall count ratio of the LBBB group was lower than that of the control group on the ES images (0.62 ± 0.10 versus 0.81 ± 0.11 $p < 0.001$) and on the nongated images (0.72 ± 0.09 versus 0.84 ± 0.09 $p < 0.01$), while the ratios were similar on the ED images (0.84 ± 0.11 versus 0.86 ± 0.12; ns) (Table 1). In addition, in the LBBB group, there was less count increase in the septal

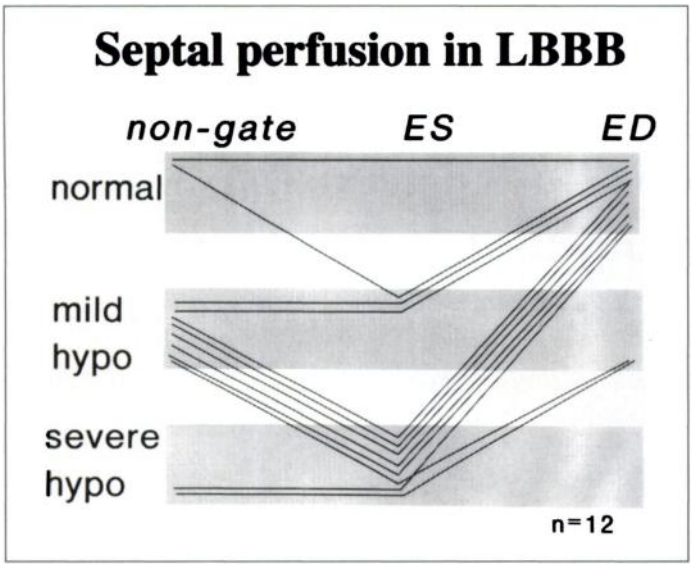

FIGURE 1. Qualitative assessment of septal perfusion of 12 patients with LBBB on nongated (left), ES (middle) and ED (right) images.

region during a cardiac cycle than in the lateral region; the count increase from ED to ES was 25% ± 19% in the septal region and 48% ± 14% in the lateral region ($p < 0.01$) (Fig. 4).

The radioactivity change on the lateral wall tended to be delayed in patients with LBBB compared with normal subjects. In contrast, the phase of the peak count on the septal wall was earlier than that of the normal subjects (Fig. 4).

DISCUSSION

The results of this study demonstrated that even though the majority of patients with LBBB showed septal hypoperfusion on nongated images, ED images were almost the same as those of normal subjects in qualitative and quantitative assessment. These findings indicated that the hypoperfusion on nongated images is a result of reduced wall thickening rather than actual hypoperfusion at rest. Our data is concordant with the report by Knapp et al. (*6*) showing a fixed septal defect in patients with LBBB and the absence of CAD on nongated sestamibi stress/rest images. Altehoefer et al. (*12*) showed that less than 50% of the patients with LBBB showed perfusion abnormalities at rest. However, this study included the qualitative and quantitative data which clearly indicated hypoperfusion in the majority of the patients, whereas the ED images showed relatively homogeneous perfusion as was seen in Figures 2 and 3.

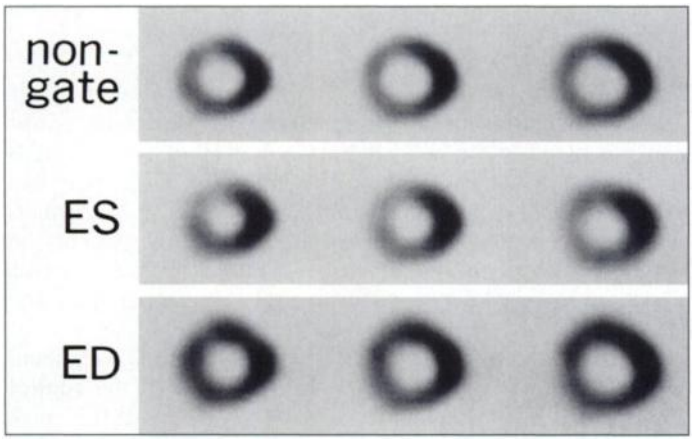

FIGURE 2. Short axial slices of a 67-yr-old woman with LBBB and absence of CAD. Nongated image (top) show septal hypoperfusion. ES image (middle) show severe hypoperfusion. In contrast, there is not apparent perfusion abnormalities on ED image (bottom).

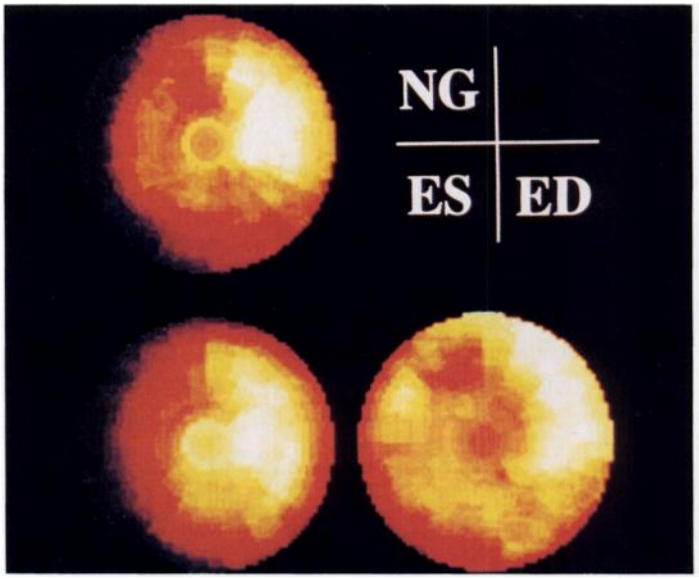

FIGURE 3. Polar maps of a 57-yr-old woman with LBBB and without CAD. Nongated polar map demonstrate septal hypoperfusion (upper left), whereas end-diastolic polar map demonstrates almost normal perfusion (lower right).

ECG-gated myocardial perfusion SPECT permits the simultaneous assessment of regional wall motion and myocardial perfusion (*8–11*). Recent reports indicated that regional wall thickening can be evaluated quantitatively by measuring the count increase from the ED to the ES phase (*13–15*). Count-based evaluation of wall thickening was justified on the principle of partial volume effect (*14,15*). In this study, the effect of count increase due to myocardial wall thickening during the systolic period was assessed quantitatively. In patients with LBBB, the septal count increase was significantly less than that in the lateral wall in these patients, and less than in any segment in normal subjects, indicating a disproportional decrease in regional wall thickening in the septal region.

In the evaluation of change in myocardial radioactivity, the phase of peak count on the lateral wall tended to be delayed compared with normal subjects, probably due to conduction delay to the free wall of the left ventricle. These results corresponded to the finding that the onset of left ventricular contraction was delayed in patients with LBBB (*16*). The pathophysiological mechanism of the decrease of wall thickening in the septal region with relatively preserved perfusion remains unknown. More precise investigations of the regional contraction and potential mechanisms using echocardiography and MR and metabolic imaging are warranted.

The nongated myocardial perfusion image was composed of serial frames of a cardiac cycle. Therefore, the perfused region without significant count increase during the systolic period

TABLE 1
Comparison of Septal-to-Lateral Wall Count Ratio on Nongated ES and ED Images

	Nongate	ES	ED
Normal (n = 10)	0.84 ± 0.09 *	0.81 ± 0.11 †	0.86 ± 0.12 ns
LBBB (n = 11)	0.72 ± 0.09	0.62 ± 0.10	0.84 ± 0.11

*$p < 0.01$.
†$p < 0.001$.
ns = not significant

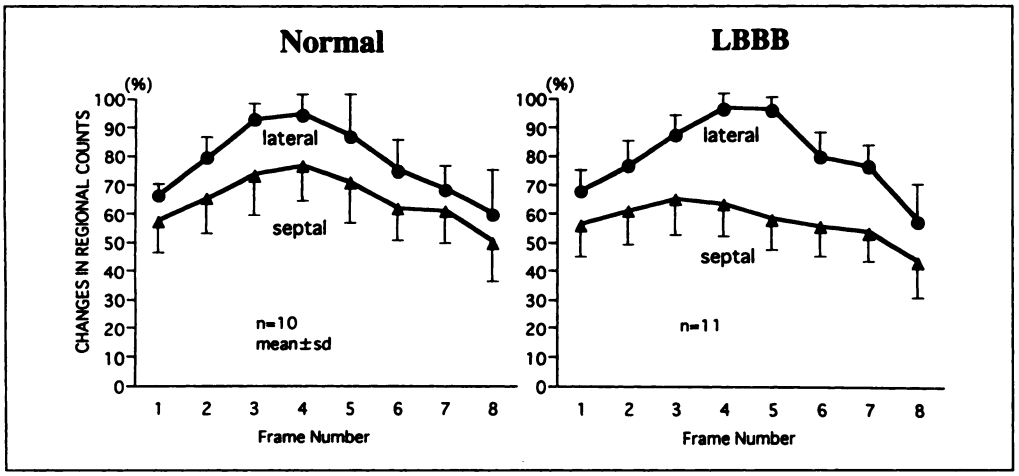

FIGURE 4. The count increase of septal and lateral regions during a cardiac cycle of the patients with LBBB (right) and normal subjects (left).

may be observed on nongated images as a hypoperfused region compared to the normally contracted region. Eisner et al. (*17*) also reported that abnormal segmental contraction can create abnormalities on SPECT myocardial perfusion images in a canine experimental study. These results indicate that abnormal wall thickening may mimic hypoperfusion on nongated images. Thus, actual perfusion should be carefully assessed at ED images in patients having a disproportional decrease in contraction such as those with LBBB or stunned myocardium. Avery et al. (*18*) mentioned that the ED frame can enhance the diagnostic capacity in coronary artery disease. Similarly, the effect of wall thickening should be considered to evaluate regional distribution of the tracers in any other radionuclide studies.

Our study has several limitations. The patient population was rather small; however, significant differences were obtained with this patient population. A previous study reported that the patients with LBBB often had associated CAD and nonischemic cardiomyopathies (*19*). We excluded the patients with prior myocardial infarction from our study. In addition, all of the patients had a low likelihood of CAD. However, coronary angiography was not performed in all the patients. Further study is warranted to assess regional function and perfusion with ECG-gated tomography in these patients, with different subgroups based on the etiology of the disease.

We evaluated myocardial perfusion at rest but not during stress. It is well known that reversible perfusion defect in the septal region occurs in patients with LBBB (*1–7*). Several mechanisms have been considered for this phenomenon (*1,20*). ECG-gated SPECT during stress may clarify the effect of regional thickening on regional perfusion in these patients as well.

CONCLUSION

Nongated SPECT images reflect both regional perfusion and regional wall thickening. In patients with LBBB, a disproportional decrease in regional wall thickening may cause a decrease in tracer distribution in the septal region at rest on nongated images. Such artifacts can be eliminated by analyzing ED and ES images separately on ECG-gated SPECT. Thus, ECG-gated SPECT images, especially the ED images, are better to evaluate the true perfusion of patients with abnormal contractions such as LBBB.

REFERENCES

1. Hirzel HO, Senn M, Nuesch K, et al. Thallium-201 scintigraphy in complete left bundle branch block. *Am J Cardiol* 1984;53:764–769.
2. Kipper MS, Grosshans C, Ashburn WL. False-positive ^{201}Tl SPECT studies in patients with left bundle branch block. Frequency and clinical significance. *Clin Nucl Med* 1991;16:890–893.
3. Jazmati B, Sadaniantz A, Emaus SP, Heller GV. Exercise thallium-201 imaging in complete left bundle branch block and prevalence of septal perfusion defects. *Am J Cardiol* 1991;67:46–49.
4. DePuey EG, Guertler-Krawczynska E, Robbins WL. Thallium-201 SPECT in coronary artery disease patients with left bundle branch block. *J Nucl Med* 1988;29:1479–1485.
5. Tighe DA, Hutchinson HG, Park CH, Chung EK, Fischman DL, Raichlen JS. False-positive reversible perfusion defect during dobutamine-thallium imaging in left bundle branch block. *J Nucl Med* 1994;35:1989–1991.
6. Knapp WH, Bentrup A, Schmidt U, Ohlmeier H. Myocardial scintigraphy with thallium-201 and technetium-99m-hexakis-methoxyisobutylisonitrile in left bundle branch block: a study in patients with and without coronary artery disease. *Eur J Nucl Med* 1993;20:219–224.
7. Campeau RJ, Garcia OM, Colon R, Agusala M, Correa OA. False-positive ^{99m}Tc-sestamibi SPECT in a patient with left bundle branch block. *Clin Nucl Med* 1993;18:40–42.
8. Faber TL, Akers MS, Peshock RM, Corbett JR. Tree-dimensional motion and perfusion quantification in gated single-photon emission computed tomograms. *J Nucl Med* 1991;32:2311–2317.
9. DePuey EG, Nichols K, Dobrinsky C. Left ventricular ejection fraction assessed from gated technetium-99m-sestamibi SPECT. *J Nucl Med* 1993;34:1871–1876.
10. Grucker D, Florentz P, Oswald T, Chambron J. Myocardial tomoscintigraphy with ^{99m}Tc-MIBI: regional and temporal activity curve analysis. *Nucl Med Commun* 1989;10:723–732.
11. Marzullo P, Marcassa C, Parodi O, Sambuceti G, Ferdeghini EM, L'Abbate A. Noninvasive quantitative assessment of segmental myocardial wall motion using technetium-99m 2-methoxyisobutylisonitrile scintigraphy. *Am J Noninvas Cardiol* 1990;4:22–28.
12. Altehoefer C, Dahl J, Kleinhans E, Uebis R, Hanrath P, Buell U. Technetium-99m-methxyisobutylisonitrile stress/rest SPECT in patients with constant complete left bundle branch block. *Nucl Med Commun* 1993;14:30–35.
13. Yamashita K, Tamaki N, Yonekura Y, et al. Quantitative analysis of regional wall motion by gated myocardial positron emission tomography: validation and comparison with left ventriculography. *J Nucl Med* 1989;30:1775–1786.
14. Marcassa C, Marzullo P, Parodi O, Sambuceti G, L'abbate A. A new method for noninvasive quantitation of segmental myocardial wall thickening using technetium-99m 2-methoxyisobutyleisonitrile scintigraphy–results in normal subjects. *J Nucl Med* 1990;31:173–177.
15. Cooke CD, Garcia EV, Cullom SJ, Faber TL, Pettigrew RI. Determining the accuracy of calculating systolic wall thickening using a fast Fourier transform approximation: a simulation study based on canine and patient data. *J Nucl Med* 1994;35:1185–1192.
16. Grines CL, Bashore TM, Boudoulas H, et al. Functional abnormalities in isolated left bundle branch block. The effect of interventricular asynchrony. *Circulation* 1989;79: 845–853.
17. Eisner RL, Schmarkey LS, Martin SE, et al. Defects on SPECT perfusion images can occur due to abnormal segmental contraction. *J Nucl Med* 1994;35:638–643.
18. Avery PG, Hudson NM, Hubner PJB. Gated technetium-99m methoxyisobutylisonitrile perfusion imaging. *Int J Cardiol* 1992;35:227–234.
19. Sugiura M, Hiraoka K, Ohkawa S, Ueda K, Toku A. A clinicopathological study on 25 cases of complete left bundle branch block. *Jpn Heart J* 1979;20:163–176.
20. Larcos G, Brown ML, Gibbons RJ. Role of dipyridamole thallium-201 imaging in left bundle branch block. *Am J Cardiol* 1991;68:1097–1098.