Technetium-99m HM-PAO-SPECT Study of Regional Cerebral Perfusion in Early Alzheimer's Disease

Daniela Perani, Vittorio Di Piero, Giuseppe Vallar, Stefano Cappa, Cristina Messa, Gabriella Bottini, Anna Berti, Domenico Passafiume, Guglielmo Scarlato, Paolo Gerundini, Gian Luigi Lenzi, and Ferruccio Fazio

Department of Biomedical Technologies, H. S. Raffaele, University of Milan; Department of Neuroscience, University of Rome; Clinica Neurologica II, Policlinico Hospital, University of Milan; and Department of Environmental Sciences, University of L'Aquila, Italy

Regional cerebral perfusion was evaluated by single photon emission computed tomography (SPECT) using technetium-99m hexamethylpropyleneamine oxime ([^{99m}Tc]HM-PAO) in sixteen patients with Alzheimer's disease (AD) in early clinical phase and in 16 healthy elderly controls. In all patients transmission computed tomography (TCT) and/or magnetic resonance imaging (MRI) did not show focal brain abnormalities. Relative to normal subjects, AD patients showed significant reductions in cortical/cerebellar activity ratio: cortical perfusion was globally depressed with the largest reductions in frontal and posterior temporo-parietal cortices. Asymmetries of relative perfusion between cerebral hemispheres were also demonstrated when language was affected or visuospatial functions were unevenly impaired. In patients with early AD, SPECT provides functional information to be compared with clinical and psychometric data.

J Nucl Med 29: 1507–1514, 1988

Patterns of alterations in cerebral blood flow and metabolism have been demonstrated by several positron emission tomography (PET) studies in patients with clinically diagnosed Alzheimer's disease (AD). Metabolism and perfusion were both reduced particularly in the posterior parietal and in the frontal regions and a significant increase in right/left metabolic asymmetry was associated with predominantly lateralized neuropsychological deficits (*1–4*).

Single photon emission computed tomography (SPECT) perfusion studies of regional cerebral blood flow (rCBF) both by the xenon-133 (^{133}Xe) inhalation method and the N-isopropyl-p- ^{123}I iodoamphetamine (IMP) i.v. injection method in patients with severe and advanced AD have provided similar information (*5–7*).

Recently, technetium-99m hexamethylpropylenamine oxime ([^{99m}Tc]HM-PAO) has been used as a potential rCBF agent by the SPECT technique (*8*). This tracer crosses the blood-brain barrier and it is almost completely cleared from the blood in a single passage through the cerebral circulation. Thus, its regional distribution can be considered proportional to regional blood flow (*9*). Due to the easy availability of ^{99m}Tc, the [^{99m}Tc]HM-PAO/SPECT technique can be proposed as a routine method for the assessment of regional perfusion. Aim of the present investigation has been to evaluate the usefulness of this method for the clinical assessment and management of AD.

Received Sept. 22, 1987; revision accepted Mar. 9, 1988.

For reprints contact: Daniela Perani, Dept. of Biomedical Technologies, Nuclear Medicine, Istituto San Raffaele, University of Milan, Via Olgettina 60, 20132 Milan, Italy.

METHODS

Subjects

Sixteen outpatients (ten women and six men, mean age 71.0 ± 7.7 yr, range 56 to 82 yr) with clinically diagnosed mild to moderate AD, (average duration of illness 20.9 mo, range 10 to 36 mo) and 16 normal elderly controls (four women, 12 men, mean age 63.5 ± 5.8 yr, range 54 to 75 yr) were studied. All normal controls lived independently and were free from known cerebrovascular disease. All patients were suffering from progressive dementia of recent onset and met clinical criteria for probable Alzheimer's disease (*10*). The severity of dementia was rated using the Crichton Dementia Scale (*11*): patients with a score exceeding 24 (severe demen-

tia) were excluded from the study. Patients with a score of more than four on the modified Hachinski Ischemia Score (*12*) were excluded. None of these patients had other neurological disease. Other causes of dementia were excluded as follows. No patient was taking medications or had a history of drug or alcohol abuse. All had normal laboratory blood tests including electrolytes, blood urea, VDRL, Vitamin B_{12}, folate, thyroid, and liver functions. In all patients third generation transmission computerized tomography (TCT) and/or 1.5 Tesla magnetic resonance imaging (MRI) performed within 1 wk from the SPECT examination, did not show focal brain abnormalities, the only pathologic finding being in some patients mild to moderate cerebral atrophy. Patients with severe cerebral atrophy were not included in the study (*13*).

Neuropsychological Assessment

All patients underwent a detailed neuropsychological evaluation, including measures of nonverbal intelligence (Raven's Progressive Matrices Coloured), auditory language comprehension (Token Test), controlled word association (Phonemic and Categorial Fluency), short-term verbal (Digi Span) and spatial (Corsi Span) memory, long-term verbal (Short Story, Word List Learning), and spatial (Corsi Supraspan Learning) memory and constructional apraxia (Copying Drawings) (for tests description see *14*).

SPECT Study

SPECT data collection was carried out 10 min following i.v. injection of 20 mCi of [^{99m}Tc]HM-PAO using a rotating gamma camera and a dedicated computer. The technique has been previously described, albeit for a different tracer (*15*). Acquisitions were made recording 64 angular views (from 0 to 360°) using a 64 × 64 matrix. In 30 min, 4 million total counts were collected. SPECT data, reconstructed and corrected for attenuation, yielded a complete set of axial tomographic slices from the posterior fossa up to the vertex. For each subject (patients and controls) five slices (2 pixels thick = 1.2 cm) were considered: one slice corresponding to the cerebellum (orbito-meatal (OM) line) and four supratentorial cerebral slices at 3.3, 4.5, 5.7, and 6.9 cm above the OM line respectively. On each cerebral slice, eight regions of interest (ROIs) (4 × 4 pixels large = 2.5 × 2.5 cm) were symmetrically located, four on the right and four on the left cortical ribbon (Fig. 1A). On the cerebellar slice, two symmetrical ROIs (4 × 4 pixels large) were selected, centered on each cerebellar hemisphere (Fig. 1B). Counts of the two symmetrical cerebellar ROIs were averaged yielding a single value representing cerebellar activity.

Data Analysis

A semi-quantitative assessment of rCBF was obtained as a ratio of activity distribution in the cortical ROIs to the activity in the cerebellar ROI, thus obtaining 16 index values of relative perfusion for each cerebral hemisphere. Cerebellar activity was chosen as a reference because the cerebellum is generally spared by major pathological involvement in AD (*16*). Data were then submitted to a repeated analysis of variance following a split-plot factorial design (*17*). The main factors of this analysis were group (patients/controls), region of interest (1, 2, 3, 4), slice (four supratentorial slices) and hemisphere (right/left).

In addition, in order to assess perfusion differences between cerebral hemispheres, relative perfusion indexes were calculated as left to right counts ratio for each pair of symmetrical ROIs. These ratios yielded 16 indexes for each subject. In patients with AD, hemispheric perfusion asymmetry was evaluated comparing for each hemisphere the number (N) of index

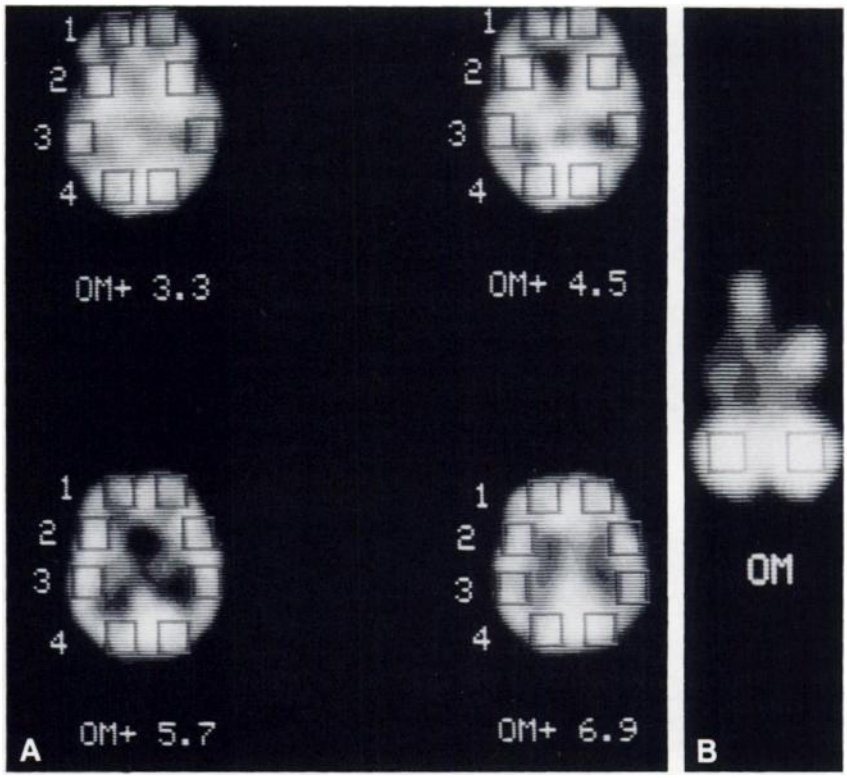

FIGURE 1
A: SPECT images of the four supratentorial slices at 3.3, 4.5, 5.7, 6.9 cm. above the orbito-meatal line of a normal control. Eight symmetrical regions of interest are outlined on the cortical ribbon. The regions are as follows: 1, frontal; 2, anterior temporo-parietal; 3, posterior temporo-parietal; 4, occipital. B: SPECT image corresponding to the orbito meatal line (OM) with two symmetrical regions of interest placed on the cerebellar hemispheres.

TABLE 1
Mean Values of Cortical/Cerebellar Ratios*

	Patients LH				Controls LH			
Site	1	2	3	4	1	2	3	4
†OM + 3.3	0.675 ± 0.20	0.721 ± 0.11	0.718 ± 0.15	0.931 ± 0.14	0.949 ± 0.08	0.962 ± 0.07	0.962 ± 0.08	1.038 ± 0.09
OM + 4.5	0.686 ± 0.17	0.761 ± 0.09	0.659 ± 0.10	0.868 ± 0.14	0.963 ± 0.09	0.996 ± 0.08	0.874 ± 0.12	1.026 ± 0.07
OM + 5.7	0.668 ± 0.15	0.713 ± 0.10	0.630 ± 0.07	0.830 ± 0.14	0.923 ± 0.10	0.992 ± 0.07	0.884 ± 0.12	1.008 ± 0.09
OM + 6.9	0.665 ± 0.17	0.739 ± 0.09	0.677 ± 0.09	0.790 ± 0.16	0.931 ± 0.10	0.916 ± 0.11	0.898 ± 0.10	1.013 ± 0.08
	Patients RH‡				Controls RH§			
Site	1	2	3	4	1	2	3	4
OM + 3.3	0.711 ± 0.18	0.743 ± 0.10	0.696 ± 0.14	0.881 ± 0.12	0.952 ± 0.10	0.973 ± 0.09	0.963 ± 0.09	1.025 ± 0.10
OM + 4.5	0.703 ± 0.13	0.783 ± 0.09	0.655 ± 0.12	0.851 ± 0.14	0.971 ± 0.09	0.990 ± 0.07	0.914 ± 0.11	1.036 ± 0.08
OM + 5.7	0.701 ± 0.11	0.754 ± 0.08	0.636 ± 0.12	0.833 ± 0.14	0.917 ± 0.10	0.978 ± 0.09	0.865 ± 0.08	1.015 ± 0.08
OM + 6.9	0.698 ± 0.12	0.745 ± 0.09	0.700 ± 0.12	0.811 ± 0.14	0.924 ± 0.11	0.917 ± 0.11	0.881 ± 0.07	1.021 ± 0.09

* The difference between patients and controls were significant for group ($p < 0.001$) site ($p < 0.001$) and slice ($p < 0.001$) by ANOVA.
† OM = orbito-meatal line.
‡ RH = right hemisphere.
§ LH = left hemisphere.

values out of the normal range as assessed in the control group.

RESULTS

Table 1 shows the mean values ± s.d. of the cortical/cerebellar ratios in both patients and controls. Cortical perfusion was significantly reduced in patients with AD compared with the 16 elderly normal subjects. The reversal of numbers of males and females in the patients and the control groups did not influence the results as significant sex-related differences have never been reported for cerebral blood flow in normal subjects (*18*). Analysis of variance revealed significant effects of: (a)

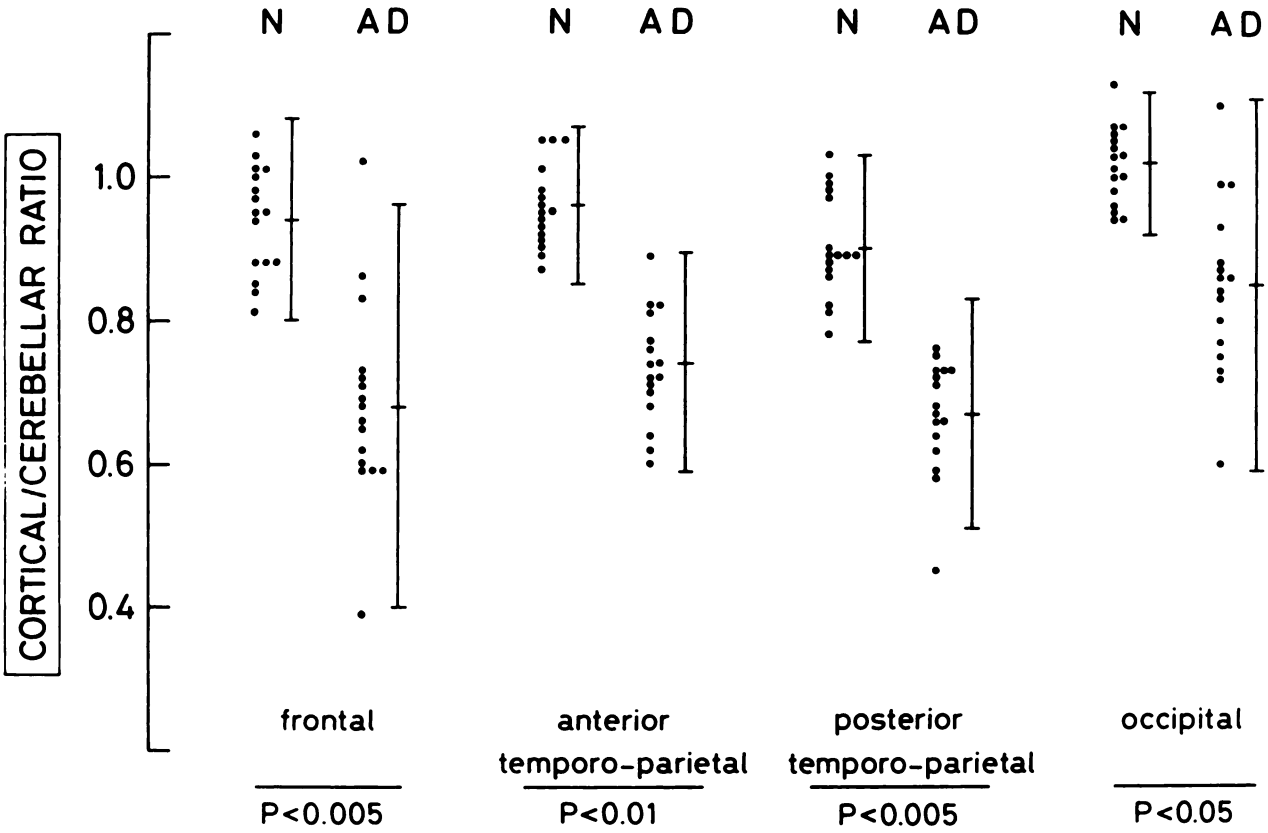

FIGURE 2
Mean cortical/cerebellar ratios for all the patients and the controls in four different cerebral regions. N = normals; AD = Alzheimer patients. Dots represent individual values. Bars indicate mean ± 2 s.d.

group ($F = 998.51$; $df = 1$; $p < 0.001$); (b) region of interest ($F = 85.58$; $df = 3$; $p < 0.001$); and (c) slice ($F = 6.57$; $df = 3$; $p < 0.001$). Significant differences between regions were also found within each group (group × region interaction ($F = 6.06$; $df = 3$; $p < 0.001$): the most marked reductions of rCBF were found in the frontal (site 1: $p < 0.005$) and posterior temporo-parietal (site 3: $p < 0.005$) cortical regions bilaterally, whereas smaller reductions were found in the fronto-parietal (site 2: $p < 0.01$) and occipital (site 4: $p < 0.05$) areas (Fig. 2).

In the control group the cerebral interhemispheric ratio of radioactivity distribution was 1.00 ± 0.05 (s.d.), setting the normal range (mean ± 2 s.d.) between 0.90 and 1.1. Cerebellar hemispheres in all AD patients showed symmetrical patterns of radioactivity distribution comparable to those found in the normal group. Asymmetries of relative perfusion between the cerebral hemispheres exceeding the normal range were detected in 14 out of 16 patients. This difference involved more than three ROIs in eight patients: four patients showed a predominantly left hemispheric involvement, while in four the decrease in radioactivity was in the right hemisphere. For the two groups, perfusion asymmetry ratios did not correlate with performance at language tests for the left hemisphere, and visuospatial tests for the right hemisphere. However, in selected patients, functional deficits and SPECT patterns showed a remarkable correspondence. Two examples follow, the first showing how a diffuse cognitive deficit correlates with a diffuse perfusion impairment, the second with more regional defect in cognitive functions and perfusion.

Case 12

A 75-yr-old man (Fig. 3) (with 4 yr of schooling) 28 mo before our study started to complain of a progressive memory loss. He had no history of other neurological disorders. In the period following, he was seriously impaired in the activities of the daily life; he was unable to find the way for an accustomed destination and to use money and objects properly—his general performances rapidly deteriorated. General and neurological examinations were normal. On neuropsychological evaluation he had defective scores on all tasks. The Raven PM score, which can be assumed to indicate the severity of global deterioration, was low, but also the auditory language comprehension (Token Test score = 15) and the ability to copy drawings (score = 0) were severely impaired. The TCT scan was normal. The SPECT study demonstrated a bilateral reduction of cerebral perfusion in posterior temporo-parietal areas.

Case 9

A 56-yr-old woman (Fig. 4) (with 17 yr of schooling) began to show a progressive change of personality 1 yr before our observation; she complained of depressed mood and had frequent episodes of psychomotor agitation. In the following months, she became unable to dress herself independently and had difficulties in using common household objects properly. No language defects were apparent.

Previous medical history was unremarkable. General and neurological examinations were normal. On neuropsychological evaluation performed at the time of SPECT study, the score of Raven PM was in the low range and the Token Test, which is a sensitive index of left hemispheric damage (*19*), was normal (score = 29). For the constructional apraxia test, where impairment is more frequent and severe after right hemispheric lesion (*20*), the score was 0. The TCT showed a mild degree of cortical atrophy. The SPECT study revealed a reduction of perfusion in frontal and temporo-parietal cortical region with major involvement of the right hemisphere.

DISCUSSION

In AD patients, positron emission tomography (PET) has shown a generalized decline in cerebral blood flow, oxygen and glucose utilization, paralleling disease progression (*2,21*). Coupling of blood flow and metabolism was preserved, with normal regional oxygen extraction ratio, thus ruling out a casual role of ischemia in the development of the disease (*2*). Further PET studies in AD showed reduction in glucose metabolism chiefly in the frontal and temporo-parietal cortex, sometimes in the early clinical phases of the disease (*22–24*). The cortical areas most severely involved in PET studies of AD are the same regions most severely affected in neuropathological and neurochemical investigations (*16,25,26*). These severe and selective pathologic effects are clearly distinguishable from the slight and uniform age-related decline of cerebral blood flow and metabolism reported by PET studies in normal aging (*27,28*). A depression of cortical tracer activity has also been demonstrated by rCBF SPECT study using both ^{133}Xe and iodine-123-labeled amines (*5–7,29*).

Our own SPECT findings, obtained in a relatively early stage AD (*30*) using a widely available tracer such as [^{99m}Tc]HM-PAO are in agreement with previous PET and SPECT studies, confirming a marked impairment of cerebral perfusion, particularly in frontal and temporoparietal areas. The correspondence of PET and SPECT findings can be explained by the preserved coupling of blood flow and metabolism in AD (*2*). In turn, this suggests that cortical areas of reduced perfusion detected by SPECT in AD patients represent areas of impaired neuronal function. This pattern of reduced perfusion does not occur in age-matched controls, and it may represent a diagnostic criterion.

In this study, we used a semiquantitative assessment of rCBF comparing cortical to cerebellar ROIs, because

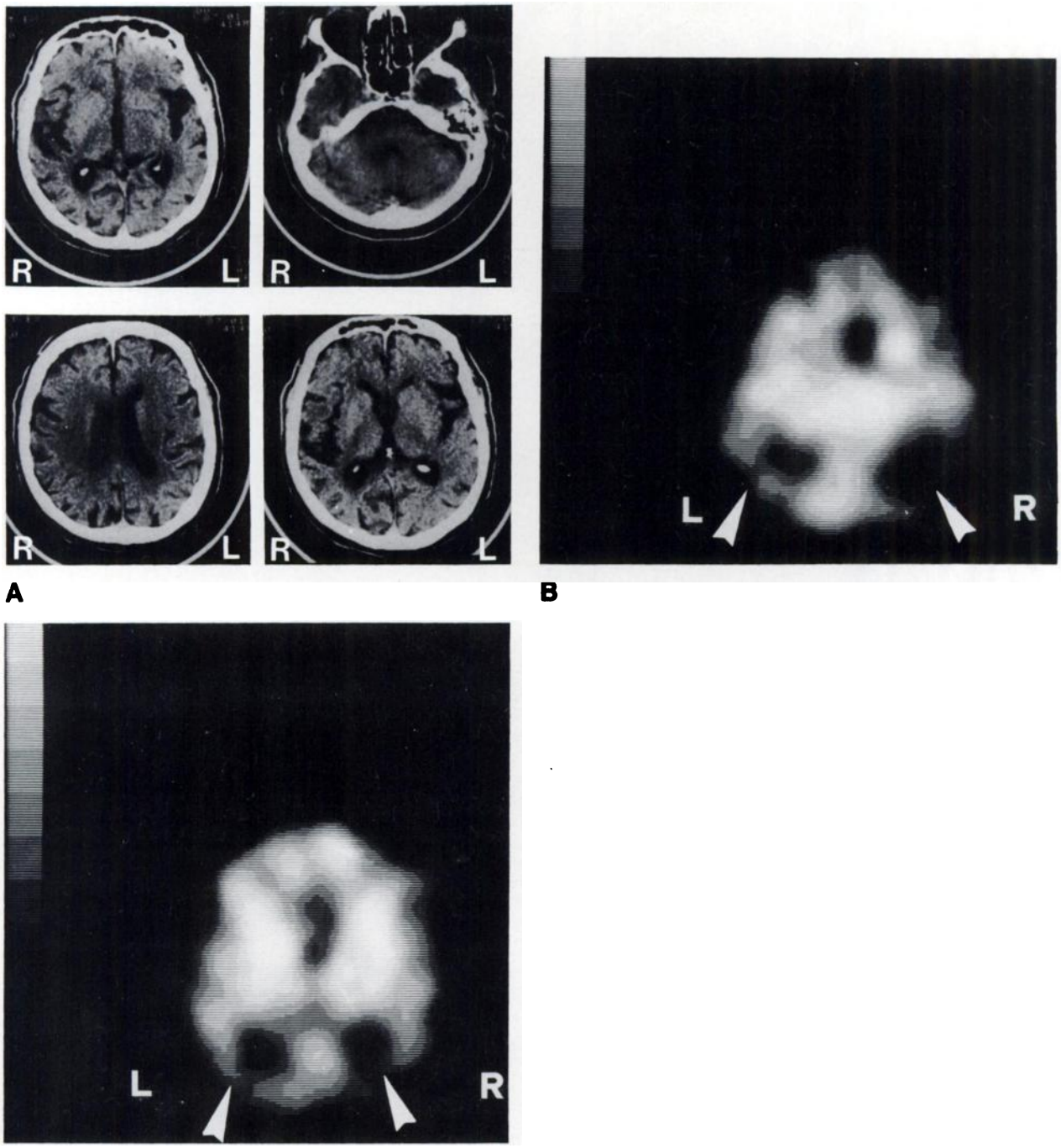

FIGURE 3
Patient 12. A: TCT scan shows normal appearance of cerebral structures with mild signs of atrophy. B: SPECT (OM + 4.5) and C: SPECT (OM + 5.7) demonstrates temporo-parietal areas of bilateral reduction of cerebral perfusion (arrows). This patient demonstrated a global correlation between general decreased cognitive function and diffuse perfusion reduction.

at the present quantitative data cannot be retrieved from SPECT studies. This semiquantitative method has been previously used (*3,4,7,24*) and relies on the assumption that cerebellar rCBF is unaffected in AD. This assumption is warranted by pathologic (*31*) and SPECT (*7*) findings.

Our data point to an early cortical rCBF impairment as shown by abnormal cortical/cerebellar perfusion ratios with normal cortex at TCT or MRI. This has also been reported in a PET study (*25*). Undoubtedly, structural imaging modalities such as TCT and MRI are very effective for the differential diagnosis of dementia,

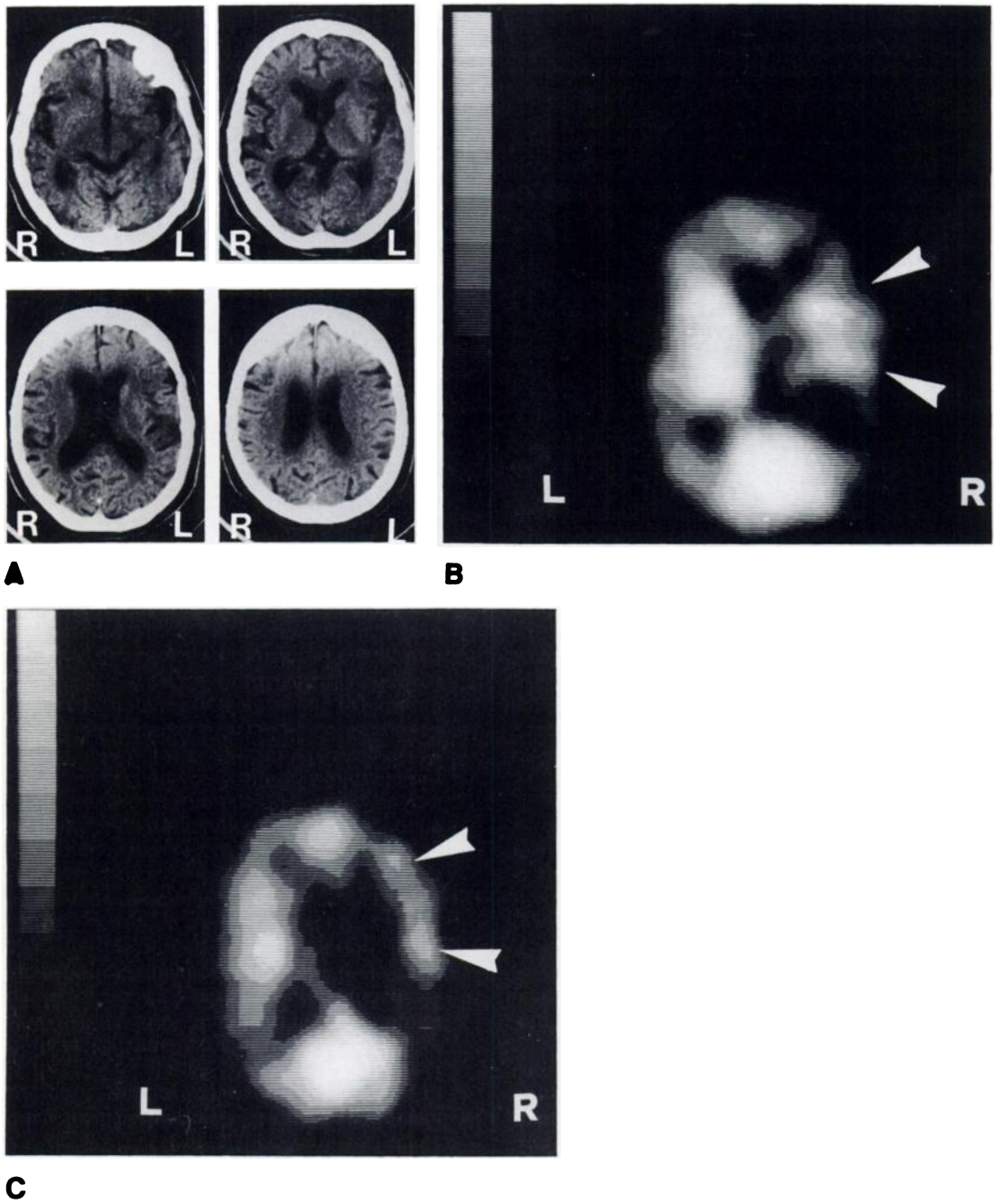

FIGURE 4
Patient 9. A: TCT scan shows only a mild degree of cortical atrophy. B: SPECT (OM + 5.7) and C: SPECT (OM + 6.9) evidences reduction of perfusion in right frontal and temporo-parietal cortical regions, (arrows), in keeping with the focal cognitive defect (constructional apraxia).

establishing the presence of tumors, abscesses, and vascular lesions. MRI can be particularly useful in detecting the white matter abnormalities suggestive of multi-infarct dementia (*32*). In patients with severe and advanced AD, significant cortical atrophy and changes in ventricular size have been demonstrated by TCT measurements, but efforts to use atrophy indexes to differentiate patients from elderly controls have yielded inconsistent results (*13,33*); only recent studies using sophisticated quantitative analyses look promising (*34, 35*). A smooth "halo" of periventricular hyperintensity at MRI has been proposed as a distinctive finding in Alzheimer's disease (*36*). However, this is known to be present also in other cerebral diseases (*37*). Thus, at this time, both TCT and MRI imaging are yet regarded of limited value for the clinical assessment of primary degenerative dementia of the Alzheimer type.

In addition to abnormal cortico-cerebellar perfusion

ratios, hemispheric asymmetries of cortical perfusion were also found in some of our patients. Similar findings have been reported by PET studies in patients with mild and moderate AD (*3,4,38*). This may be related to the existence of clinical subtypes of AD, characterized by selective neurochemical and neuropsychological deterioration (*39,40*) particularly early in the disease, when uneven pathologic involvement of the two hemispheres has been reported (*41*). In our study, statistically significant correlations between patterns of neuropsychological impairment and perfusion asymmetries were not found. However, an agreement between clinical presentation and hemispheric side of major perfusion impairment was found in selected cases.

As already anticipated for SPECT methods in general (*42*), this work indicates that the [^{99m}Tc]HM-PAO SPECT technique is valuable for the clinical assessment and management AD patients.

ACKNOWLEDGMENTS

This research was supported by CNR grant. The authors thank Dr. G. Raimondi for her cooperation.

REFERENCES

1. Alavi A, Ferris S, Wolf A, et al. Determination of cerebral metabolism in senile dementia using F-18-deoxyglucose and positron emission tomography. *J Nucl Med* 1980; 21:21.
2. Frackowiak R, Pozzilli C, Legg J, et al. Regional cerebral oxygen supply and utilization in dementia. *Brain* 1981; 104:753–778.
3. Foster NL, Chase TN, Fedio P, et al. Alzheimer's disease: focal cortical changes shown by positron emission tomography. *Neurology* 1983; 33:961–965.
4. Duara R, Grady C, Haxby J, et al. Positron emission tomography in Alzheimer's disease. *Neurology* 1986; 36:879–887.
5. Bonte FJ, Ross ED, Chehabi HH, et al. SPECT study of regional cerebral blood flow in Alzheimer disease. *J Comput Assist Tomogr* 1986; 10:579–583.
6. Sharp P, Gemmell H, Cherryman G, et al. Application of iodine-123-labeled isopropylamphetamine imaging to the study of dementia. *J Nucl Med* 1986; 27:761–768.
7. Johnson KA, Mueller ST, Walshe TM, et al. Cerebral perfusion imaging in Alzheimer's disease. Use of SPECT and I-123 IMP. *Arch Neurol* 1987; 44:165–168.
8. Leonard JP, Nowotnik DP, Neirinckx RD. Technetium-99m-d, 1-HM-PAO: a new radiopharmaceutical for imaging regional brain perfusion using SPECT. A comparison with iodine-123 HIPDM. *J Nucl Med* 1986; 27:1819–1823.
9. Lucignani G, Perani D, Rossetti C, et al. Biodistribution and clinical evaluation of ^{99m}Tc HM-PAO: a tracer for rCBF assessment by SPECT. *J Cereb Blood Flow Metab* 1987; 7:S538.
10. McKhann G, Drachman D, Folstein M, et al. Clinical diagnosis of Alzheimer's disease: report of the NINCDS-ADRDA Work Group under the auspices of Department of Health and Human Services Task Force on Alzheimer's disease. *Neurology* 1984; 34:939–944.
11. Robinson RA. Problems of drug trials in elderly people. *Geront Clin* 1961; 3:247–257.
12. Hachinski VC, Lassen NA, Marshall J. Multi-infarct dementia, a cause of mental deterioration in the elderly. *Lancet* 1974; 2:207–209.
13. Huges CP, Gado M. Computed tomography and aging of the brain. *Radiology* 1981; 139:391–396.
14. Lezak MD. Neuropsychological assessment. Second Ed. New York: Oxford University Press, 1983.
15. Fazio F, Lenzi GL, Gerundini P, et al. Tomographic assessment of regional cerebral perfusion using intravenous I-123 HIPDM and a rotating gamma camera. *J Comput Assist Tomogr* 1984; 8:911–921.
16. Brun A, Englund E. Regional pattern of degeneration in Alzheimer's disease: neuronal loss and histopathological grading. *Histopathology* 1981; 5:549–564.
17. Kirk RE. Experimental design: procedures for the behavioural science. Belmont, California: Brooks/Cole Publishing Company, 1969.
18. Hartmann A, Hoyer S. Cerebral blood flow and metabolism measurement. New York: Springer-Verlag, 1985.
19. De Renzi E, Vignolo LA. The Token Test: a sensitive test to detect receptive disturbances in aphasia. *Brain* 1962; 85:665–678.
20. Arrigoni G, De Renzi E. Constructional apraxia and hemispheric locus of lesion. *Cortex* 1964; 1:170–197.
21. Cutler NR, Haxby JV, Duara R, et al. Clinical history, brain metabolism, and neuropsychological function in Alzheimer's disease. *Ann Neurol* 1985; 18:298–309.
22. Chase TN, Foster NL, Fedio P, et al. Regional cortical dysfunction in Alzheimer's disease as determined by positron emission tomography. *Ann Neurol* 1984; 15:S170–S174.
23. Metter EJ, Riege WH, Kameyama M, et al. Cerebral metabolic relationships for selected brain regions in Alzheimer's, Huntington's, and Parkinson's diseases. *J Cereb Blood Flow Metab* 1984; 4:500–506.
24. Friedland RP, Budinger TF, Koss E, et al. Alzheimer's disease: anterior-posterior and lateral hemispheric alterations in cortical glucose utilization. *Neurosci Lett* 1985; 53:235–240.
25. Mc Geer PL, Kamo H, Harrop R, et al. Comparison of PET, MRI, and CT with pathology in a proven case of Alzheimer's disease. *Neurology* 1986; 36:1569–1574.
26. Davies P. Neurotransmitter related enzymes in senile dementia of the Alzheimer type. *Brain Res* 1979; 171:319–327.
27. Frackowiak RSJ, Lenzi GL. Physiological measurement in the brain: from potential to practice. In: Ell PJ, Holman BL, eds. *Computed emission tomography.* Oxford: OUP, 1982: 188–210.
28. Pantano P, Baron JC, Lebrun-Grandie P, Duquesnoy N, Bousser MG, Comar D. Regional cerebral blood flow and oxygen consumption in human aging. *Stroke* 1984; 15:635–641.
29. Cohen MB, Graham LS, Lake R, et al. Diagnosis of Alzheimer's disease and multiple infarct dementia by tomographic imaging of iodine-123 IMP. *J Nucl Med* 1986; 27:769–774.
30. Martin DC, Miller JK, Kapoor W, et al. A controlled study of survival with dementia. *Arch Neurol* 1987;

44:1122–1126.
31. Tomlison BE, Corsellis JAN. Aging and dementia. In: Adams JH, Corsellis JAN, Duchen LW, eds. *Greenfield's Neuropathology.* New York: John Wiley & Sons, Inc, 1984:951–1025.
32. Erkinjutti T, Sipponen TJ, Iivanainen M, et al. Cerebral NMR and CT imaging in dementia. *J Comput Assist Tomogr* 1984; 8:614–618.
33. Brinkman SD, Sarwar M, Levin HS, et al. Quantitative indexes of computed tomography in dementia and normal aging. *Radiology* 1981; 138:89–92.
34. Creasey H, Schwartz M, Frederickson H, et al. Quantitative computed tomography in dementia of the Alzheimer type. *Neurology* 1986; 36:1563–1568.
35. Schwartz M, Creasey H, Grady CL, et al. Computed tomographic analysis of brain morphometrics in 30 healthy men, aged 21 to 81 years. *Ann Neurol* 1985; 17:146–157.
36. Fazekas F, Chawluk JB, Alavi A, et al. MR signal abnormalities at 1.5 T in Alzheimer's dementia and normal aging. *Am J Roentgenol* 1987; 149:351–356.
37. Zimmerman RD, Fleming CA, Lee BCP, et al. Periventricular hyperintensity as seen by magnetic resonance: prevalence and significance. *Am J Roentgenol* 1986; 146:443–450.
38. Haxby JV, Duara R, Grady CL, et al. Relations between neuropsychological and cerebral metabolic asymmetries in early Alzheimer's disease. *J Cereb Blood Flow Metab* 1985; 5:193–200.
39. Chang Chui H, Teng EL, Henderson VW, et al. Clinical subtypes of dementia of the Alzheimer type. *Neurology* 1985; 35:1544–1550.
40. Capitani E, Della Sala S, Spinnler H. Neuropsychological approach to dementia. In: Poech K, Freund HJ, Gianshirt H, eds. Berlin: Springer Verlag, 1986.
41. Koss E, Friedland RP, Ober BA, et al. Differences in lateral hemispheric asymmetries of glucose utilization between early and late onset Alzheimer type dementia. *Am J Psych* 1985; 142:638–640.
42. Holman BL. Perfusion and receptor SPECT in the dementias. George Taplin Memorial Lecture. *J Nucl Med* 1986; 27:855–860.